
Asymmetry of limbic structure (hippocampal formation and amygdaloidal complex) at PTSD

Aida Sara--Had`ihalilovi}, Faruk Dilberovi}

Department of Anatomy, Faculty of Medicine, University of Sarajevo, ^ekaluša 90

Abstract

Defining exact position of weak anatomic function which is find in a base of neurological and psychiatric disorder is just became the subject of intensive research interest. For this purposes it is important to implement structural and functional MRI techniques, also for further lightening and seeing subject of this work, more concretely connected to PTSD. Therefore, exactly MRI gives most sensitive volumetric measuring of hippocampal formation and amygdaloidal complex.

The goal of this work was to research asymmetry of hippocampal formation and amygdaloidal complex to the PTSD patients.

Results showed that at the axial slice length of hippocampal formation on the left and right side of all patients are significantly asymmetric. At the sagittal slice from the left side of hippocampal formation is in many cases longer than right about 50 %. At the coronal slice, there are no significant differences toward patient proportion according to *symm. / asymm.* of the hippocampal formation width at the right and left side. Difference in volume average of hippocampal formation between right and left side for axial and coronal slice is not statistically significant, but it is significant for sagittal slice. In about amygdaloidal complex patients with PTSD toward *symm. / asymm.* Amygdaloidal complex at the right and left side of axial and sagittal slice in all three measurement shows asymmetry, what is especially shown at sagittal slice. Difference in average length of amygdaloidal complex at the right and left side is not statistically significant for no one slice.

Therefore, results of a new research that are used MRI, showed smaller hippocampal level at PTSD (researched by Van der Kolka 1996, Pitman 1996, Bremner et al., 1995.). Application of MRI technique in research of asymmetry of hippocampal formation and amygdaloidal complex, which we used in our research, we recommend as a template for future researches in a sense of lightening anatomic function that is a base of neuropsychiatric disorders.

Keywords: limbic system, hippocampal formation, amygdaloidal complex, asymmetry, posttraumatic stress disorder - PTSD

Introduction

Concerning development concept of PTSD since 1980 by American society of psychiatrics, officially is accepted what even laics knows, that extreme stress can lead to continuous psychiatric disorder. World health organization (WHO) PTSD entering in their 10 revision of International illness classification (IIC 10) and related health problems. Last years became clear and in specialist and scientific societies accepted that PTSD is not the only shape of psychopathological disorder that is caused by stress. Today it is find that in around 20 % people who's passing through heavy stresses, heavy psychiatric disorders has been developed, or that in a around 18 % of ambulance psychiatric patients psychiatric disorder for which they are contacting psychiatrics, are results of life trauma.

Hypersensibility, avoiding / emotional weakening, and repeatedly happening situations with hard remembrance of trauma are defined signs of PTSD. Authors presume that many of PTSD symptoms are result of limbic structure hyperactivity, which can through their many projections in to prefrontal cortex contribute to dysfunction of this system, and as results of that expect the loss in performance with frontal functioning. This hyperactivity can be physiological correlate of fear structure knowledge (hypothesis made by Foa, Feske, Murdock, Kozak I McCarthy, 1991.), which are contagiously activated and can be leader of emotional abnormality, as sudden shows of hyper sensibility and sense of horror. Authors conclude that what ever neuropathological mechanism in sense is, no matter is this is prefrontal cortical pathology, lower function of limbic system, or most probably some combination of these two, their follows OR, OI and ONPSU damages in PTSD clearly contain involvement of frontal system.

Materials and Methods

As a material for construction of this study, we used 10 MRI scan patients with PTSP, where we have cognately function damage. Methods of work include measuring the size of hippocampal formations and amygdaloidal complex in all three projections (axial, coronal and sagittal) 10 patients with PTSP, where we have cognately functional damage.

MRI scans are done on MAGNET IMPACT SIEMENS 1.0 TESLA in T1 relaxation (TR 500 - 600 / TE 15 / field of view 180 x 260, the fatness layer SL 5 mm) and T2 relaxation (TR 4000 / TE 90 field of view 188 x 250 for axial and 173 x 230 for coronal, 210 x 240 for sagittal scans in 5 mm layer). Dual sequences are used PD and T2. In PD TR is 4000, and TE 22. We used a head - neck spiral, as well as a head spiral.

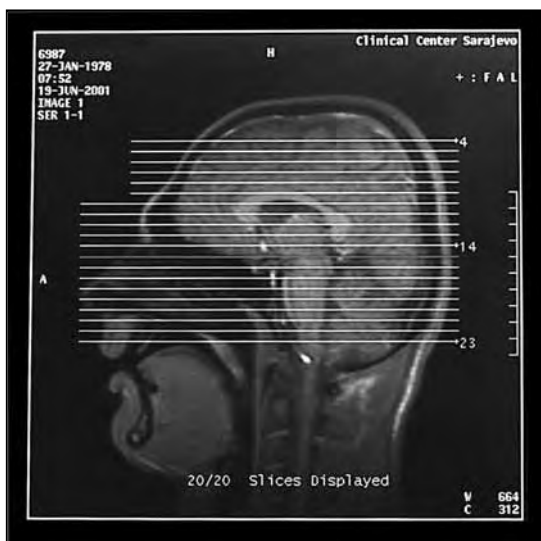For the size measurement of amygdaloidal complex and hippocampal formation, and their comparison from right to left, we used a program of evaluation- distance on the MRI from the Institute of Radiology of Clinical Centre in Sarajevo. We tested 10 patients with PTSP, approximate age 49.9 with standard deviation of 4.62 years.

The size of hippocampal formation is measurement in all three projections: horizontal (axial), frontal (coronal) and sagittal from right and left. The size of amygdaloidal complex is measurement in two projections: horizontal (axial) and sagittal. In axial projections, we are measurement anterior - posterior and lateral - medial diameter of amygdaloidal complex. We do not measurement the amygdaloidal complex in coronal projections, because it is not possible his clear diffraction from the other cerebral structures. All values of hippocampal formation and amygdaloidal complex are given in centimetres.

For hippocampal, formation and amygdaloidal complex in all three projections (axial, coronal and sagittal) are met in:

Results

MRI analysis in patients with PTSD

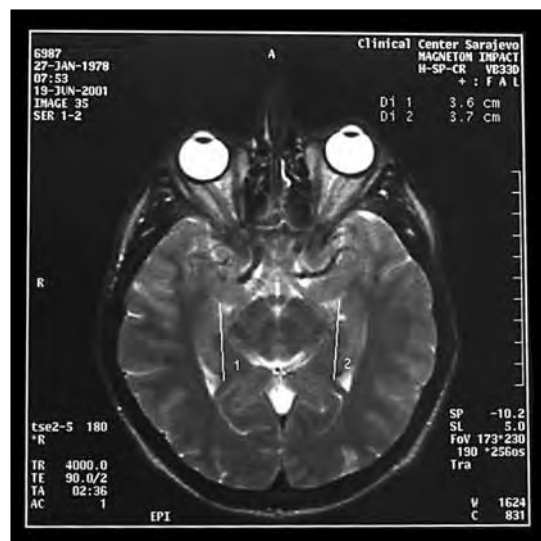

Picture 1 Axial MRI scans -the slice on a hippocampal formation level

1. The number of patients with PTSD according to symmetry/asymmetry of hippocampal formation on the right and left side
2. Analysis of patients with PTSD by the approximate size of hippocampal formation on left and right side
Significant difference is tested with t-test
3. The number of patients with PTSD according to symmetry/asymmetry of amygdaloidal complex on the right and left side on axial and sagittal projections
4. Analysis of patients with PTSD by the approximate size of amygdaloidal complex on left and right side on axial and sagittal projections
Significant difference is tested with t-test

Methods of statistical analysis used in this assignment are:

1. Arithmetic middle
2. Standard deviation
3. Standard failure
4. Median
5. Mod
6. Chi - Square test
7. t - test differences of arithmetical middle
8. t - test proportionally
9. Coefficient of asymmetry



Picture 2 Axial MRI scans -length of hippocampal formation from the right and the left side

Table 1 Shows patients with PTSD towards symmetry/asymmetry hippocampal formation from right and left on the axial, coronal and sagittal slice

		Axial slice		Coronal slice		Sagittal slice	
		Number	in %	Number	in%	Number	in %
SYMMETRY: hippocampal formation on the right and left side of the slice is the same size		-	-	5	50 .00	2	20.00
ASYMMETRY hippocampal formation on the right and the left side of the slice is the different size	Total	10	100.00	5	50.0	8	80.0
	Out of that: <i>The right side bigger than the left side</i>	6	60.00	2	20 .00	3	30.00
	<i>The left side bigger than the right side</i>	4	40 .00	3	30.0	5	50.00
TOTAL		10	10 0.00	10	10 0.00	10	100.00

Length of hippocampal formation on the left and right side of axial slice are on all patient significantly asymmetric. Value of Chi - square test is: ChiSq = 10, level of assurance is $p < 0.01$.

Length of hippocampal formation on the left and right side of sagittal slice is not statistically significant on the level of reliability $p < 0.05$. Value of ChiSq = 3.6. (Sign. for level $p < 0.10$).

At the coronary slice, there are no significant differences in patient proportion toward symm/asymm of width hippocampal formation with right and left side.

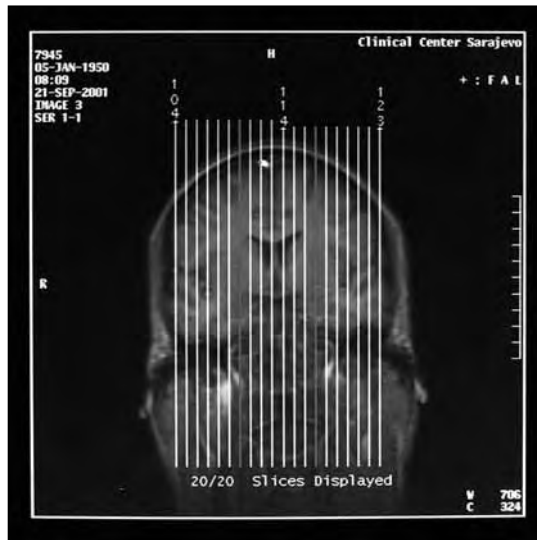
Table 2 Approximate size of the hippocampal formation on the right and left side on the axial, coronal and sagittal slice on patient with PTSD

HIPPOCAMPAL FORMATION	Right side		Left side	
	\bar{x} in cm	S.D. in cm	\bar{x} in cm	S.D. in cm
Axial slice	3.89	0.495	3.89	0.579
Coronal slice	2.08	0.116	2.11	0.34
Sagittal slice	4.08	0.477	4.21	0.476

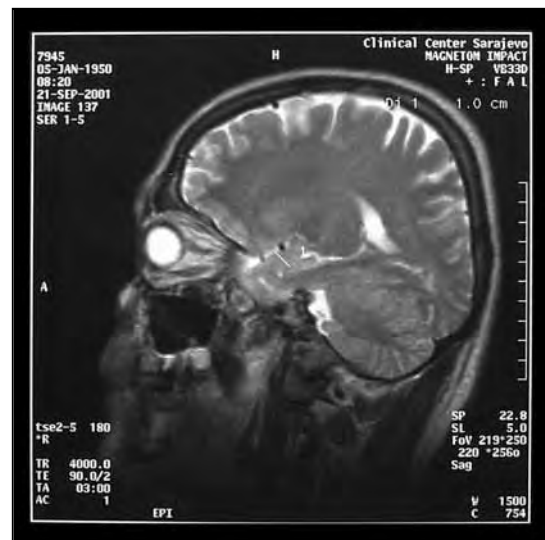
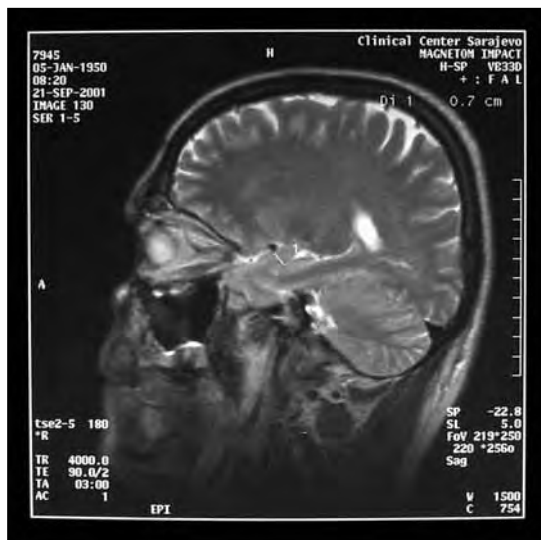Difference in average size of hippocampal formation between right and left side is not statistically significant for axial and coronary slice, but it is significant for sagittal slice.

Values of t- test are:

- a) for axial slice: $t = 0.0615$ not significant
- b) for coronary slice: $t = 0.223$ not significant
- c) for sagittal slice: $t = 2.727$ significant $p < 0.05$



Picture 3
Sagittal MRI scans - the slice on a parahippocampal gyrus and hippocampal formation level



Picture 4
Sagittal MRI scans - size of amygdaloidal complex on the right and left side

Table 3 Shows patients with PTSD towards symmetry /asymmetry amygdaloidal complex from right and left on the axial, coronal and sagittal slice

		Axial slice (ant. — post. diameter)		Axial slice (lat.-med. diameter)		Sagittal slice	
		Number	in%	Number	in %	Number	in%
SYMMETRY: Amygdaloidal complex on the right and left side of the slice is the same length		2	20 .00	2	20 .00	-	-
ASYMMETRY Amygdaloidal complex on the right and the left side of the slice is the different length	Total:	8	80.00	8	80.00	10	100.00
	Out of that: <i>The right side length than the left side</i>	5	50 .00	6	60 .00	6	60.00
	<i>The left side length than the right side</i>	3	30 .00	2	20 .00	4	40.00
TOTAL:		10	10 0.00	10	10 0.00	10	100.00

On all three measurements, there are asymmetry in length of right and left side, and what is especially signed on sagittal slice.

Value Chi - square test for sagittal slice is ChiSq = 10, level of reliability is $p < 0.01$.

Table 4 Approximate length of the amygdaloidal complex on the right and left side on the axial and sagittal slice on patient with PTSD

AMYGDALOIDAL COMPLEX	Right side		Left side	
	\bar{x} in cm	S.D. in cm	\bar{x} in cm	S.D. in cm
Axial slice (ant.-post. diameter)	1.42	0.209	1.35	0.242
Axial slice (lat.-med. diameter)	1.88	0.275	1.82	0.200
Sagittal slice	1.17	0.205	1.15	0.191

Difference in average length of right and left side is not statistically significant for any case. Values of t - tests are:

- a) For axial slice (ant. - post. diameter): $t = 0.694$ not sign.
- b) For axial slice(lat. - med. diameter): $t = 0.549$ not sign
- c) For sagittal slice: $t = 0.226$ not sign.

Discussion

Defining exact position of weak anatomic function which is found in a base of neurological and psychiatric disorder is just became the subject of intensive research interest. For this purposes it is important to implement structural and functional MRI techniques, also for further lightening and seeing subject of this work, more concretely connected to PTSD. Therefore, exactly MRI gives most sensitive volumetric measuring of hippocampus formation and amygdaloidal complex.

Karestan C. Koenen et al. - 2001. (20) Evaluate cognitive loss in PTSD. Authors mainly guess that many of PTSD symptoms are results of limbic structure hyperactivity, which can through their high-levelled projection in to prefrontal cortex contribute to dysfunction of this system and because of that, we can expect loss in performing of neuropsychological tasks. Result of newer researches that used MRI showed on smaller hippocampal size at PTSD (Van der Kolka 1996). Pitman, 1996, approved smaller hippocampal size bilaterally on to Vietnam war veterans with PTSD. Bremner et al., 1995, showed significant size decrease of right hippocampal volume on to Vietnam war veterans with PTSD. According to given results authors conclude that discontinuation in performing of neuropsychological tasks (OI & IP), will show if limbic projection in to prefrontal cortex are going to be under attack with smaller hippocampal size in PTSD.

According to basis of analyze of our results linked to size of hippocampal formation in all three projection (axial, coronary and sagittal), in a group of patient with PTSD, we can observe on a following way:

1. On to axial slice length of hippocampal formation on left and right side on all patients are significantly asymmetric. On to sagittal slice from the left side, the hippocampal formation is in many cases longer than right - 50 %.

On coronary slice, there are no significant differences toward proportion patient according to symm. /asymm. of width of hippocampal formation on the left and right side.

2. Difference in average size of hippocampal formation between left and right side for axial and coronary slice is not statistically significant, but it is significant for sagittal slice.

According to analysis of our results connected to size of amygdaloidal complex in two projections (axial: ant. - post. in addition, lat. - med. diameter and sagittal), in a group of patient with PTSD, we can conclude that:

1. Patient with PTSD according to symm. / asymm. of amygdaloidal complex on the left and right side of axial and sagittal slice in all 3 measurement shows asymmetry, what is mostly present on sagittal slice.

2. Difference in average length of amygdaloidal complex on the left and right side is not statistically significant for none of the slices.

Conclusions

On basis of our analysis, we can conclude:

1. Every one of analyzed asymmetry shows the same characteristics in the group, in which we emphasize variations.

2. We also emphasize the importance of presence of conciseness in individual characteristics of every one of the parameters in the shading light on asymmetry of hippocampal formation and amygdaloidal complex.

3. We have to be careful about what projection we are refusing to as being watched hippocampal formation and amygdaloidal complex because the results will depend on that. We can suggest the prospective studies in more projections because of the value of the statistically significant conclusions.

4. MRI - volumetric measurement have their value.

5. Usage of MRI techniques in examining the asymmetry of hippocampal formation and amygdaloidal complex, that we used, we suggest as the studies in the future research in the sense of the shading light on the anatomical functions that are based on neuropsychiatry dysfunctions.

References

1. Bilir E., Craven W., Hugg J., Gilliam F., Martin R., Faught E., Kuzniecky Volumetric MRI of the limbic system: anatomic determinants, *Neuroradiology*. 40(3):138-44, 1998 Mar.
2. Cahill L., Haier RJ., Fallon J., Alkire MT., Tang C., Keator D., Wu J., McGaugh JL.: Amygdala activity at encoding correlated with long-term, free Recall of emotional information, *Proceedings of the National Academy of Sciences of the USA*. 93 (15): 8016-21, 1996 Jul.
3. Chronister R. B., Hardy S. G. P.: *The Limbic System*, chapter thirty, 444 - 454, 2000.
4. Dilberovi} F., Kulenovi} A., Kundurovi} Z., Sara~ - Had`ihalilovi} A.: Contribution to detection of the corpus amygdaloideum using magnetic resonance, XV Congress of the International Federation of Associations of Anatomists and IV International Malpighi Symposium, Rome, September 11 - 16, 1999.
5. Dilberovi} F., Kulenovi} A., Sara~ - Had`ihalilovi} A., Kadeni} Z.: Prikaz limbi-kih struktura u temporalnom re`nju velikog mozga metodom MRI i CT, Prvi Kongres Radiologa Bosne i Hercegovine, Sarajevo, 14 - 16 Oktobar, 1999.
6. Dilberovi} F., F. Ov~ina, V. ^erkez: Hipokamp i amigdaloidni kompleks u pacova i ma~aka, *Folia Anatomica Jug.*: 11 - 20, 1982
7. Dalagija F., Be{li} [., Vobornik S.: Magnetna Rezonanca, *Medicinski `urnal*, 1 - 11, Supplement 2000
8. Elaine N. Marieb: *Neural Integration - Higher Mental functions*, *Human Anatomy and Physiology*, third edition: 489 - 500, 1995.
9. Foundas AL., Hong K., Lonard CM., Heilman KM.: Hand preference and magnetic resonance imaging asymmetries of the central sulcus, *Neuropsychiatry, Neuropsychology & Behavioural Neurology*. 11 (2): 65 - 71, 1998. Apr.
10. Giedd JN., Vaituzis AC., Hamburger SD., Lange N., Rajapakse JC., Kaysen D., Vauss YC., Rapoport JL.: Quantitative MRI of the lobe, amygdala and Hippocampus in normal human development: ages 4 - 18 years. *Journal of Comparative Neurology*. 336 (2): 223 - 30, 1996 Mar.
11. Had`iselimovi} H.: O asimetriji ~ovje~ijeg mozga, *Radovi - LI Odjeljenja medicinskih nauka*, Sarajevo, 1974.
12. Had`iselimovi} H., ^u{ M.: The appearance of internal structures of the brain in relation to configuration of the human skull, *Acta anat*. 63, 289 - 299, 1966.
13. Had`iselimovi} H., Ru`di} N.: Appearance of the base of the brain in relation to the configuration of human skull, *Acta anat*. 65, 146 - 156, 1966.
14. Had`iselimovi} H., And`eli} M.: On the appearance of some interior brain structures in relation to the exterior configuration of the brain, *Acta anat*. 63, 289 - 299, 1966.
15. Had`iselimovi} H., M. ^u{, F. Dilberovi}: Hipokamp i amigdaloidni kompleks novore|en~eta, *Folia Anatomica Jug.* : 21 - 30, 1979.
16. Hellige JB., Taylor KB., Lesmes L., Peterson S.: Relationships between brain morphology and behavioural measures of hemispheric asymmetry and interhemispheric interaction, *Brain & Cogniton*. 36 (2): 158 - 92, 1998 Mar.
17. Haines D. E., Mihailoff G. A.: Hippocampus and Amygdala, *The Telencephalon*, chapter fifteen, 216 - 217, 2000.
18. Irwin W., Davidson RJ., Lowe MJ., Mock BJ., Sorenson JA., Turski PA.: Human amygdalae activation detected with echo - planar functional magnetic resonance imaging, *Neuroreport*. 7 (11): 1765 - 9, 1996 Jul.
19. Juki} Vlado: Posttraumatski stresni poreme}aj, *Medikus: Br*. 1 (7): 15 - 28, Zagreb, 1998.
20. Karestan C. Koenen., Kelly L. Driver., Marlene Oscar - Berman.: Measures of Prefrontal System Dysfunction in Posttraumatic Stress Disorder, *Brain and Cognition* 45, 64 - 78, 2001.
21. Koenen KC., Driver KL., Oscar - Berman M., Wolfe J., Folsom S., Huang MT., Schlesinger L.: Measure of prefrontal system dysfunction in post-traumatic stress disorder, *Brain and Cognition*. 45 (1):64 - 78, 2001 Feb.
22. Lynch J. C.: *Higher Cortical Functions*, *The Cerebral Cortex*, chapter thirty one, 465 - 469, 2000.
23. Malcom B. Carpenter: *Gross Anatomy of the Brain*, *Core Text of Neuro-anatomy*, third edition: 23-28,1985.
24. Malcom B. Carpenter: *Olfactory Pathways, Hippocampal Formation and the Amygdala*, *Core Text of Neuroanatomy*, third edition: 331 - 347, 1985.
25. Merhemi} Z., Dalagija F., Kadeni} Z., Sulejmanpa{i} G., Prevljak S., Konjho|i} F.: Po~etna iskustva sa aparatom za magnetnu rezonancu od 1,0 Tesla u neuroradiologiji, *Medicinski `urnal*, 32 - 36, Supplement 2000.

26. Petersen R. C. et al.: Memory and MRI - based hippocampal volumes in aging and AD, *Neurology*, 54: 581 -587, 2000.
27. Pruessner JC., Collins DL., Pruessner M., Evans AC.: Age and gender predict volume decline in the anterior and posterior hippocampus in early adulthood, *Journal of Neuroscience.*, 21 (1): 194 - 200, 2001 Jan 1.
28. R. Barber, McKeith IG., Ballard C., Gholkar A., O'Brien JT.: A comparison of medial and lateral temporal lobe atrophy in dementia with Lewy bodies and Alzheimer's disease: magnetic resonance imaging volumetric study, *Dementia and Geriatric Cognitive Disorder*, 12 (3): 198 - 205, 2001 May-Jun.
29. Sara~ - Had`ihalilovi} Aida: Asymmetry of palate in relation of asymmetry Of neurocranium, The Eleventh European Anatomical Congress Timisoara - Romania, September 10 - 13, 1998.
30. Sara~ - Had`ihalilovi} Aida: Asymmetry of the brain and his blood - vessels, XV Congress of the International Federation of Associations of Anatomists and IV International Malpighi Symposium, Rome, September 11 - 16, 1999.
31. Schneidr F., Grodd W., Wiss U., Klose U., Mayer KR., Nagele T., Gur RC.: Functional MRI reveals left amygdala activation during emotion, *Psychiatry Research*. 76 (2 - 3): 75 - 82, 1997 Dec.
32. Stephan G. Waxman: The Limbic System, *Correlative Neuroanatomy*, twenty - third edition: 246 - 258, 1996.
33. Stephan G. Waxman: Higher Cortical Functions, *Correlative Neuroanatomy*, Twenty - third edition: 275 - 286, 1996.
34. Wolf H., Grunwald M., et al.: Hippocampal volume discriminates between normal cognition, questionable and mild dementia in the elderly, *Neuro-biology of Aging*. 22 (2): 177 - 86, 2001 Mar - Apr.