

Computed tomography review of the osseous structures of the orbital apex

Eldan Kapur, Faruk Dilberović

Department of Anatomy "Prof. Dr. Hajrudin Hadžiselimović"
Faculty of Medicine, University of Sarajevo, Čekaluša 90

Abstract

In this paper, we described osseous anatomy of the orbital apex using CT in axial and coronal projections. The main osseous landmarks facilitate the evaluation of orbital apex in radiology, especially on the axial and coronal CT scans. These landmarks include so called optic strut, small segment of the greater wing of the sphenoid bone and upper part of the pterygopalatine fossa. We also concentrate attention upon visualisation and review of the optic canal, superior and inferior orbital fissure, pterygopalatine fossa and foramen rotundum.

Key words: orbital apex, CT, optic canal, superior orbital fissure, inferior orbital fissure, pterygopalatine fossa, foramen rotundum.

Introduction

The top of the orbital cavity or orbital apex is defined as the area between the posterior ethmoidal foramen on one side, and optic canal and superior orbital fissure, on other side. The roof of the orbital apex consists of lower side of the lesser wing of the sphenoid bone; its medial wall creates the lateral wall of the ethmoidal sinus, medial wall creates the greater wing of the sphenoid bone, and the basis is the orbital process of the palatine bone. The orbital apex through the optic canal and superior orbital fissure is establishing the communication with the sellar region, and together with it, it represents the clinical-anatomical and radiological entity known as the cranio-orbital junction. This area is affected by different pathological processes which include fracture of the sphenoid bone with consecutive lesion of intracanalicular or intracranial part of optic nerve, infectious processes (orbital pseudotumour and Tolosa-Hunt syndrome), vascular lesions (e.g. aneurysm, carotid-cavernous shunts, thrombosis of cavernous sinus etc.), and tumours with the most frequent appearing of pituitary adenoma, meningioma and craniopharyngioma (1).

From the above mentioned we can conclude that the osseous anatomy of the orbital apex is very complicated and that it understands the knowing of the optic canal, superior and inferior orbital fissures, pterygopalatine fossa and foramen rotundum (2,3,4,5). Knowing these structures, its relations and variations, as well as the posi-

tion and the orientation is the key point in evaluation (diagnostics and therapy) of the fractures, tumours and the inflammatory processes in the area of orbital apex, as well as the neighbouring topographical areas, firstly the middle cranial fossa, pterygopalatine and infratemporal fossa (1,2,3,4,5,6,7).

Adequate presentation and description of osseous anatomy of the orbital apex by the method of computed tomography (CT) demands knowing of its appear in three dimensions (Figure 1 and Figure 2)

Figure 1 Osseous structures of the cranio-orbital junction. Viewed from the above:

1. fossa pterygopalatina, 2. foramen rotundum,
3. canalis pterygoideus, 4. canalis palatinus major,
5. foramen sphenopalatinum, 6. fissura orbitalis inferior,
7. sulcus infraorbitalis,
8. paries inferior orbitae,
9. cellulae ethmoidales,
10. foramen ovale,
11. foramen spinosum.

Testut / Latarjet - Traite D'Anatomie Humaine, Tome 1, page 281.

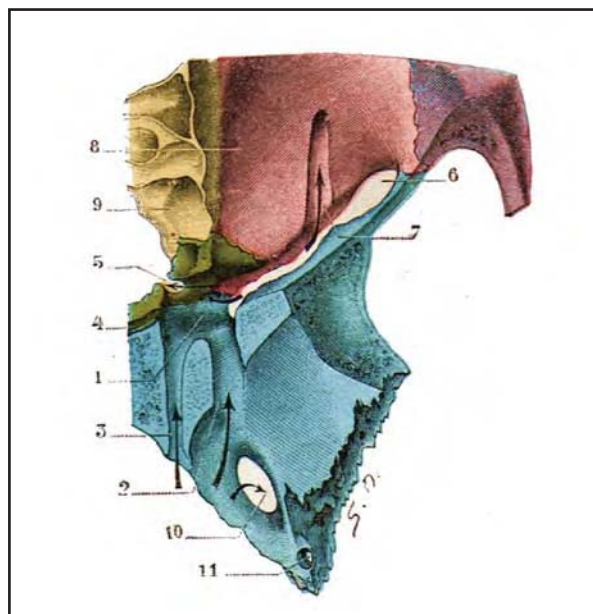
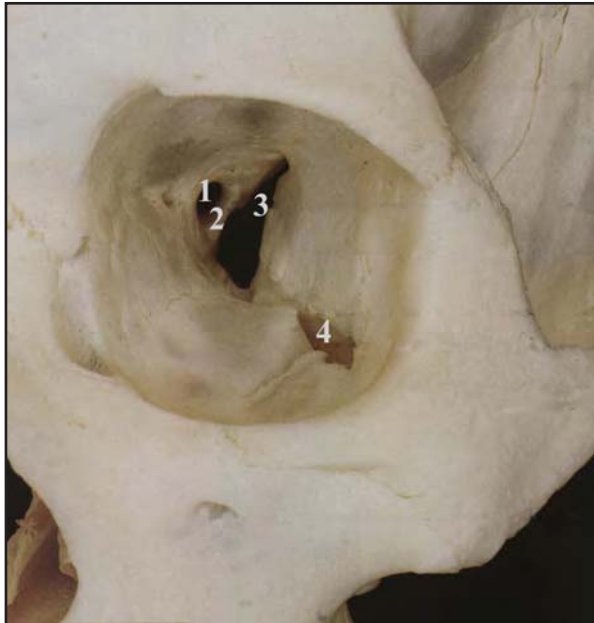


Figure 2 Osseous structures of the cranio-orbital
Osseous structures of the orbital apex

1. canalis opticus,
2. optic strut,
3. fissura orbitalis superior,
4. fissura orbitalis inferior



By this we can have the complete insight in "normal" appearance of the osseous structures of the orbital apex, and analyse the changes which are seen with different pathological conditions by which it may be primarily or secondarily affected.

Aim of work

The objective of this paper is defining and the presentation of main osseous orientation points (landmarks) by the method of computed tomography, which will help the evaluation of the structure of orbital apex in normal and pathological circumstances.

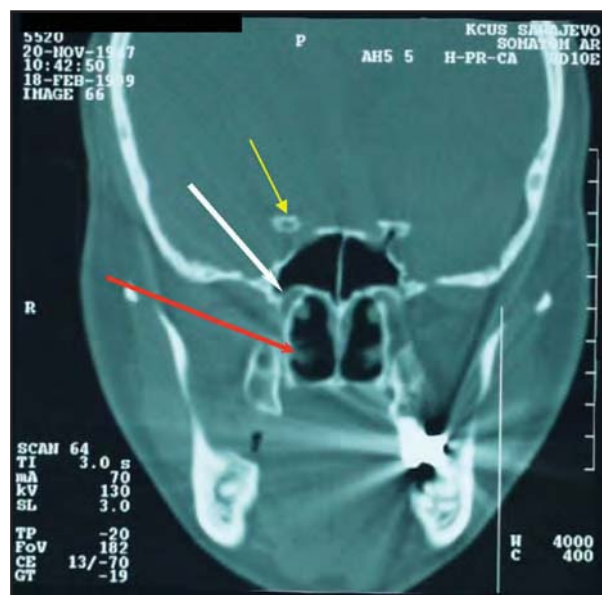
Material and methods

As the material for the preparation of these papers, we used 50 craniums from the osteological collection of the Institute for Anatomy of the School of Medicine in Sarajevo. With the osteological material, by anthropometrical analyses we defined main osseous orientation points of the orbital apex and the ratios of osseous structures in so-called cranio-orbital junction and the junction of the orbital cavity with the extracranial topographic areas. CT findings in axial and coronal projections are made by the apparatus Somatom ART with the width of layers of 2.3 and 5 mm. The osseous orientation points, defined at the bone material are shown at CT records.

Results

The optic canal (**canalis opticus**) forms the angle of 40° -50° with the sagittal plane of the head. It is limited medially by the body of the sphenoid bone, towards the superior root of the lesser wing of the sphenoid bone, inferolaterally by so called optic strut (which represents the inferior root of the lesser wing), and totally laterally by the anterior clinoid process (Figure 3).

Figure 3 Coronal CT scans through the posterior part of the orbital cavity and the pterygopalatine fossa (white arrow - foramen rotundum, red arrow - sinus maxillaris, yellow arrow - canalis opticus)



Inferolaterally from the optic canal, separated from it with above mentioned optic strut, there is the superior orbital fissure (**fissura orbitalis superior**). It is located between greater and lesser wing of the sphenoid bone (Figure 4).

It mostly has the form of cut with widen, round part, positioned inferomedially and thinner part in shape of small tail positioned superolaterally. Directly beneath and behind the superior orbital fissure there is a foramen rotundum (**foramen rotundum**), located in the upper part of the sphenoid bone's greater wing. In question is in fact parasagittally positioned small thin canal, directed from the back area and laterally towards front and medially - anteromedially direction (Figure 5).

The communication of middle cranial and pterygopalatine fossa is established through the foramen rotundum.

The pterygopalatine fossa (fossa pterygopalatina) and the inferior orbital fissure (fissura orbitalis inferior) have the common relations (Figure 6).

Figure 4 Axial CT scan through the upper part of the orbital cavity (red arrow - foramen rotundum, yellow arrow - fissura orbitalis superior)

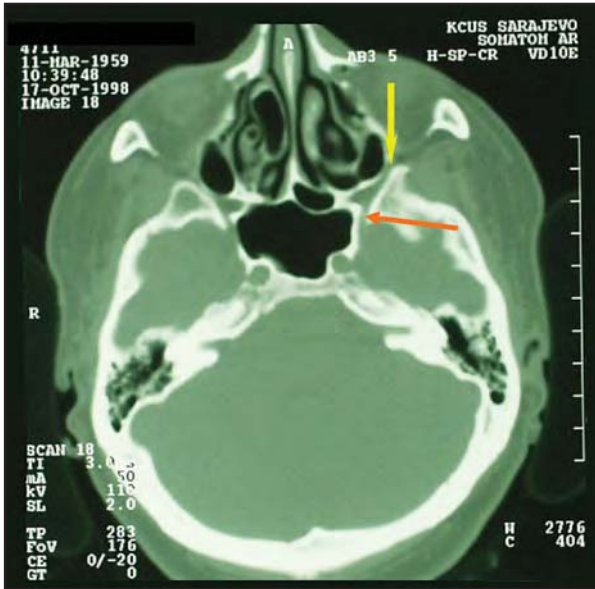


Figure 5 Axial CT scan through the lower part of the orbital cavity (black arrow - fissura orbitalis inferior, yellow arrow - foramen sphenopalatinum, red arrows - canalis rotundus)

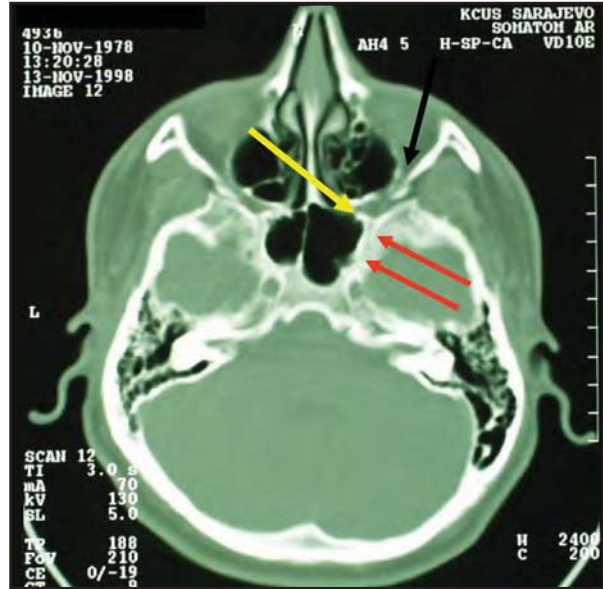
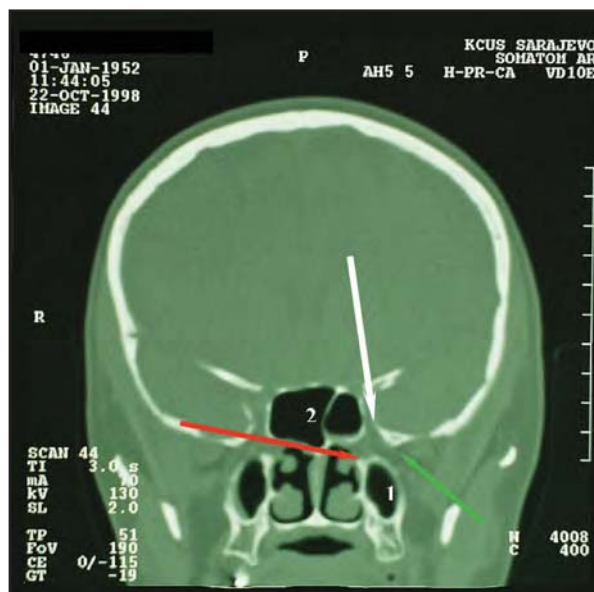

Figure 6 Coronal CT scan through the anterior part of the pterygopalatine fossa (white arrow - fissura orbitalis inferior, red arrow - foramen sphenopalatinum, green arrow - fissura pterygomaxillaris)



The inferior orbital fissure with the sagittal plane of head creates the angle of around 45°. It is located between the lateral and the inferior wall of the orbital cavity and it is best noticed if the cranium is observed from aside and slightly from back. The sphenoid bone creates the lateral margin of the inferior orbital fissure, and superior and posterior wall of the pterygopalatine fossa. The maxillary bone creates the medial margin of the inferior orbital fissure and together with orbital process of the palatine bone creates the anterior wall of the pterygopalatine fossa. The anterior margin of the inferior orbital fissure is created by the zygomatic bone. The anterior part of the inferior orbital fissure is widen, while its posterior part (best shown in coronal CT) seems to be the thin, obliquely positioned gap, surrounded laterally by the sphenoid bone, and medially by the maxillary bone. Inferolaterally, through the inferior orbital fissure there is the communication between the orbital cavity and the infratemporalis fossa (**fossa infratemporalis**).

Discussion and conclusion

Important osseous orientation landmarks are making easier the evaluation of the orbital apex with axial and coronal CT scans (1,2,3,4). These orientation points include, firstly, so called optic strut (which separates the optic canal and the superior orbital fissure) small segment of the greater wing of the sphenoid bone (which separates the foramen rotundum and the superior orbital fissure), as well as upper part of the pterygopalatine fossa, which is screened at axial CT scans. Knowing of the osseous orientation points is of crucial importance in diagnostics of many pathological processes by which the orbital apex is primarily or secondarily affected, but also in the diagnostics of processes in the closest intracranial and extracranial surroundings (1,2,3,6,8,9,10).

References

1. **Ettl A., Zwrtek K., Daxer A., Salomonowitz E.:** Anatomy of the orbital apex and cavernous sinus on high resolution magnetic resonance images, *Survey of Ophthalmology*. Vol 44, 2000
2. **Citrin CM.:** High-resolution orbital computed tomography, *J. Comput Assist Tomogr*. 10(5):810-16, 1986 Sep-Oct
3. **Chong VFH., Fan YF., Chan LL. :** Radiology of the orbital apex. *Australas Radiol*. 1999; Aug 43 (3):294-302
4. **Daniels DL., Pech PJ., Kay MC., et al:** Orbital apex: correlative anatomic and CT study. *AJNR* 1985; 6:705-710
5. **Daniels DL., Rauschnig W., Lovas J., et al:** Pterygopalatine fossa: computed tomography studies. *Radiology* 1983; 149:511-516
6. **Kapur E.:** Lateralni pristup na nervus maxillaris i anatomske karakteristike pterigopalatinalne jame. *Magistarski rad*, Sarajevo 2001.
7. **Dilberović F., Kapur E.:** Osteologija (priručnik za studente Medicinskog i Stomatološkog fakulteta), Prvo izdanje. Štamparija Fojnica, Sarajevo, 2002.
8. **Forbes G.:** Computed tomography of the orbit, *Radiol Clin. North Am*. 20(1):37-49, 1982 Mar
9. **Gingsberg LA.:** Skull base foramina of middle cranial fossa; reassessment of normal variations with high resolution CT. *AJNR* 1994; 15:283-91
10. **Unsold R.:** Computed tomography of the orbit, *Int Ophtalmol Clin*. 22(4):45-80, 1982 Winter