
ANTI-CYTOKERATIN 7: A POSITIVE MARKER FOR EPITHELIAL DYSPLASIA IN FLAT BOWEL MUCOSA

Svjetlana Radovi}1*, Ivan Selak1, Mirsad Babi}1, Zora Vukobrat-Bijedi}2, @eljka Kne`evi}3

1 Institute of Pathology, School of Medicine, University of Sarajevo, ^ekalu{a 90, Sarajevo, Bosnia and Herzegovina

2 Gastroenterology Department, Sarajevo University Hospital Centre, Bolni-ka 25, Sarajevo, Bosnia and Herzegovina

3 General Hospital "Sarajevo", Kranj-evi}a 12, Sarajevo, Bosnia and Herzegovina

* Corresponding author

Abstract

The aim of this paper is to establish by immunohistochemistry the expression of keratin 7 in inflammatory-regenerative flat bowel mucosa and in different grades of epithelial dysplasia regarding the sub-units expressed in normal and carcinomatous colonic mucosa.

Biopsy specimens from 270 patients were examined: 74 were classified as inflammatory-regenerative changes and 196 as dysplastic lesions. There were 108 cases of mild dysplasia, 58 cases of moderate and 30 cases of severe dysplasia, respectively. Demonstration of location and intensity of cytokeratin 7 staining was performed by immunohistochemistry using monoclonal antibody (anti-cytokeratin 7). Findings of cytokeratin 7 in dysplastic lesions were compared with those in normal mucosa, inflammatory -regenerative mucosa and adenocarcinoma. Cytokeratin 7 is not found in normal colonic mucosa. In inflammatory-regenerative mucosa it was found in solitary cells in small number of cases. It is found in all cases of epithelial dysplasia and its expression showed no difference regarding moderate and severe dysplasia. In few cases of adenocarcinoma, cytokeratin 7 is found in traces and showed minimal staining intensity.

Having in mind that cytokeratine 7 is primarily found in dysplastic lesions of the flat colonic mucosa it can be a valuable diagnostic tool in the histological interpretation of epithelial dysplasia.

Key words: cytokeratin, dysplasia, colon mucosa,.

Introduction

Cytokeratins are complex proteins of intermediate filaments that provide epithelial cells with mechanic cohesion and resistance to trauma. Cytokeratins' family comprises of more than 20 different polypeptides. According to Moll catalogue (1) they are listed from 1 to 20, regarding their molecular weight and iso-electric point of proteins. They are divided into two subgroups: tip I (acid) i tip II (base). CK 1 has the largest molecular weight (68 kD) and the highest iso-electric pH (pH5.2), while CK 19 has the lowest molecular weight (40kD) and low iso-electric pH (ph 5.2). There are between 2-10 different cytokeratins in any epithelial tissue, always from both subgroups. Cytokeratins are present in both benign and malignant epithelial cells.

Immunohistochemistry provided identification of these

proteins. Monoclonal cytokeratin antibodies visualised selectively certain cytokeratins. Some epithelial cells could be differentiated on a basis of specific pattern of their cytokeratin's profile - for example hepatocytes contain cytokeratin 8 and 18 (2). It is considered that the expression of specific cytokeratins is closely related to the ways of cellular differentiation. (3, 4). Expression of CK can go that far that it represents a reflection of tumour differentiation and metaplasia but also of some other developments that are not related to malignant alteration of cells (eg. drugs' influence, side effects of medicines, environmental factors) (5).

Our aim was to map cytokeratin 7 (intermediate filamentous protein weight of 54 kDa, marked as cytokeratin 7 in Moll classification) immunophenotype in inflammatory-regenerative flat bowel mucosa as well as in different grades of dysplasia and it is compared with normal colonic mucosa and colon adenocarcinoma tissue. If there is an altered expression of keratin 7 in dysplastic colonic cells, we wanted to determine the point at which this alteration occurs, and hence evaluate the possible value of immunohistochemistry as a diagnostic tool in colonic epithelial dysplasia.

Material and methods

During the routine endoscopic examination, 2-3 specimens of colonic mucosa (always at 30 cm from the anus) were taken after the clinician established the diagnosis of inflammatory process. Biopsy specimens were taken from 270 patients, out of which 208 were males and 62 females. All patients were older than 45 years (median age 65 years, range 46-82).

As a control group we used biopsy specimens of normal colonic mucosa of 40 deceased patients, 26 males and 14 females, between 30 and 70 years old (median age 52). These specimens were taken from the regular autopsy material (corpses were stored for eight hours in a fridge at +4 °C prior to autopsy in accordance with legal provisions) and the only criterion during the biopsy specimen collection was the absence of clinical history and histological evidence of inflammatory disease of colon and autolysis of mucosae.

Specimens of colon adenocarcinoma with "de novo" carcinoma cases have been taken also from the regular autopsy material (under the same conditions as with normal mucosa) Carcinoma samples were taken from 40

deceased patients, between 38 and 76 years old (median age 65), 27 males and 13 females. Carcinomas "de novo" are small carcinomas in colonic flat mucosa ranging from 7±10 mm in diameter. In 29 cases the surface was slightly sagged, in 8 cases slightly elevated and in 3 cases a discrete swelling in the level of mucosa surface appeared. On serial sections of "de novo" carcinoma tissue, neither by macroscopic nor by microscopic methods, the existence of resident adenoma tissue could have been established. The specimens were fixed in 10% buffered formalin, embedded in paraffin, cut into 3-5 micrometer sections and stained by standard haematoxylin-eosin (HE) and analysed immunohistochemically by anti-cytokeratine 7 (clone OV-TL 12/30, code No M 7018, lot 117, DAKO).

Histological criteria were defined for easy differentiation of inflammatory-regenerative and dysplastic changes and grading of dysplasia intensity (6). According to these criteria, dysplastic changes are classified into three groups (mild, moderate and severe dysplasia). The classification was based on 19 criteria regarding morphology of lesions, graded on a 1-4 scale with respect to the intensity of change. These are the criteria used in the classification: size of the epithelial cells, shape of nuclei, nucleo-cytoplasmic ratio, chromasia of nuclei, nuclear stratification, arrangement of chromatin inside nuclei, visibility and number of nucleoli, basophilia of cytoplasm, presence of different cellular types in a crypt, mucus secretion, number of cells in a crypt, presence and number of mitotic figures, irregular budding of crypts, crypt branching complex, number of crypts, presence of "back to back" formation, tendency to adopt villous configuration, presence of inflammatory cell infiltrate in the lamina propria and presence of "crypts abscess". The scores were summed up and their mean marked as index (I). The ranges of the index values for individual categories and degrees of changes were determined mathematically (6). Numerical values of index I for individual categories of changes are:

- 1.3<I<1.8 for inflammatory-regenerative changes;
- 1.9<I<2.3 for mild dysplasia;
- 2.4<I<2.9 for moderate dysplasia and
- 3.0<I<3.7 for severe dysplasia.

Immunohistochemical status of cytokeratin 7 (CK 7) consisted of a semi-quantitative evaluation of the number of positive stained cells and intensity of antigen staining as it follows:

1. number (expressed as percentage) of antigen positive stained cells is graded as:
0= no positive cells; 1=<25% cells stained; 2=25-50% cells stained; 3= 50-75% cells stained; 4= >75% cells stained;
2. intensity of antigen staining in cells is graded as it follows:

1=weak intensity (antigen stained pale yellow); 2=medium intensity (antigen stained ochre-yellow); 3=strong intensity (antigen stained brown);

3. location of antigen in certain parts of crypts (upper third, middle third and/or basal third of the crypt).

Breast tissue was used as CK 7 positive control.

Statistical analysis

The shi-squared test was applied to analyse the correlation between cytokeratin distribution among different group of epithelial dysplasia, normal mucosa, and carcinomatous tissue. A probability of $p<0.05$ was considered statistically significant.

Results

Among microscopically examined mucosal specimens of 270 patients, chronic ulcerative colitis was found in 105 patients, lymphocytic colitis in 40 patients and eosinophilic colitis in 25 patients. In 74 cases the changes have been defined as inflammatory-regenerative, and 196 cases as dysplastic ones. Mild dysplasia was found in 108 cases, moderate in 58, and severe in 30 cases (Table 1.). The correlation between the number of CK 7 positive cells and intensity of examined morphological lesions is shown in Table 2. CK 7 is not found in epithelial cells of normal colonic mucosa while in inflammatory-regenerative mucosa was found in only 8 cases (8.2%) in which 25% of cells contained antigen (grade 1). All these 8 cases were qualified with index value $I=1.8$ and they represented borderline cases toward moderate dysplasia. In 18 cases (16.6%) of mild dysplasia (Figure 1.) up to 25% of cells contained antigen (grade 1) and in 36 cases (33.7%) the antigen was present in 25-50% of cells (grade 2), while in 54 cases (50.1%) it was present in 50-75% of cells (grade 3). The difference between CK 7 positive cells in mild dysplasia (Figure 1.) and inflammatory-regenerative mucosa was highly significant (Table 2a). In 7 cases (12.0%) of moderate dysplasia (Figure 2.) CK 7 is found in only 25-50% cases (grade 2), in 11 (18.9%) cases in 50-75% of cells (grade 3), and in 40 cases (68.9%) is notified in more than 75% of cells (grade 4). In severe dysplasia (Figure 3.) in 5 cases (16.6%) 25-50% of cells contained antigen (grade 2), and in 5 cases (16.6%) 50-75% of cells contained antigen (grade 3), while in 20 (66.6%) cases is notified in more than 75% of cells (grade 4). The difference in number of antigen positive cells between categories of moderate and severe dysplasia was not significant (Table 2a). In only 3 (7.5%) cases of adenocarcinoma (Figure 4.) CK 7 was present in less than 25% of cells (grade 1). The difference between number of antigen positive cells in adenocarcinoma tissue and severe dysplasia tissue was highly significant (Table 2a). The intensity of the antigen staining in colonic inflamma-

Table 1. Classification of morphological mucosal changes in 270 patients with colonic inflammatory-regenerative and dysplastic epithelial lesions.

Morphological changes	Index*	No. of Patients
Inflammatory- regenerative	1.3	7
	1.4	10
	1.5	16
	1.6	9
	1.7	20
	1.8	12
Total		74
Mild dysplasia	1.9	21
	2.0	10
	2.1	29
	2.2	30
	2.3	18
	Total	
Moderate dysplasia	2.4	14
	2.5	15
	2.6	8
	2.7	6
	2.8	11
	2.9	4
Total		58
Severe dysplasia	3.0	5
	3.1	9
	3.2	4
	3.3	6
	3.4	2
	3.5	2
	3.6	2
3.7	0	
Total		30
* Index (I) is a numerical estimate of the extent of the morphological changes.		

tory-regenerative and dysplastic epithelial lesions is shown in Table 3.

CK 7 was in 8 cases (8.2%) of inflammatory-regenerative colonic mucosa stained pale yellow (grade 1). The difference in antigen staining in the category of mild dysplasia in relation to category of inflammatory changes was highly significant ($p < 0.01$) (Table 3a). CK 7 was in 10 cases of mild dysplasia (9.2%), 3 cases of moderate dysplasia (5.1%) and in 4 cases of severe dysplasia (13.3%) stained

ochre-yellow (grade 2), and was stained brown (grade 3) in the rest of cases of all three categories of dysplastic lesions. Differences in antigen staining in epithelium with various grades of epithelial dysplasia were not significant (Table 3a). In all 3 cases of adenocarcinoma (7.5%) the antigen was stained pale yellow (grade 1).

All cases of mild, moderate, and severe dysplasia showed cytokeratin 7 staining along the entire crypt. Positive staining was always present in goblet-cells, absorptive cells, and undifferentiated cells.

Discussion

Cytokeratins are family of intermediate filaments with molecular weight between 40 and 68 kDa that are found in almost all epithelial cells. Epithelium of colonic mucosa contains low molecular weight proteins i.e. CK 8, 18 and 19 (7). Moll (1) stated that CK 20 is not always present, and even when it is found in colonic mucosa its quantity is very small. There are published studies stating possible alterations in expression of low molecular weight cytokeratins in some pre-malignant lesions of stomach (4) and colon (8). Loss of cellular differentiation is primarily accompanied with changes in the antigen expression scheme and after that changes in cellular morphology follow. Malignant potential of epithelial cells is not determined with changes in the expression of only one protein, but that quality can only be evaluated after examination of whole range of cellular antigens as well as those proteins located in basement membrane and extracellular matrix (9, 10).

Carcinoma "de novo" in flat bowel mucosa appears to develop through a multi-step process with progressive worsening of a precursor lesion called as "dysplasia". The multi-step process is known as the dysplasia-carcinoma sequence. This paper deals with dysplastic lesions of flat colonic mucosa and a way of expression of CK 7 is evaluated (that comprises of estimation of presence, way of distribution and intensity of staining) and compared with the one in normal colonic mucosa and colon "de novo" (adeno) carcinoma tissue. It is notified that CK 7 is not present in epithelium of normal colonic mucosa what is in compliance with the findings of other authors (11, 12, 13, 14). In inflammatory-regenerative mucosa it is discovered in only few cases and not in numerous cell population. It is found in all cases of ED with obvious and highly significant increase of antigen positive cells in grades of mild and moderate dysplasia. There was no significant alteration in expression of CK 7 in severe dysplasia in relation to moderate dysplasia. Significant decrease of CK 7 was notified in colon adenocarcinoma tissue in relation to severe dysplasia. In all grades of ED, in each individual case, all three types of epithelial cells contained CK 7. In adenocarcinoma tissue CK 7 was found in only three cases and was detected in small number of cells with minimal staining intensity, what is in compliance with the findings of other authors (13,15). In all three grades ED

antigen was always expressed in maximum staining intensity. Cytokeratin 7 is typical for ductal structures and can be observed in the pancreatic and bile duct as well as in the gallbladder. Some other epithelia also have CK 7, e.g. the urothelium. Epithelial cells of colorectal mucosa contain low-molecular weight keratins CK 8, CK 18, CK 19 and CK 20, but they do not stain with CK7. Production of

CK 7 was observed in epithelial dysplasia, that is regarded as pre-malignant tissue alteration and it disappeared with final malignant alteration of cells. Increased expression of this cytokeratin can be an attempt to maintain cellular integrity through incorporation of additional quantity of newly produced cytokeratins in existing system of intermediate filaments. In the course of hyperproliferation

Table 2. Immunoreactivity of CK 7 in normal colonic mucosa of 40 patients, inflammatory - regenerative and dysplastic flat colonic mucosa of 270 patients and colon adenocarcinoma tissue of 40 patients.

CK Type	% of positive stained cells	Normal mucosa N=40	Inflammatory - regenerative changes N=74	Epithelial dysplasia			Adenocarcinoma N=40
				Mild N=108	Moderate N=58	Severe N=30	
CK 7	0	49(100%)	66(89.3%)	0	0	0	37(92.5%)
	1	0	8(8.2%)	18(16.6%)	0	0	3(7.5%)
	2	0	0	36(33.3%)	7(12.0%)	5(16.6%)	0
	3	0	0	54(50.1%)	11(18.9%)	5(16.6%)	0
	4	0	0	0	40(68.9%)	20(66.6%)	0

0=no positive cells; 1=<25% cells stained; 2=25-50% cells stained; 3=50-75% cells stained; 4=>75% cells stained.

Table 2a. Results of the testing of differences for significance Table 2.

Morphological groups on which significance is derived	Degree of freedom	Value of Hi-quadrat test	Significance of differences between morphological groups and level of significance
1. Normal mucosa-inflammatory-regenerative changes	1	3.124	not significant
2. Normal mucosa-mild dysplasia	3	154.29	significant, p<0.05
3. Normal mucosa-moderate dysplasia	2	103.039	significant, p<0.05
4. Normal mucosa-severe dysplasia	2	69.636	significant, p<0.05
5. Normal mucosa-adenocarcinoma	1	1.385	not significant
6. Inflammatory-regenerative changes-mild dysplasia	3	159.59	significant, p<0.05
7. Mild dysplasia-moderate dysplasia	3	99.527	significant, p<0.05
8. Moderate dysplasia-severe dysplasia	1	0.375	not significant
9. Severe dysplasia-adenocarcinoma	1	65.976	significant, p<0.05

Table 3. Intensity of staining of different CK types in normal mucosa of 40 patients, inflammatory - regenerative and dysplastic flat colon mucosa of 270 patients and colon adenocarcinoma tissue of 40 patients.

CK type	Intensity of antigen staining (grade*)	Normal mucosa N=40	Inflammatory - regenerative changes N=74	Epithelial dysplasia			Adenocarcinoma N=40
				Mild dysplasia N=108	Moderate N=58	Severe dysplasia N=30	
CK 7	0	40(100.0%)	66(91.8%)	0	0	0	37(92.5%)
	1	0	8(8.2%)	0	0	0	3(7.5%)
	2	0	0	10(9.2%)	3(5.1%)	4(13.3%)	0
	3	0	0	98(90.7%)	55(94.8%)	26(86.6%)	0

*Grade: 0 = not stained; 1 = pale yellow; 2 = ochre; 3 = brown.

of epithelial cells during dysplastic changes, it is possible to hypothesise the occurrence of additional cytokeratins, which are unusually found in the simple epithelium of colon mucosa. The same atypical cytokeratins have been found in gastric carcinoma, for example CK 5, CK 7 and CK 13 (16). The biological role of this process was to increase a cellular stability, because additional cytokeratins would further enforce the intermediate filament system polymerisation from cytokeratin. Epithelial dysplasia include a loss of differentiation, which is comparable to lower level of maturation during embryogenesis (16). The gastric mucosa as well as the intestine and ductal structure of the gut develop from the proximal part of the embryonic intestine. This common histogenesis is reflected in the cytokeratin patterns of expression in the stroma and the intestine being related to the one of the pancreatic and bile duct as well as the gallbladder (16). The increasing proportion of CK 7 in the intermediate-sized filaments of the cytokeratins type of immature enterocytes and goblet cells also raised the question of the possible cell type-specific function(s) of this protein and the mechanisms by which this newly formed protein is integrated into the pre-existing formation of a polar cytoskeletal architecture from other types CK, e.g. CK 8, 18 and 19. Although the

mechanisms that regulate a production of different keratins have not yet been elucidated, the process is dependent on the interaction of several genes and the maturation process is influenced by changes in the microenvironment (17). With the finalised malignant transformation of cell this attempt faced its final breakdown. This idea needs to be supported with a research of the exact mechanisms involved in this process. A detection of same keratins could be useful in order to understand the relationship between dysplasia and invasive carcinoma. In some carcinomas of various origins, keratins can be masked, suppressed or modified (18).

The selective and consistent expression of the CK 7 gene in the dysplastic cells, makes the CK a valuable histological marker for the identification of such cells. The anti-cytokeratin 7 antibody, combined with H&E morphology, may be a helpful tool in the differential diagnosis of epithelial dysplasia in flat bowel mucosa in a routine examination of biopsies. As CK 7 was primarily found in dysplastic lesions of the flat colonic mucosa it can be regarded as a marker of epithelial dysplasia.

Table 3a. Results of testing of Table 3.

Morphological groups tested for significance	Degree of freedom	Value of Hi-quadrate test	Conclusion on significance of differences between morphological groups and level of significance
CK 7			
1. Normal mucosa - inflammatory-regenerative changes	1	3.14	not significant
2. Normal mucosa - mild dysplasia	1	37.845	significant, $p < 0.005$
3. Normal mucosa - moderate dysplasia	1	93.904	significant, $p < 0.005$
4. Normal mucosa - severe dysplasia	1	65.976	significant, $p < 0.005$
5. Normal mucosa - adenocarcinoma	1	1.385	not significant
6. Inflammatory-regenerative changes - mild dysplasia	2	163.15	significant, $p < 0.005$
7. Mild dysplasia - moderate dysplasia	1	0.398	not significant
8. Moderate dysplasia - severe dysplasia	1	0.499	not significant
9. Severe dysplasia - adenocarcinoma	1	65.976	significant, $p < 0.005$

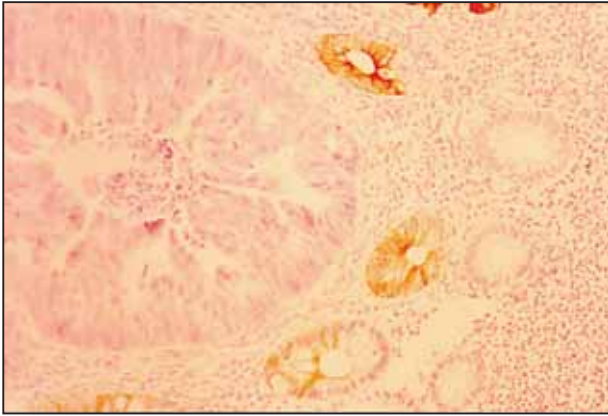


Figure 1. Positive cytoke-
ratin 7 staining limited to low
dysplastic epithelial cells. (X100)

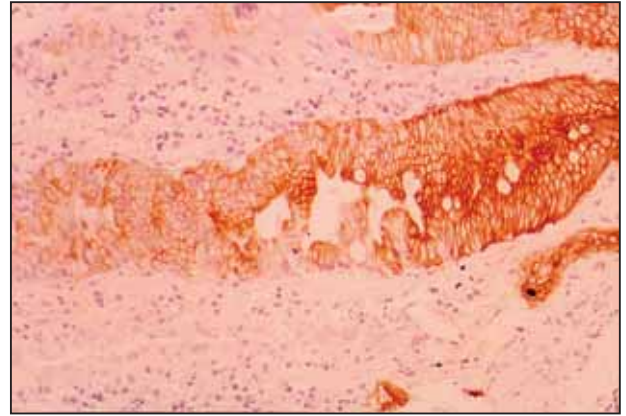


Figure 2. Cytoke-
ratin 7 is strongly immunoreactive in
moderate than low dysplastic epithelial cells. Note that
the entire inflammatory-regenerative epithelium is CK 7
negative. (X 100)

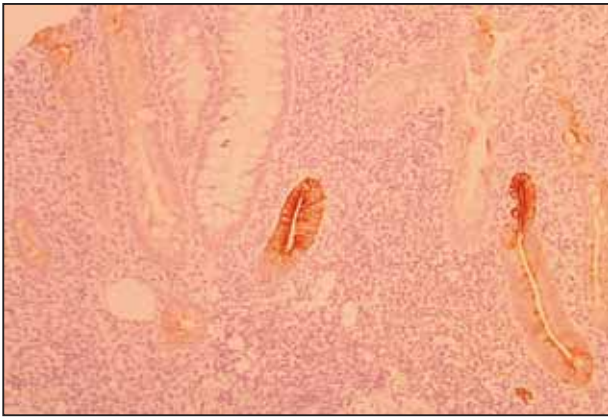


Figure 3. Severe dysplastic epithelial cells showing dif-
fuse cytoplasmic staining for cytoke-
ratin 7. (X 250)

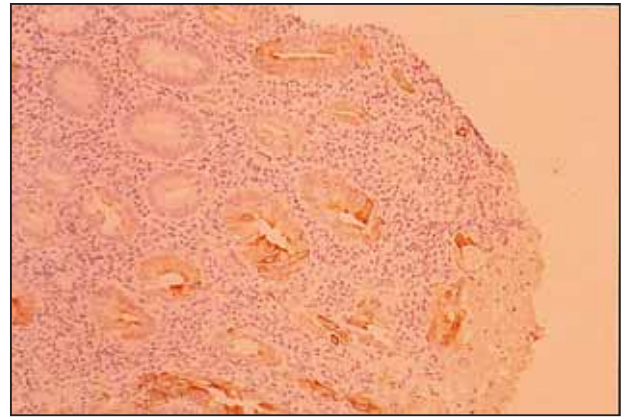


Figure 4. Note the restriction of moderate positive stain-
ing for cytoke-
ratin 7 to dysplastic epithelial cells. There is
no staining in the cell of carcinoma. (X 250)

References

- (1) Moll R., Franke W.W., Schiller D.L., Geiger B., Krepler B. The catalogue of human cytokeratins: patterns of expression in normal epithelia, tumors and cultured cells. *Cell* 1982; 31:11-24.
- (2) Application of cytokeratin 7 and 20 immunohistochemistry to diagnostic pathology. *Current Diagnostic Pathology* 2001; 7: 113-122.
- (3) Mallofre C., Cardesa A., Campo E., Condom E., Palacin A., Garin-Chesa P., Traserra J. Expression of cytokeratins in squamous cell carcinomas of the larynx: Immunohistochemical analysis and correlation with prognostic factors. *Path. Res. Pract.* 1993; 189: 257-282.
- (4) Schwerer M.J., Baczako K. Expression of cytokeratins typical for ductal and squamous differentiation in the human stomach: an immunohistochemical study of normal foveolar epithelium, *Helicobacter pylori* gastritis and intestinal metaplasia. *Histopathology* 1996; 29: 131-137.
- (5) Coltrera M.D., Zarbo R.J., Sakr W.A., Gown A.M. Markers for dysplasia of the upper aerodigestive tract. Suprabasal expression of PCNA, p53 and CK 19 in alcohol-fixed, embedded tissue. *Am. J. Pathol.* 1992; 141:817-825.
- (6) Nikulin A., Radovi} S. Razrada morfolo{kih kriterija za dijagnosticiranje displasti-nih promjena u sluznici debelog crijeva (Analysis of morphological criteria for the diagnosis of dysplastic changes in the colon mucosa). *Radovi ANUBiH, odjeljenje medicinskih nauka* 1991; 25: 33-43.
- (7) Bartek J., Vojte{ek B., Stra{kova Z., Bartkova J., Kerekes Z., Rejthar A., et al. A series of 14 monoclonal antibodies to keratins: characterization and value in diagnostic histopathology. *J. Pathol.* 1991; 164: 215-224.
- (8) Ahnen D., Warren G., Bown W. Search for specific marker of mucosal dysplasia in chronic ulcerative colitis. *Gastroenterology* 1987; 93: 1346-1355.
- (9) Fisseler-Eckhoff A., Prebeg M., Voss B., Muller K.M. Extracellular matrix in preneoplastic lesions and early cancer of the lung. *Path. Res. Pract.* 1990; 186: 95-101.
- (10) Antonelli A.R., Nicolai P., Cappiello J., Peretti G., Molinari Tosatti M.P., et al. Basement membrane components in normal, dysplastic, neoplastic laryngeal tissue and metastatic lymph nodes. *Acta Otolaryngol.* 1991;111: 437-443.
- (11) Cooper D., Schermer A., Sun T. Biology of disease. Classification of human epithelial and their neoplasms using monoclonal antibodies to keratin. Strategies, amplification, and limitation. *Lab. Invest.* 1985; 52: 243-256.
- (12) Cooper H.S., Steplewski Z. Immunohistologic study of ulcerative colitis with monoclonal antibodies against tumor-associated and/or differentiation antigens. *Gastroenterol* 1988; 95:686-693.
- (13) Wang M.P., Zee S., Zarbo J.R., et al. Coordinate expression of cytokeratin 7 and 20 defines unique subsets of carcinomas. *Appl. Immunohistochem.* 1995; 3: 99-107.
- (14) Loy T.S., Calaluce R.D. Utility of cytokeratin immunostaining in separating pulmonary adenocarcinomas from colonic adenocarcinomas. *Am. J. Clin. Pathol.* 1994; 102: 764-767.
- (15) Ramaekers F.C., Van Niekerk C.C., Poels L., et al. Use of monoclonal antibody to keratin 7 in the differential diagnosis of adenocarcinomas. *Am. J. Pathol.* 1990; 136: 641-655.
- (16) Moll R. Cytokeratins as markers for differentiation: expression profiles in epithelia and epithelial tumors. Stuttgart: Gustav Fischer, 1993.
- (17) Doran T.I., Vidrich A., Sun T.T. Intrinsic and extrinsic regulation of the differentiation of skin, corneal and esophageal epithelial cells. *Cell* 1980; 22: 17.
- (18) Moll R., Krepler R., Franke W.W. Complex cytokeratin polypeptide patterns observed in certain human carcinomas. *Differentiation* 1983; 23: 256-269.