

ANGIOGRAPHY ANALYSIS OF VARIATIONS OF THE POSTERIOR SEGMENT OF THE CIRCLE OF WILLIS

ALMA VOLJEVICA*, AMELA KULENOVIĆ,
ELDAN KAPUR, ILVANA VUČKOVIĆ

Institute of Anatomy, Faculty of Medicine, University of Sarajevo,
Čekaluša 90, 71000 Sarajevo, Bosnia and Herzegovina

* Corresponding author

ABSTRACT

Cerebral-vascular diseases present one of the leading problems of the modern mankind. They are followed by the risk of high mortality rate, and as such cause high level of disability with people who survive cerebral-vascular incident (stroke, apoplexy). Researches done so far proved that beginning, course and result of the cerebral-vascular diseases depend immensely of the possibility to establish collateral blood circulation and first of all on so called tertian level that is actually the circle of Willis. The circle of Willis, thanks to communicating segments, provide detour way to procure parts of the brain which, due to insufficiency, do not get enough quantity of blood. In this particular study by the analysis of 150 MRI patient's angiographies of the circle of Willis that had been processed at the Radiology Institute of the Clinic Center of University in Sarajevo, we tried to present the most common variations of the posterior segment of the circle of Willis with patients who did not have signs of the cerebral-vascular diseases. The analysis included two target groups (above 60 years old and younger than 34 years old) and both genders. By the analysis of the angiographies of the circle of Willis we reached following results: complete posterior configuration of the circle of Willis has been found with all patients in 54% of cases, but in some slightly higher percentage complete posterior configuration is noted with younger category of patients compared to elderly patients, and in some higher percentage with female compared to male patients. Out of variations that damage the posterior segment of the circle of Willis the first one, according to the frequency of occurring, is the variation of the type of unilateral fetal sort of posterior cerebral artery, and then the variation marked as unilateral aplasia or hypoplasia of the posterior communicating artery.

KEY WORDS: the circle of Willis, MR- angiography, variations

INTRODUCTION

The posterior segment of the circle of Willis is consisted of right and left arteria communicans posterior, final prong arteriae basilaris and initial parts of the posterior brain artery. Collateral function of the posterior segment of the circle of Willis had been described by the creator of theory, Thomas Willis in its study written in 1664 (1). The finding that was discovered that communicating segments of the circle of Willis function as valvular mechanism even during the physiological state of the organism forced many authors to research this issue. During the researches done in this field it has been found that when flexion and especially when head extension, the compression of the vertebral arteries occurs and when rotation and lateroflexion, the compression of the arteriae carotis internae and arteriae carotis communis occurs. In cases of occlusion of some brain artery, the transfer of blood from one system into another might be much intensive. When the occlusion of both carotides, the blood from basilar artery transfers into front parts that were procured with carotid blood circulation, and when occlusion of the vertebral artery the blood from carotid arteries transfers into the back parts. In both cases, the most important anastomoses vessel is the arteria communicans posterior (ACoP), through which blood is transferred into one or another flow. When the occlusion of one carotid, blood comes from the same name artery of the opposite side through arteria communicans anterior and from basilar artery through arteria communicans posterior. However, this blood reshuffling can be minimal or it should not happen at all, if there are certain anatomy variations of the components of the circle of Willis. The variations of the following types like aplasia, hypoplasia and incompatibility of certain components of the circle of Willis have the highest possible importance because they cause anatomy and functional interruption of the continuity of the circle of Willis (2). Thanks to their researches, clinic staff reached common ground that patients vary in their compensatory capability, in case the change occurs in the cerebral flow. Occlusion of carotid artery with one person can be followed by temporary neurological deficit or there are no any other symptoms, while other person can get heart attack infarction of bigger part of one cerebral hemisphere. These differences are without any doubts in relation with existence or non existence of adequate cerebral blood circulation, clinic staff stated (3,4,5). Functional efficiency of the collateral blood circulation in post-occlusion states depends of the huge number of factors: the number of anastomoses

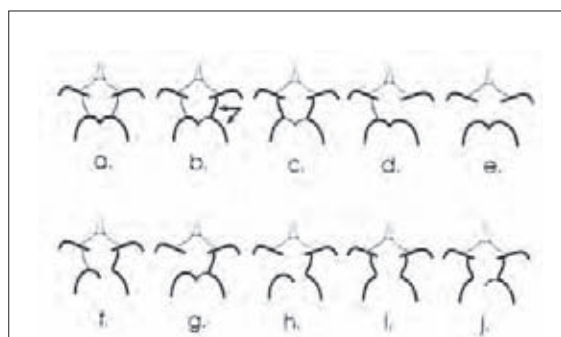
and their calibre, state of complete cerebral-vascular system (existence and absence of arteriosclerosis), vascular variations and anomalies, speed of occlusion occurrence (trombosis or embolia), system artery pressure, volume and viscosity of the blood (6).

STUDY'S OBJECTIVE

The objective of this study is to examine the presentation of variations of the posterior segment of the circle of Willis in percentages with the patients with regular cerebral-vascular status by application of the MRI-angiography.

MATERIAL AND METHODS

MRI – angiography analysis of the circle of Willis is performed on 150 angiographies of adults of both genders and age of 25 - 75 years old in two target groups; group of 50 patients of 25 – 34 years old, and group of 100 patients of 60 - 75 years old, who do not have any signs of the cerebral-vascular diseases, with the aim to compare the results considering the gender and age. These angiographies were done on the devices MAGNETOM IMPACT „Simens” of 1,0 Tesla technique 3D TOF- time of flight. All check-ups started with the DUAL sequence PD (TR/TE 2500-2625/16), T2 TSE (TR/TE 2500-4186/98), and T1SE sequence (TR/TE 500-693/15) for coronary angiographies in layers of 3 and 5 mm, on which we have analysed the anatomy and variations of the circle of Willis on different levels. We analysed the types of configurations of the circle of Willis on the axial and coronary MRI scannes in T1 and T2 relaxation. Morphological analysis comprised the analysis of the anterior segment of the circle



HEME 1. Presentation of variation of the posterior segment of the circle of Willis, used for the development of this study.

PREVALENCE OF VARIANTS IN THE POSTERIOR PART OF THE CIRCLE OF WILLIS

PREVALENCE OF COMPLETE POSTERIOR

CONFIGURATION

GROUP	a	b	c	d	e	f	g	h	i	j	
YEARS											
25 - 34	19	13	0	12	3	0	3	0	0	0	32
n=50	38,0%	26,0%	0,0%	24,0%	6,0%	0,0%	6,0%	0,0%	0,0%	0,0%	64,0%
>60											
	26	15	8	28	10	4	6	1	1	1	49
n=100	26,0%	15,0%	8,0%	28,0%	10,0%	4,0%	6,0%	1,0%	1,0%	1,0%	49,0%
SEX											
MALE	21	13	1	22	7	4	2	0	0	0	35
n=70	30,0%	18,6%	1,4%	31,4%	10,0%	5,7%	2,9%	0,0%	0,0%	0,0%	50,0%
FEMALE	24	15	7	18	6	0	7	1	1	1	46
n=80	30,0%	18,8%	8,8%	1,3%	7,5%	0,0%	8,8%	1,3%	1,3%	1,3%	57,6%
ALL SUBJECTS											
	45	28	8	40	13	4	9	1	1	1	81
n=150	30,0%	18,7%	5,3%	26,7%	8,7%	2,7%	6,0%	0,7%	0,7%	0,7%	54,0%

TABLE 1. Presents the variations of the back segment of the circle of Willis considering the gender and age. We have marked in red colour the variations that mean complete posterior configuration of the ring. The table itself does not contain data (in percentages) on frequency of particular variations occurring, as well as representation of that variation compared to all patients.

of Willis with the assistance of previously set forth criteria. We have used in this analysis partially modified classification that was also used by German authors Lippert H. and Pabst R. in their study published in 1985 (7), and that was result of the summerized results of the up to date researches of the circle of Willis .

RESULTS OF THE STUDY

By the analysis of variations of the posterior segment of the circle of Willis we have reached the following results presented comprehensively in Table 1. We have marked in red colour variations that means complete posterior configuration of the circle. The table itself does contain data (in percentages) on frequency of particular variations occurring, as well as representation of that variation in percentages compared to all patients. Based on the presented results, we can conclude that configuration of the posterior segment of the circle of Willis of **the type a** is the most common occurrence among the patients (normal configuration characterized by existence of both posterior cerebral arteries), (Figure 1.) This type of configuration is noticed in higher percentage with young patients that immensely contributed to higher representation (in percentages) of their complete back configuration compared to older patients. Regarding variations that affect the incompleteness of

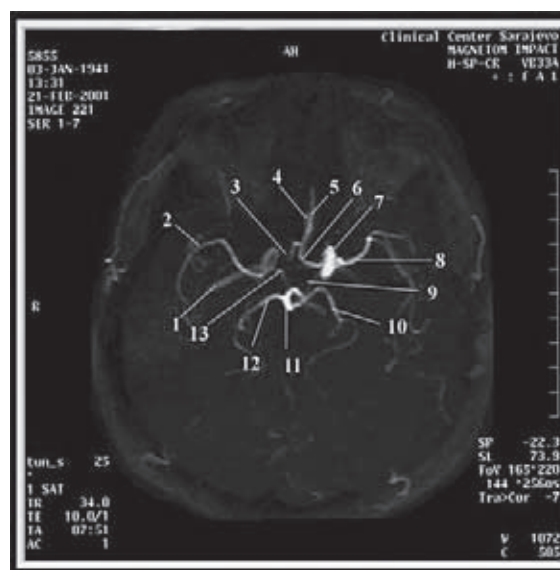


FIGURE 1. MR angiography 60 years old man with posterior configuration of the circle of Willis of the type a (normal configuration with both posterior communicating artery)

1. right internal carotid artery
2. right middle cerebral artery
3. right anterior cerebral artery (part precommunicating)
4. right anterior cerebral artery (part postcommunicating)
5. left anterior cerebral artery (part postcommunicating)
6. left internal carotid artery
7. left middle cerebral artery
8. left posterior communicating artery
9. left posterior cerebral artery
10. basilar artery
11. right posterior cerebral artery
12. right posterior communicating artery

the circle of Willis, we have marked in our study the highest percentage of variation of **type d** (configuration characterized by unilateral aplasia or hypoplasia of posterior communicating artery) (Figure 2.), **type e** (hypoplasia or aplasia of both communicating arteries) and finally configuration of the **type g** (unilateral fetal type of posterior cerebral artery with hypoplasia or aplasia of conter-lateral posterior communicating artery) (Figure 3.).

DISCUSSION

Researches done so far showed that the most common variation that damage arteries of the circle of Willis is hypoplasia of one or both posterior communicating arteries. According to the references this variation is occurring in 22-32% of cases (8,9). Our research material show that variation marked as unilateral hypoplasia of posterior communicating artery is on the first place according to the frequency of occurrence. This variation has been noted with younger target group of patient precisely in 24% of cases and bilateral hypoplasia in 6% of cases. As the

older target group of patients, unilateral hypoplasia is noted in 28% of cases and bilateral hypoplasia in 10% of cases. As male population, unilateral hypoplasia has been registered in 31,6% of cases compared to 22,5% that is registered with female target group of patients. Bilateral hypoplasia left and right of posterior communicating artery is registered in 10% of cases, males patients compared to 7,5% of cases, female patients. According to up to date researches, the variation known as fetal type of posterior cerebral artery is on the second spot according to frequency of occurrence. This type of variation is characterized by carotid origine of posterior cerebral artery while posterior communicating artery has higher caliber compared to posterior cerebral artery. This variation in the studies is recorded in 15-22% of cases (10,11). Our research material show that unilateral fetal type has been registered with target group of young patients precisely in 6% of cases, and with target group of older patients in 10% of cases, where 2,9% with male patients and 10,1% registered with female patients. These results slightly deviate from the up to date results of the researches.

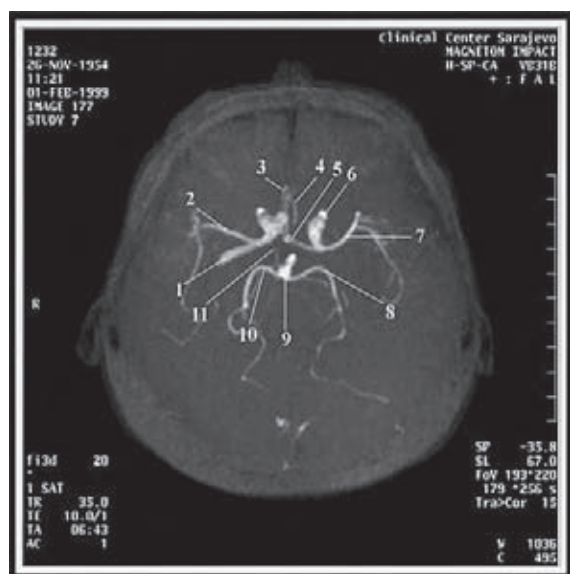


FIGURE 2. MR angiography 45 years old females with posterior configuration of the circle of Willis of the type d (unilateral aplasia of posterior communicating artery)

- | | |
|--|--|
| 1. right internal carotid artery | 7. left middle cerebral artery |
| 2. right middle cerebral artery | 8. left posterior cerebral artery |
| 3. right anterior cerebral artery (part postcommunicating) | 9. basilar artery |
| 4. left anterior cerebral artery (part postcommunicating) | 10. right posterior communicating artery |
| 5. left anterior cerebral artery (part precommunicating) | 11. right posterior communicating artery |
| 6. left internal carotid artery | |

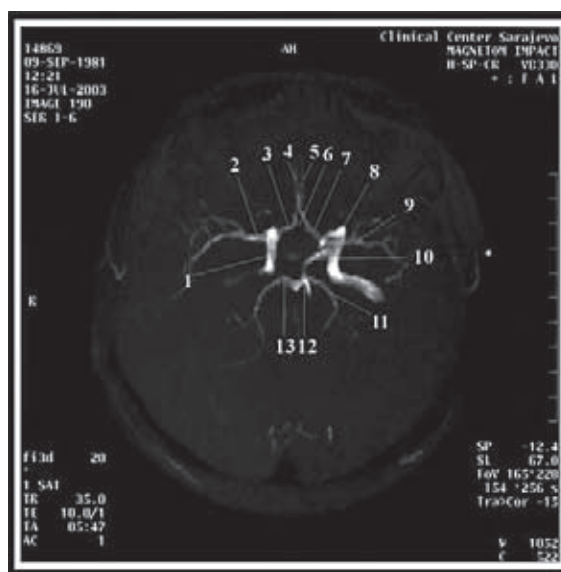


FIGURE 3. MR angiography 22 years old females with posterior configuration of the circle of Willis of the type g (unilateral fetal type of posterior cerebral artery with aplasia of conter-lateral posterior communicating artery)

- | | |
|--|--|
| 1. right internal carotid artery | 8. left internal carotid artery |
| 2. right middle cerebral artery | 9. left middle cerebral artery |
| 3. right anterior cerebral artery (part precommunicating) | 10. left posterior communicating artery |
| 4. right anterior cerebral artery (part postcommunicating) | 11. fetal type of left posterior cerebral artery |
| 5. left anterior cerebral artery (part postcommunicating) | 12. basilar artery |
| 6. anterior communicating artery | 13. right posterior cerebral artery |
| 7. left anterior cerebral artery (part precommunicating) | |

CONCLUSION

On the basis of the radiology-anatomy analysis of the circle of Willis we have made following conclusions:

1. Variation of posterior segment of the circle of Willis are often more presented with older patients than young patients;
2. Complete configuration of posterior segment is presented more (in percentages) with young patients than the older patients;
3. Higher percentage of the complete configuration of posterior segment has been registered with female patients than male patients;
4. According to frequency of occurrence, out of variations of the posterior segment, the variation noted as unilateral fetal type of posterior cerebral artery is registered on the first place and variation noted as unilateral aplasia or hypoplasia of the posterior cerebral artery on the second place.

REFERENCES

- (1) Thomas Willis *Cerebri Anatome*, 1664.
- (2) Lazorthes G. et al. *Vascularisation et circulation de l'encéphale*. Masson, Paris 1976.
- (3) Marinković S., Milisavljević M.: *Arterije mozga- anatomske i kliničke karakteristike*, Bit inženjering, Beograd, 1990;
- (4) Hoksbergen A.W.J., Legemate D.A, Ubbink D.T, de Vos H. J, Jacobs M.J.H.M. Influence of the collateral function of the circle of Willis on hemispherical perfusion during carotid occlusion as assessed by transcranial colour-coded duplex ultrasonography. *Eur J Vasc Endovasc Surg*. 1999;17:486–492.
- (5) Kwiecinski J., Pierzchala K., Kapustecki J. Increased cerebrovascular reactivity and risk factors for ischaemic stroke in patients with inadequate circulation in the posterior circle of Willis, *Wiad Lek*. 2003;56(7-8):319-23.
- (6) Jongen J.C., Franke C.L., Ramos L.M., Wilmink J.T, van Gijn J. Direction of flow in posterior communicating artery on magnetic resonance angiography in patients with occipital lobe infarcts. *Stroke* 2004 35(1):104-108.
- (7) Lippert H., Pabst R. Cerebral arterial circle (circle of Willis). In: Lippert H., Pabst R.: *Arterial variations in man: classification and frequency*, Munich, Germany, Bergmann, 1985; 92-93;
- (8) Krabbe-Hartkamp M.J, van der Grond J., de Leeuw F.E., de Groot J.C., Algra A., Hillen B., Breteler M.M.B, Mali W.P.T.M. Circle of Willis: morphologic variation on three-dimensional time-of-flight MR-angiograms. *Radiology*. 1998;207:103–111.
- (9) Macchi C., Catini C., Federico C., Gulisano M., Pacini P., Cecchi F., Corcos L., Brizzi E. Magnetic resonance angiographic evaluation of circulus arteriosus cerebri (circle of Willis): a morphologic study in 100 human healthy subjects. *Ital J Anat Embryol*. 1996;101:115–123.
- (10) Orlandini G.E, Ruggiero C., Orlandini S.Z, Gulisano M. Blood vessel size of circulus arteriosus cerebri (circle of Willis): a statistical research on 100 human subjects. *Acta Anat*. 1985;123:72–76.
- (11) Shomer D.F., Marks M.P., Steinberg G.K., Johnstone I.M., Boothroyd D.B., Ross M.R., Pelc N.J., Enzmann D.R. The anatomy of the posterior communicating artery as a risk factor for ischemic cerebral infarction. *N Engl J Med*. 1994;330:1565–1570.