

# ERYTHEMA NODOSUM AND LUNG AILMENTS AT THE CLINIC FOR DERMATOLOGICAL AND VENEREAL DISEASES IN SARAJEVO FROM 1989 TO 2005

FARUK ALENDAR\*

Department of Dermatovenerological Diseases, University of Sarajevo Clinics  
Center, Bolnicka 25, 71000 Sarajevo, Bosnia and Herzegovina

\* Corresponding author

## ABSTRACT

In 15 years period (1989 – 2004) we have treated at our Clinic a total of 101 patients diagnosed with erythema nodosum which makes 2,9% of the total number of patients treated in this period. In order to explore correlation between dermatological and lung diseases we applied statistical analysis with respect to number, sex, age and irregularities occurring on the skin surface. Female patients dominated with 96 of them (95,6%) in the group, while only five patients were male (4,3%). This makes 22 : 1 scale in favor of female patients, as opposed to usual 5:1 ratio. Similar predominance (86%) was found in the study conducted by Mert and Gurkan (1,2). Average age of the patients was 41,6 years, which is slightly higher than the average of 18 and 34. The youngest patient was 17 and oldest 77.

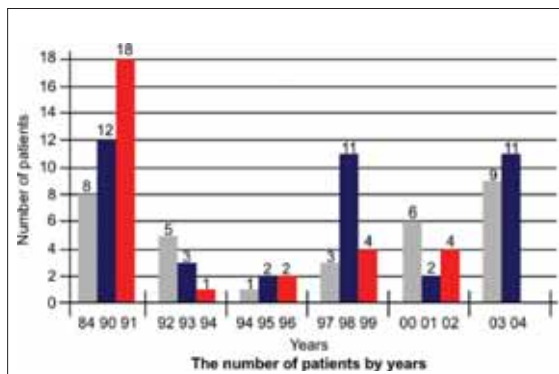
**KEY WORDS:** erythema nodosum, lung, skin.

## INTRODUCTION

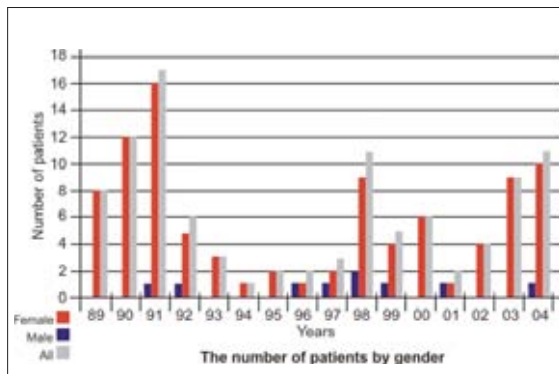
Erythema nodosum is an allergic reaction of the skin to different organic and nonorganic agents. It appears as a temporary emergence (eruption) of efflorescences appearing on the extensory side of lower extremities. It has not yet been established if erythema nodosum is a disease of immune system that leads to accumulation of immune complexes in blood vessels causing the inflammatory process in septa between subcutaneous fat lobuli or if it is allergic reaction of the delayed kind (3). Extensory side of the lower leg is the most frequent localization of erythema nodosum. In 78 patients (69,8%) symptoms were exclusively found in that position, while 23 (24,6%) of them exhibited erythema above the knee. Only 4 patients exhibited these changes on upper and lower extremities (4). Common infectious causes of erythema nodosum are streptococcal, staphylococcal infections as well as leprosy syphilis. Viral infections in most cases disease follow flu, morbilli, psittacosis, ornithosis, and the cat scratch disease. By order of frequency the first is streptococcal infection that occurred in all patients (15,9%). Most of them had chronic tonsillitis. Staphylococcal infection preceded erythema nodosum in 4 cases (5,7%). Tuberculosis etiology was recorded in 2 cases. Both of those were primary infections. Medicaments caused erythema nodosum was found in two cases. Both cases followed sulfonamide and analgesics treatment. Three pregnant women discovered erythema, one of them in the third month of pregnancy the other two in the fourth. In 6 patients pregnancy was discovered alongside erythema (5,6). Erythema nodosum is an inflammatory dermatosis which affects hypodermis and the fat tissue. The disease characterizes high febrility and erythematous areas on the extensory side of the lower leg, and sometimes on the hips and forearms. Palpation indicates that it is not only erythema but also painful to touch nodosum of few centimeters in diameter that never exulcerate (5,7,8). Disease usually lasts for 2-3 weeks and it tends to relapse.

## METHODS AND MATERIALS

The study included all of the 101 patients who were diagnosed with erythema nodosum at the «Clinic for Dermatological and Venereal Diseases» in the last 15 years (Januar 89 to Decembar 2004). All of the patients were statistically analyzed with respect to number, sex, age, and irregularities that appeared on the skin surface. The study was focused on exploring correlation between dermatological and lung diseases.



GRAPH 1. The number of patients by years



GRAPH 2. The number of patients by gender

## RESULTS

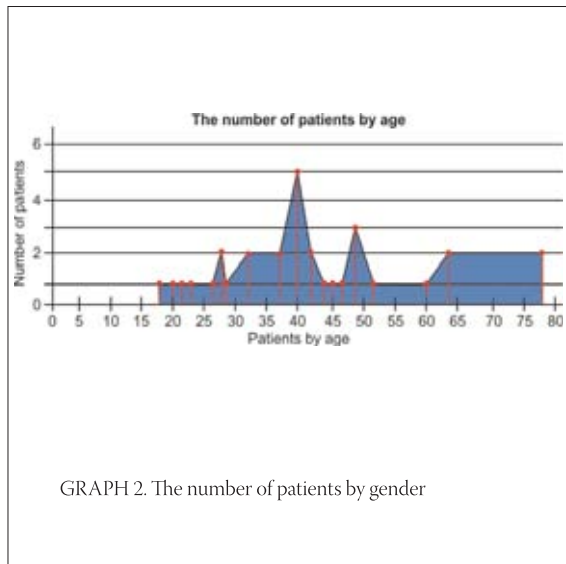
In the 15 years period we have treated a total of 101 patients diagnosed with erythema nodosum at our clinic which makes 2,9% of the total number of patients treated in this period as inpatients.

### GENDER BREAKDOWN

Predominant group was female including 96 of them (95,6%), while only five patients were male (4,3%). This creates 22 : 1 scale in favor of female patients, as opposed to usual 5 : 1 ratio (Graph 2). Similar predominance (86%) was found in the studies conducted by Mert A. and Gurkan (1,2).

### AGE

Average age of the patients was 41,6 years, which is slightly higher than the average of 18 and 34. The youngest patients was 17 and oldest 77 (Graph 3).



#### LOCALIZATION OF THE SKIN CHANGES

Extensory side of the lower leg is the most frequent localization of erythema nodosum. In 78 patients (69,8%) symptoms were exclusively found in that position, while 23 (24,6%) of them exhibited erythema above the knee. Only 4 patients exhibited these changes on upper and lower extremities (3).

#### LABORATORY RESULTS

All the admitted patients were subjected to a round of routine lab checkups such as: PPD, ASTO, WAALER ROSE, Lung X ray, CT of thoracic organs. Most of the patients were tested for focuses. Accelerated erythrocyte sedimentation upon arrival was found in 89 patients (85,5%) with average value of 43 in the first hour. Only 10 of the patients had regular sedimentation (14,4%). In 15 patients extreme leukocytosis was registered in peripheral blood. Pathological changes in lungs were

found in 53 patients out of 75 tested (4,9). X-rays registered bilateral increase of hilar lymphonods in 29 patients (27,5%). Fearing sarcoidosis we referred all those patients to Pulmology Clinic for further treatment. Our results are within 11-65% range established by Criber (6).

#### DISCUSSION

Erythema nodosum is an inflammatory dermatosis that affects hypodermis and the fat tissue. Disease is characterized by high febrillity and erythematous areas on the extensory side of the lower leg, and sometimes on the hips and forearms. Pulpation indicates that it is not only erythema but also painful to touch nodosum of few centimeters in diameter which never exulcerate. Disease usually lasts for 2-3 weeks and it tends to relapse (10,11). Erythema nodosum is considered to be an autoimmune response of the body to different (various) etiological agents, or a sign of decreased immunological defense of a body. In our sample concomitant illnesses were diabetes mellitus (in 2 cases), malignancy in 2 cases (both ovarian tumors), dermatomyositis in 1 patient and enteropathies in 2 patients. In 8 patients we were not able to determine etiological factor, which concurs with the results of the research done in this area worldwide (12,13). We can conclude that our results are consistent with literature data that indicate significant gender differences and connection with decrease in immune response of the body (14,15). Erythema nodosum often appears as a side effect of sarcoidosis. In many cases it is the first symptom. Early diagnosis of sarcoidosis is of great importance so that therapy applied in timely manner. Therefore, the cooperation of pulmonologists and dermatologists is of immense value (16).

#### CONCLUSION

1. In our sample it is proven (and consistent with literature data) that gender difference is an important finding among the patient with erythema nodosum.
2. Most of the patients were 40 years old.
3. Erythema nodosum is in the majority of cases prodromal sign of lung sarcoidosis.
4. Early and correct diagnosis and adequate therapeutic approach are of crucial importance for therapeutical outcome and for the prevention of the underlined disease.

## REFERENCES

- (1) Mert A., Ozaras R., Tabak F., Pekmezci S., Demirkesen C., Ozturk R. Erythema nodosum: an experience of 10 years. *Scand. J. Infect Dis.* 2004; 36(6-7):424-427.
- (2) Gurkan O.U., Celik G., Kumbasar O., Kaya A., Alper D. Sarcoidosis in Turkey: 1954-2000. *Ann Saudi Med.* 2004; 24(1):36-39.
- (3) Faure M.D., Schwartz R.A. Erythema nodosum. *Am. Fam. Physician* 1992; 46(3): 818-822.
- (4) Yanardag H., Pamuk ON., Karayel T.: Cutaneous involvement in sarcoidosis: analysis of the features in 170 patients. *Respir Med.* 2003;97(8):978-982.
- (5) Puavilai S., Sakunthabai A., Sriprachaya-anunt S., Rajatanavin N., Charuwichitratana S. Etiology of erythema nodosum. *J. Med. Ass. Thai.* 1995; 78(2): 72-75.
- (6) Amoli M.M., Liorca J., Gomez-Bigirey A., Garcia-Porrúa C., Lueiro M., ElMagadmi M., Fernandez ML., Ollier WE., Gonzales-Gay MA. E-selectin polymorphism in erythema nodosum secondary to sarcoidosis. *Clin. Exp. Rheumatol.* 2004; 22(2):230-232
- (7) Hoffmann A.L., Milman N., Byf K.E. Childhood sarcoidosis in Denmark 1979-1994: incidence, clinical features and laboratory results at presentation in 48 children. *Acta Paediatr.* 2004;93(1):30-36.
- (8) Fetil E., Ozkan S., Ilknur T., Kavukcu S., Kusku E., Lebe B.:Sarcoidosis in a preschooler with only skin and joint involvement. *Pediatr. Dermatol.* 2003;20(5):416-418.
- (9) Marcoval J., Moreno A., Mana J.: Papular sarcoidosis of the knees: a clue for the diagnosis of erythema nodosum-associated sarcoidosis. *J. Am. Acad. Dermatol.* 2003;49(1):75-78.
- (10) Pileckyte M., Griniute R.: Erythema nodosum association with malignant lymphoma. *Medicina (Kaunas).* 2003; 39(5): 438-442. Review. Lithuanian.
- (11) Atanes A., Gomez N., Aspe B., et al.: Erythema nodosum: a study of 160 cases. *Med. Clin* 1991; 96 (5): 169-172
- (12) Bohn S., Buchner S., Itin P.: Erythema nodosum: 122 cases. Epidemiology, clinical aspects and histopathology. *Schweiz Wochenschr* 1997; 127(27-28): 1168-1176
- (13) Cribier B., Caille A., Heid E., Grosshans E. Erythema nodosum and associated diseases. A study of 129 cases. *Int. J. Dermatol.* 1998; 37(9): 667-672.
- (14) Hassink R.I., Pasquinelli – Egli C.E., Jacomella V., Laux – EndR, Bianchetti M.G. Conditions Currently associated with erythema nodosum in Swiss children. *Eur. J. Ped.* 1997; 156(11):851-853.
- (15) Kano Y., Shioara T., Yagita A., Nagashima M. Erythema nodosum, lichen planus, and lichen nitidus in Chron's diseases: report of a case and analysis of T cell receptor V gene Expression in the cutaneous and intestinal lesions. *Dermatol.* 1995; 190(1): 59-63.
- (16) Ozerova L.V. Erythema nodosum in sarcoidosis patients. *Probl. Tuberk.* 1993;(6):25-27.