



STEREOLOGICAL ANALYSIS OF MATURE HUMAN PLACENTA OF PREGNANT WOMEN OF DIFFERENT AGE

SUADA RAMIĆ^{1*}, ZLATA ŽIGIĆ¹, MIRNA ALEČKOVIĆ²

1. Department of Histology and Embriology, Faculty of Medicine, University of Tuzla, Univerzitetska 1, 75000 Tuzla, Bosnia and Herzegovina
2. Department of Cardiology, University Clinics Center Tuzla, Trnovac bb, 75000 Tuzla, Bosnia and Herzegovina

* Corresponding author

ABSTRACT

The normal placentas, regular pregnancies and deliveries were structurally examined. The aim of this research was to compare the results and to confirm if there were some difference in the structure of placenta related to the age of pregnant women. We examined 30 human placentas. The examined group of women were divided into two groups: 1) pregnant women 20-35 years old; 2) pregnant women over 35 years old. The stereological method was used. The volume density, absolute volume, the surface density and absolute surface of terminal villi of placentas in younger and older pregnant women were not significantly different. The volume density, absolute volume, the surface density and absolute surface of the other placenta villi in younger pregnant women compared to older ones, were significantly increased ($p < 0.001$). The volume density of fibrinoid of placentas in older pregnant women compared to younger ones was significantly increased ($p < 0.02$). The surface density, absolute volume and absolute surface of fibrinoid in these two examined groups of pregnant women were not significantly different. The volume density of intervillous space of placentas in older pregnant women compared to younger ones was significantly increased ($p < 0.05$). Absolute volumes of intervillous space of placentas in these two examined groups of pregnant women are not significantly different.

KEY WORDS: placenta, pregnant women of different age, stereology

INTRODUCTION

The basic functional unit of placenta is composed of chorionic villi with epithelial surface (trophoblast) and of mesenchymal origin stroma in which blood vessels are embedded. Numerous authors (1) classified types of the chorionic villi inside the villous tree depending on gestational period of their occurrence and on their function in the course of pregnancy. According to the morphological properties, parts of the villous tree of the mature human placenta are: stem villus, mature intermediary villus, and terminal villus. Morphological characteristic of the stem villi is stroma, rich in connective fibers. Mature intermediary villus is composed of stroma and most of blood vessels. Terminal villi are the final branches of the villous tree. Blood capillaries of these villi are very enlarged, and they occupy more than 50% of the stroma volume (1). Through the surface of these villi, materno-fetal exchange is done. Fibrinoid is either on the surface of the chorionic villi or among them. Placental fibrinoid is extracellular deposit material. Mass of fibrinoid indicates the gestational placental age. Surface villi fibrinoid replaces worn parts of syncytiotrophoblast (2). Two kinds of fibrinoids are evident according to origin, structure and function. Fibrin-type of fibrinoid is structured mostly of fibrin and molecules resulting in the course of blood clotting, or in the degeneration processes (3). Mayhew and Sampson (4) established that fibrin-type fibrinoid volume in the pregnancies complicated by diabetes is increased. In the pregnant women smokers placentas increased deposits of perivillous fibrinoid were found compared to non smokers (5). Intervillous space is found among chorionic villi and is filled by mother's blood. Because of the intervillous deposition of fibrinoids, intervillous space volume is physiologically decreasing after 36th week (6). In the available literature we have not found any evidence on the histologic structure of placenta related to the pregnant woman age. However, a great number of investigations focused on how a pregnant woman age impacts on a delivery outcome, i.e. on malformation occurrence in the course of pregnancy. Threatening abortions, preeclampsia and preterm deliveries occurred 2-4 times more frequently in the older pregnant women (7). Since quantitative researches on placentas of different age pregnant women were not performed stereologically in the Tuzla Canton region, our objectives were to analyse placentas of younger and older pregnant women morphologically and quantitatively, to find out if there were statistically significant differences among volume densities, absolute volumes, surface densities, and absolute surfaces of the chorionic

villas, fibrinoid and intervillous space in the tested placental groups. Morphological researches of placenta enable us to presume conditions for fetus formation and development, especially important in risky pregnancy (EPH gestosis, diabetes mellitus, older mothers).

MATERIAL AND METHODS

The research was carried out on 30 human placentas of normal pregnancy and normal delivery. The age of the pregnant women ranged from 20 to 45 years. They were divided into two groups: a) 20-35 years old pregnant women b) over 35 years old pregnant women. Gestational age of the tested groups of placentas (37 to 42 weeks) was determined according to the first day of the last menstruation. Amnion and umbilical cord were removed from each placenta. The placenta mass was measured by weighting, its volume was determined indirectly by measuring the liquid squeezed out. Tissue samples were taken through the thickness of the entire organ, from chorion to decidua basalis. The tissue was fixed in 10% water solution of neutral formalin then embedded in paraffin wax, cut into 8µm thick sections and stained by hematoxylin-eosin. Stereological analysis was done by multipurpose test-system M42, magnification 10x. Referential space was parenchyma of the placenta. Relative variables (are related to one part of tissue – 1cm³) and absolute variables (are related to entire organ) were stereologically examined and compared. Relative variables were determined as follows: 1) the volume density of terminal and other villi, fibrinoid, and intervillous space; 2) the surface density of terminal and other villi and fibrinoids. Absolute variables were determined as follows: the absolute volume and absolute surface of the cited structures. Significance of different results obtained by the stereological analysis of the different age pregnant women's placentas was estimated by F-test and t-test.

RESULTS

Referential space was made of terminal villi, other villi, fibrinoid and intervillous space (Figure 1) in this researches.

RELATIVE VARIABLES

Volume densities and surface densities of terminal villi (V_{vt}), other villi (V_{vo}), fibrinoid (V_{vf}) and intervillous space (V_{viv}) of both, younger and older pregnant women's placenta, are shown in the Table 1 and 2. Placentas of older pregnant women had significantly lower proportion of other villi and significantly higher proportion of intervillous space and perivillous fibrinoid in the volume unit, in comparison to placentas in the younger group.

ABSOLUTE VARIABLES

Absolute volumes and absolute surfaces of the terminal villi (Vt), other villi (Vo), fibrinoid (Vf) and intervillous space (Viv) of both younger and older pregnant women placentas are shown in Table 3 and Table 4.

DISCUSSION

In our research, placentas of older and younger pregnant women had similar values of volume density and surface density of terminal villi. Many authors have determined volume density of fibrinoids (Vvf) so far. They established that it amounts 1,8% (8), 3% (3) in a volume unit. In our researches placentas of the older pregnant women had significantly higher proportion of perivillous fibrinoid (placed on the free surface of the terminal villi) in the volume unit in comparison to placentas in the younger group. It means that lower part of trofoblast surface of terminal villi participates in materno fetal exchange (9).

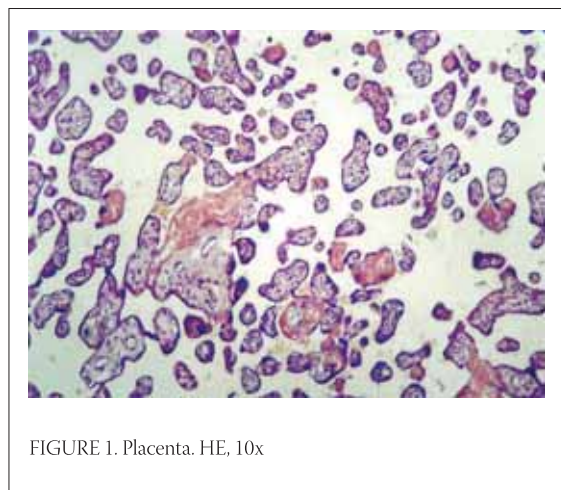


FIGURE 1. Placenta. HE, 10x

Volume density of the intervillous space is 29,3% (10), 55% (11) in the volume unit of placenta. According to our results the difference of the volume density of the intervillous space in the placenta of both younger and older pregnant women was statistically significant. It might be

DESCRIPTIVE STATISTICS	V _{Vtr,m} /mm ⁰ /	V _{Vtr,s} /mm ⁰ /	V _{Vor,m} /mm ⁰ /	V _{Vor,s} /mm ⁰ /	V _{Vf,m} /mm ⁰ /	V _{Vf,s} /mm ⁰ /	V _{Viv,m} /mm ⁰ /	V _{Viv,s} /mm ⁰ /
X	0,43	0,41	0,07	0,05	0,05	0,06	0,45	0,47
SD	0,04	0,04	0,02	0,01	0,01	0,01	0,03	0,04
SE	0,009	0,01	0,005	0,003	0,003	0,003	0,008	0,01

X – mean SD – standard deviation SE – standard error

TABLE 1. Volum densities of terminal villi (V_{Vt}) other villi (V_{Vo}), fibrinoid (V_{Vf}) i intervillous space (V_{Viv}) of both younger (y) and older (o) pregnant women's placentas

DESCRIPTIVE STATISTICS	S _{Vtr,m} /mm ⁻¹ /	S _{Vtr,s} /mm ⁻¹ /	S _{Vor,m} /mm ⁻¹ /	S _{Vor,s} /mm ⁻¹ /	S _{Vf,m} /mm ⁻¹ /	S _{Vf,s} /mm ⁻¹ /
X	22,19	22,10	1,70	1,06	1,97	2,05
SD	1,56	1,87	0,51	0,16	0,36	0,54
SE	0,40	0,48	0,13	0,04	0,09	0,14

X – mean SD – standard deviation SE – standard error

TABLE 2. Surface densities of terminal villi (S_{Vt}), other villi (S_{Vo}), fibrinoid (S_{Vf}) in both younger (y) and older (o) pregnant women

DESCRIPTIVE STATISTICS	V _{Vtr,m} /cm ³ /	V _{Vtr,s} /cm ³ /	V _{Vor,m} /cm ³ /	V _{Vor,s} /cm ³ /	V _{Vf,m} /cm ³ /	V _{Vf,s} /cm ³ /	V _{Viv,m} /cm ³ /	V _{Viv,s} /cm ³ /
X	199,22	183,88	32,57	21,52	24,59	26,96	209,26	210,70
SD	36,64	41,47	8,79	5,72	6,43	7,08	37,91	41,57
SE	9,46	10,71	2,27	1,48	1,66	1,83	9,79	10,73

X – mean SD – standard deviation SE – standard error

TABLE 3. Absolute volume of terminal villi (V_t), other villi (V_o), fibrinoid (V_f) and intervillous space (V_{iv}) of both younger (y) and older (o) pregnant women's placentas

DESCRIPTIVE STATISTICS	S _{tr,m} /m ² /	S _{tr,s} /m ² /	S _{or,m} /m ² /	S _{or,s} /m ² /	S _{fm} /m ² /	S _{fs} /m ² /
X	10,34	9,86	0,77	0,47	0,88	0,95
SD	1,74	2,32	0,20	0,12	0,23	0,30
SE	0,45	0,60	0,05	0,03	0,06	0,08

X – mean SD – standard deviation SE – standard error

TABLE 4. Absolute surface of terminal villi (S_t), other villi (S_o) and fibrinoid (S_f) of both younger (y) and older (o) pregnant women's placentas

the result of: a) decreased number of villi or their size or b) impaired space arrangement of the villous tree in one cm³ of placental volume (9). The absolute surface of terminal villi has been frequently researched because it is the surface where the maternal – fetal exchanges

take place. The absolute surface of the terminal villi in the human placenta was 15 m² (8). In our researches placentas of the older and younger pregnant women had similar values of absolute volume and absolute surface of terminal villi, fibrinoid and intervillous space.

CONCLUSION

Results of our research show that of placenta in one cm³ of older pregnant women had a statistically significant higher proportion of fibrinoid and intervillous space. However, absolute volume of terminal villi, fibrinoid and intervillous space had similar values in both tested groups. That additionally explains physiology of placenta and confirms capability of older pregnant women placenta to induce compensational mechanisms, whose main role is providing the sufficient materno-fetal exchange.

REFERENCES

- (1) Castelluci M., Scheper M., Scheffeen I., Celona A., Kaufmann P. The development of the human placental villous tree. *Anat. Embriol.* 1990; 181: 117-128
- (2) Kaufmann P., Huppertz B., Frank H.G. The fibrinoids of the human placenta: origin, composition and functional relevance. *Anat. Anz.* 1996; 178 (6): 485-501.
- (3) Mayhew T.M., Bowles C., Orme G. A stereological method for testing whether or not there is random deposition of perivillous fibrin-type fibrinoid at the villous surface: description and pilot applications to term placentae. *Placenta* 2000; 21 (7): 684-692.
- (4) Mayhew T.M., Sampson C. Maternal diabetes mellitus is associated with altered deposit of fibrin-type fibrinoid at the villous surface in term placenta. *Placenta* 2003; 24 (5): 524-531.
- (5) Battistelli M., Burattini S., Pomimi F. Ultrastructural study on human placenta from intrauterine growth retardation cases. *Microssc. Res. Tech.* 2004; 65 (3), 150-158.
- (6) Honjoh Y., Nishimura Y., Kanomata N., Hanioca K., Itoh H., Kubota A. Morphological studies on the placenta. *Kobe J. Med. Sci.* 1994; 40 (1): 1-11.
- (7) Mikulandra F. Trudnoća u mlade i stare žene U: *Porodništvo*, ur. Dražančić A. Zagreb: Školska knjiga 302-303.
- (8) Grbeša Đ. Neka morfološka obilježja sinciotrofoblasta zrele humane placente. *Magistarski rad. Sveučilište u Zagrebu, Zagreb* 1984; 106-107.
- (9) Ramić S., Grbeša Đ., Žigić Z. Humana zrela posteljica u odnosu na životnu dob trudnice. *Gynaecol. Perinatol.* 2004; 13 (3): 101-105.
- (10) Bacon B.J., Gilbert R.D., Longo L.D. Regional anatomy of the term human placenta. *Placenta* 1986; 7: 233-241.
- (11) Teasdale F. Histomorphometry of the human placenta in maternal preeclampsia. *Am. J. Obstet. Gynecol.* 1985; 152: 25-31.