

# CYCLOOXYGENASE-2 EXPRESSION DETERMINES NEOANGIOGENESIS IN GALLBLADDER CARCINOMAS

MATEJA LEGAN<sup>1\*</sup>, BOŠTJAN LUZAR<sup>2</sup>,  
VERA FERLAN-MAROLT<sup>2</sup>, ANDREJ CÖR<sup>1</sup>

1. Institute of Histology and Embryology, Faculty of Medicine,  
University of Ljubljana, Korytkova 2, 1000 Ljubljana, Slovenia
2. Institute of Pathology, Faculty of Medicine,  
University of Ljubljana, Korytkova 2, 1000 Ljubljana, Slovenia

\* Corresponding author

## ABBREVIATIONS:

COX-2: cyclooxygenase-2; MVD: microvessel density

VEGF: vascular endothelial growth factor; IRS: immunoreactive score

## ABSTRACT

Neoangiogenesis may have an important role in the poor prognosis of gallbladder carcinoma. An enhanced expression of COX-2 was found in precancerous lesions and in gallbladder carcinoma, likely to be involved in carcinogenesis as well as in angiogenesis. To study the relationships between the COX-2 expression and degree of vascularization, as well as to evaluate their role in the prognosis of patients with gallbladder carcinoma, 27 cases of gallbladder adenocarcinoma were included, classified grading I-III according to the WHO classification. The COX-2 and endothelial antigen CD105 expressions were assessed immunohistochemically. COX-2 expression was evaluated according to the percentage and staining intensity of positive cells into "COX-2 positive" and "COX-2 negative" groups. In order to assess tumor microvessel density (MVD), CD105 positively stained microvessels were counted for each specimen in predominantly vascular areas (hot spots) at 200x magnification. The MVD ranged from 9 to 46 microvessels/field. 15 tumors belonged to the hypervascular group (MVD  $\geq$  25) and 12 to the hypovascular group. There were 16 (59,2%) COX-2 positive cases. There was difference in the degree of angiogenesis between COX-2 positive vs. COX-2 negative group: 11 (68,8%) out of 16 "COX-2 positive" tumors were hypervascular, in comparison with just 4 (36,4%) of "COX-2 negative" tumors. Our data show that the MVD corresponds to the COX-2 overexpression in gallbladder carcinomas. Augmented tumor neovascularization induced by COX-2 might be responsible for the poor prognosis in gallbladder carcinoma patients.

KEY WORDS: gallbladder carcinoma, cyclooxygenase, tumor angiogenesis, endoglin, intratumoral microvessel density

## INTRODUCTION

Carcinoma of the gallbladder is an aggressive tumor with an overall 5-year survival rate of less than 5%. Activation of the angiogenic pathways in malignant tumors is common and, by inducing new blood vessel formation, may have a decisive role in determining local invasion, metastasis and clinical outcome (1, 2). CD105 (endoglin) is a new endothelial cell marker, to visualize neovasculature and to count the intratumor microvessel density (MVD). CD105 is only weakly expressed in normal tissues, but strongly in tumor endothelia (3, 4). It is superior to other panendothelial markers because it distinguishes between newborn tumor vessels and preexisting parenteral vessels, detecting only tumor neoangiogenesis (3, 4). Expression of the COX-2 enzyme is responsible for enhanced tumor growth and angiogenesis in various tumours (5-7), having the role both in early carcinogenesis as well as in angiogenesis. The role of COX-2 in the process of carcinogenesis has been dramatically emphasized by confirmation that non-steroidal antiinflammatory drugs decrease the number of colonic polypes in humans with adenomatous polyposis and lower the incidence of colorectal cancer (8). Data on gallbladder carcinoma biology are scarce (2, 9, 10). Enhanced expression of cyclooxygenase-2 (COX-2) was found in precancerous lesions and in gallbladder carcinoma (11). The aim of our recent study was to investigate the relationships between the expression of COX-2 and angiogenesis in gallbladder carcinoma as well as to evaluate their role in the prognosis of patients with gallbladder carcinoma.

## MATERIALS AND METHODS

We performed a retrospective study of 27 gallbladder adenocarcinoma tissue specimens obtained from patients operatively treated between 1998 and 2000 (Table 1).

## IMMUNOHISTOCHEMISTRY

COX-2 and CD105 expressions were investigated by immunohistochemistry. Formalin-fixed, paraffin-embedded specimens were sectioned in series at a thickness of 5 µm. After deparafinisation, the slides were immersed for 30 min in 0,3% hydrogen peroxide/methanol to deplete endogenous peroxidase. Antigen retrieval was achieved using the pressure-cooking method for 4 min in a citrate buffer (pH= 6,0). For COX-2 expression, polyclonal anti-human COX-2 antibody (Cayman Chemicals, Ann Arbor, MI) was used in a dilution 1:500. For CD105 expression, the monoclonal mouse anti-human CD105 antibody (Novocastra Neomarkers, United Kingdom) in a dilution 1:100 was used. After the primary antibody incubation, the specimens were treated with a biotinylated secondary antibody for 30 min. Antigen visualisation was achieved by applying a standard streptavidin-biotin complex (ABC, DAKO, Denmark) for 30 minutes, followed by diaminobenzidin chromogen (DAB, Sigma Chemical CO, Germany) in 0,1% H<sub>2</sub>O<sub>2</sub> PBS solution. The specimens were counterstained with haematoxylin. The specificity of the applied antibodies was checked with positive or negative controls.

## VESSEL ENUMERATION

All sections were stained immunohistochemically with CD105 and were examined using a Nikon Eclipse E400 microscope. The slide was searched for the hot spots rich in vessels, located in the area of tumor tissue under a low power microscope. Images were captured using a Nikon digital camera and analysed with LUCIA measurement software package. MVD was counted under a 200x magnification, according to the standards that any stained endothelial cell or cells were identified as an independent vessel. These vessels have to be clearly separated from each other. Ten different vision fields were chosen on each tu-

N°. of patients	27
AGE: MEAN (± SD) (YEARS)	66,5 (±11,0)
Median (years)	70
Range (years)	44-82
SEX	
Male	16
female	11
GRADE	
I (well-differentiated)	8
II (moderately-differentiated)	4
III (poorly-differentiated)	15

TABLE 1. Patients and disease characteristics

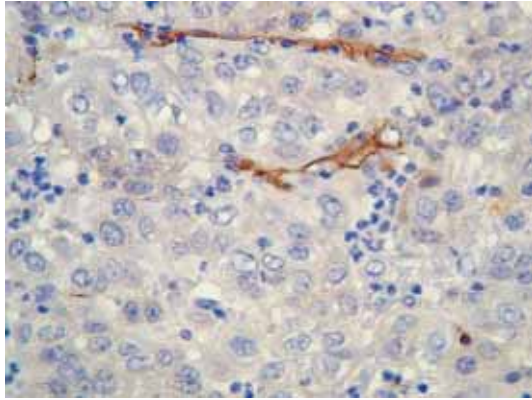


FIGURE 1. CD105 expression in a gallbladder carcinoma: a case of hypovascular tumor (Mx630)

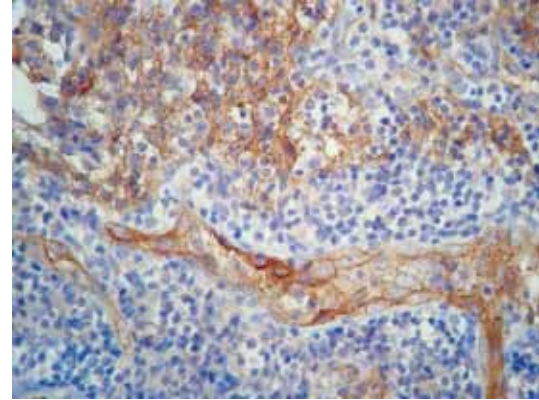


FIGURE 2. CD105 expression in a gallbladder carcinoma: a case of hypervascular tumor (Mx400)

our sample, and the stained vessels were counted by two observers separately. The results were averaged, the value was the amount of vessels per unit area.

#### COX-2 ANALYSIS

Immunostaining was independently evaluated by two investigators (AC and ML) and a consensus agreement was achieved. COX-2 was evaluated according to the percentage (0 to 4 degree; 0: 0%, 1: <10%, 2: 10-50%, 3: 51-80%, 4: >80%) and staining intensity (0-3; 0: negative, 1: weak, 2: moderate, 3: strong) of positive cells. For the immunoreactive score (IRS), the percentage of positive cells and staining intensity were multiplied, resulting in a value between 0 and 12. We united samples with an IRS of 0 to 6 into the group with negative to weak COX-2 expression (the COX-2 negative group) and those with an IRS 7-12 (the COX-2 positive group).

#### RESULTS

The positive expression of CD105 was presented as brownish granules in a cytoplasm of vascular endothelial cells. The microvessels were heterogeneously distributed in malignant tissues. In our gallbladder carcinoma tumors, MVD ranged from 9 to 46 microvessels per 200x optical field. The mean MVD was  $25 \pm 9$  (mean  $\pm$  SD). We classified tumors into hypovascular (MVD < 25) and hypervascular group (MVD  $\geq$  25): 12 tumors belonged to the hypovascular (Figure 1) and 15 to the hypervascular group (Figure 2). COX-2 was located as brownish-yellow stained granules in a cytoplasm of tumor cells (Figure 3). There were 16 (59,2%) COX-2 positive and 11 (40,8%) COX-2 negative cases. The expression rate of high MVD in 16 cases of "COX-2 positive" gallbladder carcinoma was 11 (68,8%) in com-

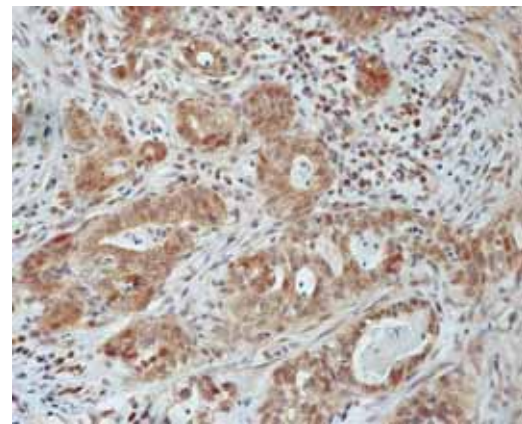


FIGURE 3. COX-2 expression in a gallbladder carcinoma (Mx400)

parison with only 4 (36,4%) out of 11 "COX-2 negative" cases (Graph 1). Tumor grading was observed in hypovascular vs. hypervascular group of tumors (Graph 2): tumor grade was insignificantly higher (Table 2) in hypervascular group (11 out of 15 poorly differentiated tumors had high MVD whereas the majority of grade I tumors were hypovascular). A correlation was observed between the COX-2 expression and tumor grade: 10 out of 15 poorly differentiated (grade III) gallbladder carcinomas were COX-2 positive (Graph 3); however, the statistical difference in COX-2 expression regarding tumor grading was non-significant ( $p=0,17$ ). The COX-2 expression as well as MVD did not correlate with age or gender. The mean survival time in our patients was  $11 \pm 19$  months (it differed in patients with hypovascular vs. hypervascular tumor, Table 3). Only 1 patient is still alive, 2 patients dropped out of medical control (alive?). These 3 patients tumors belonged to the hypovascular group.

|G

## DISCUSSION

Angiogenesis, the formation of new blood vessels within and adjacent to a tumor, is essential for tumor growth by providing nutrients and eliminating metabolic waste products. The quantity of microvessels identified by anti-CD105 monoclonal antibodies is nowadays an ideal instrument to quantify new microvessels in tumors; being specific to angiogenic tissues and as such superior to panendothelial markers such as CD34, CD31, F8 etc. (12, 13). CD105 is a proliferation-associated endothelial marker, a new kind of adhesion molecule, a receptor that is strongly up-regulated in proliferating endothelial cells (also in tumor neovasculture) (2, 3). Immunohistochemical staining for CD105 is very selective for the blood vessel endothelium and reacts specifically with endothelial cells without significant cross-reactivity of inflammatory or stromal cells within the neoplasm (2, 3). The extent of angiogenesis varied considerably in our gallbladder carcinomas. Dividing tumors into hypovascular and hypervascular groups showed that the grade III carcinoma were commonly hypervascular, whereas grade I carcinoma usually belonged to the hypovascular group ( $p=0,08$ , Table 2). Our results confirm the hypothesis that COX-2 plays an important role in tumor angiogenesis. COX-2 is an isoform of enzyme cyclooxygenase (COX), a prostaglandin (PG) synthase that catalyzes rate limiting steps in the production of PG and thromboxanes. Since another isoform COX-1 is constitutively expressed in most mammalian tissues and responsible for normal kidney and platelet function and for the maintenance of gastrointestinal mucosa, COX-2 is not detected in most normal tissues (14). It is induced by mitogenic and inflammatory stimuli, which results in the enhanced synthesis of PGs in neoplastic and inflamed tissues (15). COX-2 is overexpressed in several premalignant and malignant conditions (14), in many gastrointestinal tumors, including gallbladder carcinoma (16, 11). There are many COX-2 signalling pathways

that promote tumorigenesis. Our opinion is that probably the most important role of COX-2 in tumorigenicity is enhancing angiogenesis of the tumor (17). COX-2 (induced by hypoxia) appears to play a key role in the release of proangiogenic proteins, such as prostaglandin E<sub>2</sub>, basic fibroblast growth factor, nitric oxide and VEGF, thus stimulating endothelial cell migration and angiogenesis in vivo (16). Our results show a tendency that high COX-2 expression in gallbladder carcinomas is related to hypervascularity of the tumor. On the other hand, hypovascular tumors were more likely to be COX-2 negative. Our finding is in accordance with the study of Zhi et al. (18), who found MVD and VEGF positive rate in the COX-2 positive gallbladder carcinoma tissue higher than that in the COX-2 negative tissues. We believe that the finding of possible positive association between COX-2 and angiogenesis, also in gallbladder carcinomas, is very important since therapeutic targeting of COX-2 with COX-2 selective inhibitors is a possible future direction for fighting not only in early carcinogenesis (8), but also tumor angiogenesis (19). Gallbladder carcinoma is by now a tumor with a weak prognosis, dependent mostly on surgical treatment, with no relevant guides for the use of additional pharmaceutical therapy. Angiogenesis has been proposed as a prognostic marker in a variety of human neoplasms, including gastrointestinal (20, 21). Only a few studies investigated the clinical implications of tumor neoangiogenesis in gallbladder carcinomas (7, 9, 10). Some studies reported MVD as an independent prognostic factor for gallbladder carcinomas (10), others failed to find such a correlation (9). Our results suggest that neovascularization may reflect the malignant potential of gallbladder tumors since hypervascular tumours predicted a (insignificantly) shorter survival time. However, we are aware that our study lacks other parameters for prognosis such as the general condition of the patient, lymph node involvement, presence of the metastasis at the operation.

## CONCLUSION

Our study presented on a small group of patients with gallbladder carcinomas shows a clear association between COX-2 overexpression and neovascularization. Augmented tumor blood vessels induced by COX-2 might be responsible for the poor prognosis of human gallbladder carcinomas.

## REFERENCES

- (1) Weidner N. The importance of tumor angiogenesis: the evidence continues to grow. *Am. J. Clin. Pathol.* 2004; 122: 675-677.
- (2) Giatromanolaki A., Sivridis E., Koukourakis M.I., Polychronidis A., Simopoulos C. Prognostic role of angiogenesis in operable carcinoma of gallbladder. *Am. J. Clin. Oncol.* 2002; 25: 38-41.
- (3) Fonsatti E., Sigalotti L., Arslan P., Altomonte M., Maio M. Emerging role of endoglin (CD105) as a marker of angiogenesis with clinical potential in human malignancies. *Curr. Cancer Drug Targets* 2003; 3: 427-432.
- (4) Fonsatti E., Maio M. Highlights on endoglin (CD105): from basic findings towards clinical applications in human cancer. *J. Transl. Med.* 2004; 2: 18.
- (5) O'Grady A., O'Kelly P., Murphy G.M., Leader M., Kay E. COX-2 expression correlates with microvessel density in non-melanoma skin cancer from renal transplant recipients and immunocompetent individuals. *Hum. Pathol.* 2004; 35: 1549-1555.
- (6) Gallo O., Masini E., Bianchi B., Bruschini L., Paglierani M., Franchi A. Prognostic significance of cyclooxygenase-2 pathway and angiogenesis in head and neck squamous cell carcinoma. *Hum. Pathol.* 2002; 33: 708-714.
- (7) Hemmerlein B., Galuschka L., Putzer N., Zischkau S., Heuser M. Comparative analysis of COX-2, vascular endothelial growth factor and microvessel density in human renal cell carcinoma. *Histopathol.* 2004; 45: 603-611.
- (8) Steinbach G., Lynch P.M., Phillips R.K., et al. The effect of celecoxib, a cyclooxygenase-2 inhibitor, in familial adenomatous polyposis. *N. Engl. J. Med.* 2000; 342: 1946-1952.
- (9) Sugawara Y., Makuuchi M., Harihara Y., et al. Tumor angiogenesis in gallbladder carcinoma. *Hepato-Gastroenterol.* 1999; 46: 1882-1886.
- (10) Shirabe K., Shimada M., Tsujita E., et al. Prognostic factors in node-negative intrahepatic cholangiocarcinoma with special reference to angiogenesis. *Am. J. Surg.* 2004; 187: 538-542.
- (11) Legan M., Luzar B., Ferlan-Marolt V., Cör A. Expression of cyclooxygenase-2 is associated with p53 accumulation in premalignant and malignant gallbladder lesions. *World J. Gastroenterol.* 2006; 21: 3425-3429.
- (12) Tanaka F., Otake Y., Yanagihara K., et al. Evaluation of angiogenesis in non-small cell lung cancer: comparison between anti CD-34 antibody and anti-CD105 antibody. *Clin. Cancer Res.* 2001; 7: 3410-3415.
- (13) Middleton J., Americh L., Gayon R., et al. A comparative study of endothelial cell markers expressed in chronically inflamed human tissues: MECA-79, Duffy antigen receptor for chemokines, von Willebrand factor, CD31, CD34, CD105 and CD146. *J. Pathol.* 2005; 206: 260-268.
- (14) Gately S. The contribution of cyclooxygenase-2 to tumor angiogenesis. *Cancer Metastasis Rev.* 2000; 19: 19-27.
- (15) Subbaramaiah K., Danenberg A.J. Cyclooxygenase-2: a molecular target for cancer prevention and treatment. *Trends Pharmacol. Sci.* 2003; 24: 96-102.
- (16) Eberhart C.E., Coffey R.J., Radhika A., Gardiell F.M., Ferrenbach S., DuBois R.N. Up-regulation of cyclooxygenase-2 gene expression in colorectal adenomas and adenocarcinomas. *Gastroenterol* 1994; 107: 1183-1188.
- (17) Rao M., Yang W., Seifalian A.M., Winslet M.C. Role of cyclooxygenase-2 in the angiogenesis of colorectal cancer. *Int. J. Colorect Dis.* 2004; 19: 1-11.
- (18) Zhi Y.H., Liu R.S., Song M.M., et al. Cyclooxygenase-2 promotes angiogenesis by increasing vascular endothelial growth factor and predicts prognosis in gallbladder carcinoma. *World J. Gastroenterol.* 2005; 11: 3724-3728.
- (19) von Rahden B.H.A., Stein H.J., Puhlinger F., et al. Coexpression of cyclooxygenase (COX-1, COX-2) and vascular endothelial growth factors (VEGF-A, VEGF-C) in esophageal adenocarcinoma. *Cancer Res.* 2005; 65: 5038-5044.
- (20) Leahy K.M., Ornberg R.L., Wang Y., Zweifel B.S., Koki A.T., Masferrer J.L. Cyclooxygenase-2 inhibition by celecoxib reduces proliferation and induces apoptosis in angiogenic endothelial cells in vivo. *Cancer Res.* 2002; 62: 625-631.
- (21) Ho J.W., Poon R.T., Sun C.K., et al. Clinicopathological and prognostic implications of endoglin (CD105) expression in hepatocellular carcinoma and its adjacent non-tumorous liver. *World J. Gastroenterol.* 2005; 11: 176-181.