



# TESTICULAR METASTASIS OF GASTROINTESTINAL STROMAL TUMOR OF THE JEJUNUM

MIRSAD DORIĆ\*, SVJETLANA RADOVIĆ, MIRSAD BABIĆ,  
AJNA HUKIĆ, SUADA KUSKUNOVIĆ, IVANA TOMIĆ, IVAN SELAK

Institute of Pathology, Faculty of Medicine, University of Sarajevo,  
Čekaluša 90, 71000 Sarajevo, Bosnia and Herzegovina

\* Corresponding author

## ABSTRACT

Gastrointestinal stromal tumors (GIST) are neoplasm of mesenchymal origin that usually begins in cells of the wall of the gastrointestinal tract. It can be benign or malignant. In this report, we have presented a case of malignant GIST with uncommon site of metastasis. This is of interest because of three reasons. Firstly, metastases to the testis are extremely rare. However, metastases to distally localized organs are not commonly associated with GIST, and finally, to our knowledge this is the first case of malignant GIST metastasis to the testis reported in the world.

KEY WORDS: gastrointestinal stromal tumor, metastasis, testis

## INTRODUCTION

Gastrointestinal stromal tumors (GIST) are mesenchymal tumors which typically arise in association with the muscularis propria of gastrointestinal (GI) tract wall (1). They are defined as c-kit protein (CD 117, stem cell factor receptor)-positive mesenchymal spindle cell or epithelioid neoplasm in gastrointestinal (GI) tract, omentum and mesentery (2). GIST are most frequent in the stomach (60%), but also can occur in the small bowel (30%) or elsewhere, including the colon and rectum (5%), esophagus (<5%) (3). In addition, they may occur as a primary tumor of the omentum, mesentery or retroperitoneum (4). The majority of GIST is not malignant. The malignancy of the tumor is determined by the mitotic rate, size, and invasiveness (3). After complete resection, the rate of recurrence is high, but distant metastasis is rare. The usual sites of metastasis are the liver and peritoneum. Other sites include retroperitoneum, pleura, lungs, bone, and subcutaneous tissue in relation to a laparotomy scar or without it (5). Intracranial metastasis were also described (6,7,8).

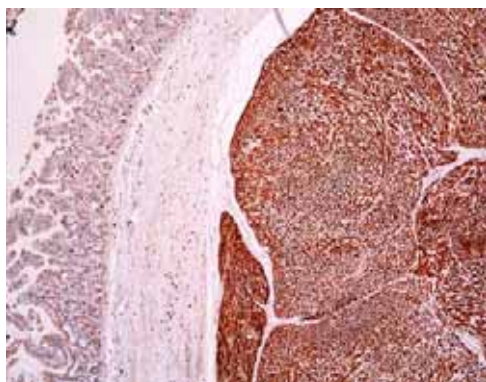


FIGURE 1. The strong positive immunohistochemical staining for CD117 of tumor cells with negative staining of the adjacent structure, x 40

A 56-year-old white male who was performed the small intestine resection in extent of approximately 1 m length, upon strong and persistent intraabdominal pain was found to have a mesenchymal tumor of the jejunum. Grossly, the middle part of resected intestine a lumen was globularly expanded (16x16 cm) and wall was thickened up to 2 cm, diffusely penetrated with grey white tumor mass. Pathologic examination revealed a spindle cell tumor with 11 mitotic figures per 10 high-powered fields, which stained positive for CD 117 (figure 1) vimentin and CD34, moderate expression of muscle actine HHF-35, focal positivity to S 100 protein, while being negative for smooth muscle actine and desmin. The patient was disease-free for seven month, when enlargement and pain sensations appeared in the right testicle. After clinical and radiological investigation an orchidectomy was performed. Macroscopically, the tissue specimen measured 13x6x4 cm, with four ovoid nodules on the cut surface between visceral and parietal sheet of tunica vaginalis testis. The small-

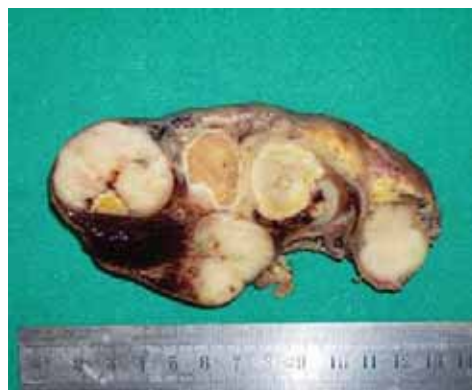

FIGURE 2. Cut surface: tumor nodules comprime but do not invade testicle parenchima leading to its atrophy

est nodule measured 22 mm and the largest 35 mm of longer diameter, grey whitish color, appearance of fish meat, with areas of necrosis and bleeding that pressured the testicle up to the size of 22 mm (figure 2). Histologically, the tumor nodules were metastatic tissue of gastrointestinal stromal tumor (figure 3) with identical immunoprofile as described in previous biopsy specimen (figure 4). The advanced atrophy is seen in testicular tissue.

## DISCUSSION

Metastases to the testis are extremely rare. After extensive literature review Kulkarni et al. (2004), found that only some 200 cases have been reported worldwide (9). Amongst these, the commonest ones are metastatic carcinoma of the prostate (34, 6 %) lung (17, 3 %), malignant melanoma (8, 2 %) colon (7, 7 %), and kidney (5, 8 %). In single cases the organs of origin of the carcinoma were stomach, pancreas, penis, bladder, rectum, thyroid, urether, bile duct and

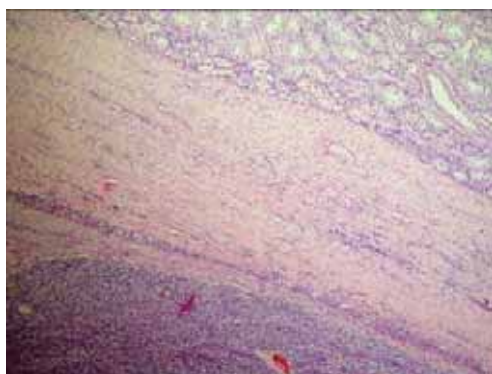


FIGURE 3 Tunica albuginea testis separated tumor tissue and atrophic testicular parenchym, HE, x 40

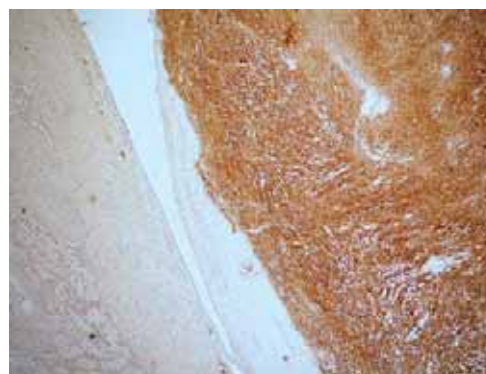

FIGURE 4. CD117 positive tumor tissue on the adjacent testicular parenchym structure, x 40

liver (10). To our knowledge, the small bowel as original tumor-bearing organ has not yet been reported. GIST is mesenchymal lesion originating from the gastrointestinal tract anywhere from the oesophagus to the rectum (2, 3). The origin of GIST appears to be the Cajal cells, which are gastrointestinal pacemaker cells that have both smooth muscle and neural features. GIST, which usually appear as solitary lesions, are highly specific for their sites of origin and different subtypes arise from different region (11). The median age for developing this tumor is between the fifth and sixth decades of life and there is no gender predilection (12). The presenting symptoms of patients with GIST are based on the tumor site and size (3). About 70 % of patients with GIST present with vague upper abdominal pain. Gastrointestinal bleeding and obstructive symptoms are other common signs (13). GIST originate from the muscularis layer of the viscus and are composed of a spindle (70 %) or epithelioid (30 %) cells (14), although some examples display a mixture of two cell types. Pathologically, the most specific indicator of GIST is the expression of the c-kit (CD 117) antigen (3). This is transmembrane receptor with tyrosine kinase component that is present in nearly 94 % of these tumors. Mutation of c-kit have been shown to be associated with malignancy (14). Vimentin is also present in all GIST (13). Another transmembrane protein that is seen in 50-70 % of GIST is CD 34 (15). Actin is detected in 20-40 % while these tumors are generally negative for the S-100 protein and desmin (11). Other spindle cell tumor such as leiomyomas and leiomyosarcomas lack c-kit mutation (16). As above, leiomyoma occur most frequently in the oesophagus as

intramural lesion. True leiomyosarcomas, sarcomas displaying smooth muscle differentiation, are very rare gastrointestinal tract tumors, in contrast to malignant GIST. Schwannomas are also distinct from GIST, and are always benign S-100 positive spindle cell tumors usually found in the stomach. Gastrointestinal autonomic nerve tumors (GANTs) are probably a subset of GIST (17). The majority of GIST are benign with a malignancy rate of 10-30 %. GIST malignant behavior is best assessed by the invasion of adjacent structures and distant metastasis (3). Tumor location is a key factor in predicting outcome. For example, most (about 70 %) gastric GIST behave in a benign fashion, whereas about half of duodenal GIST metastasize (18, 19). Location is a key prognostic factor in these tumors (20). Other signs of malignancy include large size (>6 cm), hemorrhage, necrosis and presence of peritoneal metastasis (3). Pathologically, high mitotic rates (>5 per 10 high-powered fields), high cellularity, paucity of stroma and c-kit mutation also indicate malignancy (11). GIST are capable of metastasizing to visceral organs, even though this is a rare occurrence. In series of 200 patients with malignant GIST at Memorial Sloan-Kettering, 61 % of metastases were found in the liver, 20 % had peritoneal seeding and 6 % showed bony involvement (15). In this report, we have presented a case of malignant GIST with uncommon site of metastasis. This is of interest because of three reasons. Firstly, metastases to the testis are extremely rare. However, metastases to distally localized organs are not commonly associated with GIST, and finally, to our knowledge this is the first case of malignant GIST metastasis to the testis reported in the world.

## REFERENCES

- (1) Mazur M.T., Clarc H.B. Gastric stromal tumors: reappraisal of histogenesis. *Am.J.Surg.Pathol.* 1983; 7:507-519.
- (2) Miettinen M., Sobin L.H., Sarlomo-Rikala M. Immunohistochemical spectrum of GIST at different sites and their differential diagnosis with a reference to CD 117 (kit). *Mod. Pathol.* 2000; 13: 1134-42.
- (3) Miettinen M., Sarlomo-Rikala M., Lasota J. Gastrointestinal stromal tumors: Recent advances in understanding of their biology. *Hum.Pathol.* 1999; 30: 1213-1220.
- (4) Miettinen M., Monihan J.M., Sarlomo-Rikala M. et al. Gastrointestinal stromal tumors/smooth muscle tumors (GIST) primary in omentum and mesentery: clinicopathologic and immunohistochemical study of 26 cases. *Am.J.Surg.Pathol.* 1999; 23: 1109-1118.
- (5) Shabahang M., Livingstone A.S. Cutaneous metastases from a gastrointestinal stromal tumor of the stomach: review of literature. *Digestive Surgery* 2002; 19:64-65.
- (6) Akiyama K., Numaga J., Kagaya F., Takazawa Y., Suzuki S., Koseki N., Kato S., Kaburaki T., Kawashima H. Case of optic nerve involvement in metastasis of a gastrointestinal stromal tumour. *Jpn J Ophthalmol.* 2004; 48:166-168.
- (7) Hughes B., Yip D., Goldstein D., Waring P., Beshay V., Chong G. Cerebral relapse of metastatic gastrointestinal stromal tumour during treatment with imatinib mesylate: case report. *BMC Cancer.* 2004; 4:74. doi: 10.1186/1471-2407-4-74.
- (8) Brooks B.J., Bani J.C., Fletcher C.D., Demetri G.D. Challenges in oncology. Case 4. Response of metastatic gastrointestinal stromal tumour including CNS involvement to imatinib mesylate (STI-571). *J Clin Oncol.* 2002; 20:870-872.
- (9) Kulkarni S., Coup A., Kershaw J.B., Buchholz P.N. Metastatic appendiceal adenocarcinoma presentig late as epididimo-orchitis: a case reporting and review of literature. *BMC Urology.* 2004; 4:1 doi:10.1186/1471-2490-4-1
- (10) Patel S.R., Richardson R.L., Kvols L. Metastatic cancer to the testes: a report of 20 cases and review of the literature. *J.Urol.* 1989; 142: 1003-1005.
- (11) Boggino H.E., Fernandez M.P., Logrono R. Cytomorphology of gastrointestinal stromal tumor: Diagnostic role of aspiration cytology, core biopsy and immunohistochemistry. *Diagn. Cytopathol.* 2000; 23: 156-160.
- (12) Ruiz A.R., Nassar A.J., Fromm H. Multiple malignant gastric stromal tumors presenting with GI bleeding: A case report and review of the literature. *Gastrointest. Endosc.* 2000; 51: 1-5.
- (13) Zhao H., Li H., Wang S. The clinicopathological and immunophenotypical fetures of 162 cases of gastrointestinal stromal tumor. *Chung Hua Chung Liu Tsa Chih.* 1998; 20: 313-315.
- (14) Pidhorecky I., Cheney R.T., Kraybill W.G., Gibbs J.F. Gastrointestinal stromal tumors: Current diagnosis, biologic behavior and menagment. *Ann.Surg.Oncol.* 2000; 7: 705-712.
- (15) De Matteo R.P., Lewis J.J., Leung D., Muda S.S., Woodruff J.M., Brennan M.F. Two hundred gastrointestinal stromal tumors: Recurrence patterns and prognostic factors for survival. *Ann. Surg.* 2000; 231:51-58.
- (16) Lasota J., Jasinski M., Sarlomo-Rikala M., Miettinen M. Mutations in axon 11 of c-kit occur preferentilly in malignant versus benign gastrointestinal stromal tumor and not occur in leiomyomas or leiomyosarcomas. *Am.J. Pathol.*1999; 154: 53-60.
- (17) Miettinen M., Lasota J. Gastrintestinal stromal tumors: definition, clinical, histological, immunohistochemical and molecular genetic features and differential diagnosis. *Virchows Arch.* 2001; 438: 1-12.
- (18) Goldblum J., Appelman H. Stromal tumors of the duodenum: histologic and immunohistochemical study of 20 cases. *Am.J.Surg. Pathol.* 1995; 19: 71-80.
- (19) Brainard J., Goldblum J. Stromal Tumors of the Jejunum and Ileum : A Clinicopathologic Study of 39 Cases. *Am.J.Surg.Pathol.* 1997 ; 21 : 407-416.
- (20) Emory T.S., Sobin L.H., Lukes L., Lee D., O'Leary T.J. Prognosis of gastrointestinal smooth-muscle (stromal) tumors: dependence on anatomic site. *Am.J.Surg.Pathol.* 1999; 23 : 82-87.