

# Verruca vulgaris of the tongue: a case report with literature review

Ahmet Ural<sup>1\*</sup>, Selçuk Arslan<sup>1</sup>, Şafak Ersöz<sup>2</sup>, Betül Değer<sup>1</sup>

<sup>1</sup>Department of Otorhinolaryngology, Karadeniz Technical University School of Medicine, Trabzon, Turkey. <sup>2</sup>Department of Pathology, Karadeniz Technical University School of Medicine, Trabzon, Turkey.

## ABSTRACT

Verruca vulgaris (common warts) is a benign lesion of skin and mucous membranes caused by human papillomavirus (HPV). The lesions are typically self-limited but may vary in size and number. The occurrence on the tongue is extremely rare. To the best of our knowledge, only one verruca vulgaris existing in the tongue had been reported in the literature. Case presentation: A rare case of verruca vulgaris of the tongue occurring in a 36-year-old Caucasian male is presented with a discussion on etiopathogenesis and the treatment methods. Verruca vulgaris must be remembered in the differential diagnosis of tongue lesions and surgical treatment may provide satisfactory outcomes.

KEY WORDS: verruca vulgaris, tongue, human papillomavirus

*Bosn J Basic Med Sci. 2014;14(3):136-138. © 2014 ABMSFBH*

## INTRODUCTION

Verruca vulgaris (VV) is a frequent skin disease caused by human papillomavirus (HPV) infection [1]. It is also known as common warts and the lesion tends to affect epithelial tissues and mucous membranes. Verruca vulgaris is a benign epidermal proliferation with infrequent malignant change [2]. The clinical presentations of verruca vulgaris vary according to the viral type and the anatomical site infected. The benign VV include squamous papilloma with verruca vulgaris, focal epithelial hyperplasia and condyloma [1]. Verruca vulgaris is most commonly induced by HPV-2, HPV-4 or HPV-40 and it rarely occurs on the tongue.

As a contagious disorder, it could be transmitted to other areas of body if left unattended. Compared to the commonly affected sites, such as hands, feet or face, the verruca involving the tongue has rarely been reported in the English literature. Several treatments including surgery, cryotherapy, electrocauterization, laser or topical agents all focus on eradicating the lesions; however, the treatment strategy can vary depending on the disease location, severity, and the patient's immune status [2].

In this case report, a rare case of verruca vulgaris on the tongue is presented along with a brief review of literature.

## CASE PRESENTATION

A 36-year-old male was admitted to the outpatient clinic of the otolaryngology department of our tertiary care center. He had been complaining of a painless, exophytic, sessile mass of 3 × 3 cm on the dorsal surface of the tongue (Figure 1). The patient did not have any verrucas elsewhere in the body. Under local anesthesia, the lesion was excised totally using needle-tip electrocautery with preservation of safe surgical margins. Diagnosis of verruca vulgaris was confirmed by pathological investigation (Figure 2) and polymerase chain reaction analysis which revealed HPV-4 DNA. No recurrences or complications had been noted in the observed on follow-up period of 6 months.

## DISCUSSION

Verruca vulgaris (benign cutaneous wart) is a common dermatose of viral origin affecting 7% to 10% of the general population with a peak incidence between the ages of 12 and 16 years [3]. They can affect the patient's quality of life causing discomfort, embarrassment and fear of negative appraisal in the society. The lesions are caused by human papillomavirus (HPV) invading epithelial cells with consequent cell proliferation and nodule/plaque formation. They usually occur in wet and macerated skin areas of the body that touch rough surfaces [4]. The lesions

\* Corresponding author: Ahmet Ural,  
Department of Otorhinolaryngology, Karadeniz Technical University  
School of Medicine, 61080 Trabzon TURKEY  
Tel: 00904623775884  
Fax: 00904623250518  
E-mail: ahmetural2001@yahoo.com

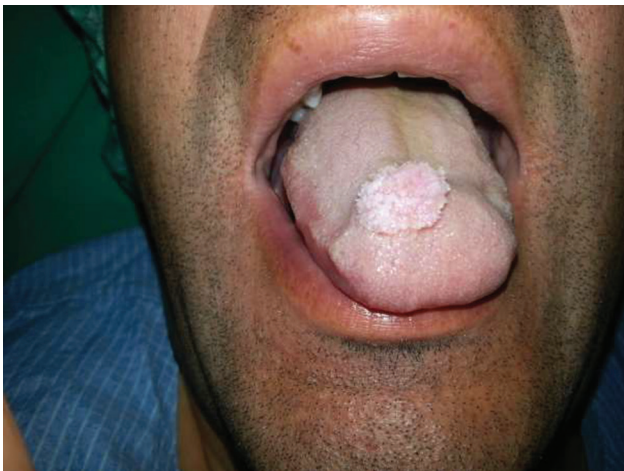

FIGURE 1. White verrucous lesion on the right side of the tongue

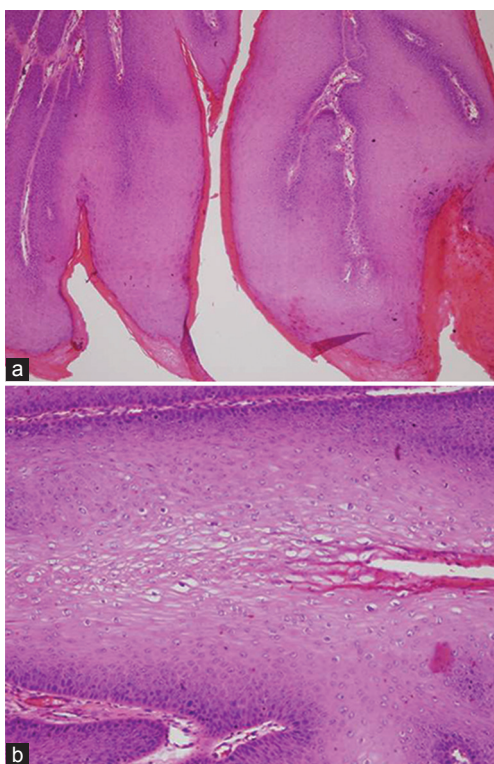


FIGURE 2. Histopathologic characteristics of the lesion. (a) Polypoid mass with an epithelium displaying acanthosis, parakeratosis and papillomatosis. (b) Superficial layers of the epithelium demonstrate koilocytotic changes

are usually located on hands, fingers, knees and elbows but can be found on any other site of body. The minor abrasions in the macerated skin are the sites of entry of HPV to basal keratinocytes of the epithelium. The warts can be transmitted by direct or indirect contact and once the skin is infected autoinoculation to secondary sites can occur by scratching, shaving or traumatizing the skin [5]. A strong immune response is not created by the viral agent and the lesion is self-limited allowing a silent growth for months or even years. Warts can resolve spontaneously depending on the host immune status and the type of the virus. Approximately 23% of the lesions show spontaneous

regression in 2 months and 30% and 65% to 78% regress spontaneously within 3 months and 2 years respectively [4]. However, some lesions may grow in size and number, and even become increasingly resistant to treatment over time [6].

Human papillomavirus is a double-stranded DNA virus that causes common warts found on the skin and anogenital warts (condyloma acuminatum) located on the genitalia. Currently, more than 120 genotypically different forms of HPV have been identified according to DNA studies and type-specific antibodies against capsid antigens [7]. Verruca vulgaris (common warts) on the hands and feet are caused by HPV types 1, 2, 4, 27, 40 and 57. Types 6 and 11 are implicated in the etiology of anogenital warts, and types 16, 18, 31, 35, 45 are associated with cervix carcinoma [8]. Infection with multiple types is not uncommon and different HPV types can show synergistic effect to facilitate a concurrent infection with another type or act antagonistically to interfere with one another [9]. Certain types of HPV are epitheliotropic and invade cornified squamous epithelium while some other mucosotropic types show preference for uncornified mucous membranes.

The benign HPV-associated oral lesions, focal epithelial hyperplasia (Heck disease), oral squamous cell papilloma, oral verruca vulgaris (common wart) and oral condyloma acuminatum, are collectively referred to as oral warts. The majority of cases reported in the literature regarding to warts of the tongue and oral cavity include condyloma acuminatum caused by HPV types 6 and 11, 12 [10]. Oral condyloma acuminatum (venereal wart) is a sexually transmitted disease which is strongly associated with oro-genital sexual behavior. The incidence has increased considerably due to the changes in sexual behaviour and an increase in the practice of oral sex [11]. In contrast, oral verruca vulgaris lesions caused by HPV types 1, 2, 4, 7 as in the current case are rarer with one reported case of VV of the tongue [12]. The lesions are usually caused by autoinoculation from lesions on the fingers and hands mainly in the children [13]. In our case, no additional risk factors such as history of common shower use or presence of other foci of verrucous lesions could be detected.

Focal epithelial hyperplasia, oral squamous papilloma, oral lichen planus, oral leukoplakia, oral verrucous carcinoma and oral squamous carcinoma should be considered in the differential diagnosis of VV. Focal epithelial hyperplasia affects oral mucosa, lips, tongue, notably lower lip and more rarely the palate and it is strongly associated with HPV types 13 and 32 [13]. Oral squamous papilloma is related to HPV 6 and 11 and is seen in oral mucosa over soft palate, lingual, frenulum, lower lip and uvula among adults [13]. Oral lichen planus is found predominantly in females between the ages of 30 to 60 years. The lesions are generally bilateral and symmetrical, affects the oral mucosa, gingival, the dorsum of tongue and lipmucosa. HPV types 11 and 16 are commonly found in about 87% of patients [14]. HPV

types 6, 11 and 16 commonly cause oral leukoplakia, a premalignant lesion of oral mucosa seen as white patches or plaques [15].

Different treatment methods are available for VV at present, but none is proven to be universally effective. Topical agents like salicylic acid and cantharidi may have only moderate beneficial effect compared to placebo, though they had been used very commonly by the public even without prescriptions. These corrosive topical agents should not be used by patients themselves theoretically, because it is difficult for them to judge the depth of lesion and dermal condition, which may increase the possibility of tissue damage and unhealing [6]. Surgical excision is a widely practiced method of treatment. Success rates of 65% to 85% have been reported but scarring can be problematic on the sole of foot and face [9].

## CONCLUSION

In conclusion, verruca vulgaris is a rare pathology of tongue that can be treated effectively with surgical excision. Other possible foci must be carefully investigated for eradication of disease completely.

## CONSENT

Written consent has been obtained from the patient for publication of this case report.

## DECLARATION OF INTEREST

The authors declare no competing interests.

## ACKNOWLEDGEMENTS

No financial support was received for this paper.

## REFERENCES

- [1] Forman D, de Martel C, Lacey CJ, Soerjomataram I, Lortet-Tieulent J, Bruni L, et al. Global burden of human papillomavirus and related diseases. *Vaccine* 2012; 30 (Suppl 5): F12-23.
- [2] Bzhalava D, Guan P, Franceschi S, Dillner J, Clifford G. A systematic review of the prevalence of mucosal and cutaneous human papillomavirus types. *Virology* 2013; 445 (1-2): 224-231.
- [3] Clifton MM, Johnson SM, Roberson PK, Kincannon J, Horn TD. Immunotherapy for recalcitrant warts in children using intraleisional mumps or Candida antigens. *Pediatr Dermatol* 2003; 20 (3): 268-271.
- [4] Sterling JC, Handfield-Jones S, Hudson PM. British Association of Dermatologists. Guidelines for the management of cutaneous warts. *Br J Dermatol* 2001; 144 (1): 4-11.
- [5] Stulberg DL, Hutchinson AG. Molluscum contagiosum and warts. *Am Fam Physician* 2003; 67 (6):1233-1240.
- [6] Nucci V, Torchia D, Cappugi P. Condyloma acuminatum of the tongue treated with photodynamic therapy. *Clin Infect Dis* 2009; 48 (9): 1330-1332.
- [7] Harper DM, Franco EL, Wheeler CM, Moscicki AB, Romanowski B, Roteli-Martins CM, et al. Sustained efficacy up to 4.5 years of a bivalent L1 virus-like particle vaccine against human papillomavirus types 16 and 18: Follow-up from a randomised control trial. *Lancet* 2006; 367 (9518): 1247-1255.
- [8] Bosch FX, Lorincz A, Munoz N, Meijer CJ, Shah KV. The causal relation between human papillomavirus and cervical cancer. *J Clin Pathol* 2002; 55 (4): 244-265.
- [9] Lipke MM. An armamentarium of wart treatments. *Clin Med Res* 2006; 4 (4): 273-293.
- [10] Badaracco G, Venuti A, Di Lonardo A, Scambia G, Mozzetti S, Benedetti Panici P, et al. Concurrent HPV infection in oral and genital mucosa. *J Oral Pathol Med* 1998;27 (3):130-134.
- [11] Eversole LR, Laipis PJ, Merrell P, Choi E. Demonstration of human papillomavirus DNA in oral condyloma acuminatum. *J Oral Pathol* 1987; 16 (5): 266-272.
- [12] Nagaraj M. Verruca vulgaris of the tongue. *J Maxillofac Oral Surg.*2013; 12 (3): 329-332.
- [13] Castro TP, Bussoloti Filho I. Prevalence of human papillomavirus (HPV) in oral cavity and oropharynx. *Braz J Otorhinolaryngol* 2006; 72 (2): 272-282.
- [14] Bharti AH, Chotaliya K, Marfatia YS. An update on oral human papillomavirus infection. *Indian J Sex Transm Dis* 2013; 34 (2): 77-82.
- [15] Sand L, Jalouli J, Larsson PA, Hirsch JM. Human papilloma viruses in oral lesions. *Anticancer Res* 2000; 20 (2B): 1183-1188.