

Bronchioloalveolar differentiation in lung adenocarcinomas

Nevena Đukić^{1*}, Božana Babić², Živka Eri¹, Dragana Zec¹, Aleksandra Lovrenski¹, Violeta Kolarov¹

¹ Institute for Pulmonary Diseases of Vojvodina, Institutski put 4, 21204 Sremska Kamenica, Serbia. ² Clinical Center Banja Luka, Institute for Pathology, Dvanaest beba 1, 78000 Banja Luka, Bosnia and Herzegovina

ABSTRACT

The goals of the study were to determine what percentage of neoplasms with a bronchioloalveolar (BAC) component were considered pure BAC by current World Health Organization (WHO) criteria. Next, we wanted to determine the number of mucinous BACs using histochemical staining with Alcian Blue PAS. Finally, we aimed to elucidate by immunohistochemistry the thyroid transcription factor-1 (TTF-1) frequency and cytokeratin 7 (CK7) expression, particularly in regard to the mucinous and non-mucinous subtypes of BAC tumors. We made a retrospective review of Hematoxylin and Eosin stained slides and classification of histologic grade, tumor subtype, and percentage of pure BAC pattern, with further characterization by histochemical staining for Alcian Blue PAS and Immunohistochemical staining for thyroid TTF-1 and CK7. Only 10 of 30 tumors examined could be classified as BAC by current strict WHO criteria. Nine cases were classified into non-mucinous and only one case was recognized as mucinous BAC, which showed positive staining for Alcian Blue PAS. TTF-1 positivity was in 100% of the non-mucinous BACs and complete absence of staining was in one case of mucinous BACs. CK7 expression in bronchioloalveolar carcinoma has demonstrated CK7 marked staining in 90% of non-mucinous BACs, also one case of mucinous BACs showed marked staining for TTF-1. BACs of mucinous morphology were notable for their conspicuous absence of TTF-1 immunoreactivity.

© 2011 Association of Basic Medical Sciences of FBiH. All rights reserved

KEY WORDS: lung, adenocarcinoma, bronchioloalveolar carcinoma, alcian blue, immunohistochemistry

INTRODUCTION

Bronchioloalveolar carcinoma (BAC) is a previously uncommon subset of non-small cell lung cancer (NSCLC) with unique epidemiology, pathology, clinical features, radiographic presentation, and natural history compared with other NSCLC subtypes. In 2004, the World Health Organization (WHO) redefined BAC to include only those lesions with so-called pure lepidic (classic) growth pattern and no evidence of invasion by a tumor [1]. If stromal, vascular, or pleural invasion was seen, the neoplasm was classified as an adenocarcinoma, mixed type, with bronchioloalveolar features [1, 2]. Three types of BAC were also recognized, including non-mucinous, mucinous, and mixed type mucinous and non-mucinous. BAC is the only subtype of adenocarcinoma with substantially better prognosis than other forms of lung cancer [2]. Studies of BACs have shown that the prognosis is directly related to the size, percentage and pattern of scar tissue present in the lesion. The goals of this study were to

determine what percentage of neoplasms with a BAC component was considered pure BAC and to determine what numbers of BACs are mucinous by current WHO criteria.

MATERIALS AND METHODS

Samples

In our study 341 cases of adenocarcinomas were retrieved from the archives of the Department of Pathology at Institute for Pulmonary Disease of Vojvodina, Sremska Kamenica, Serbia. All cases were surgically resected (wedge biopsy, lobectomy, or pneumonectomy) between January 2001 and December 2006. Medical records were reviewed to verify that the cases were of primary lung origin and did not represent metastatic disease from primary tumor at other sites. All 341 microscopic Hematoxylin and Eosin stained slides containing adenocarcinoma were reviewed, and the diagnoses of BAC according to WHO criteria were confirmed in 34 cases. For Immunohistochemical and histochemical staining we formed two groups, one with 30 cases of adenocarcinoma without bronchioloalveolar component and 30 cases of adenocarcinomas with BAC component. In accordance with WHO definition of BAC 10 cases exhibited a purely lepidic growth pattern of cells along intact alveolar septa, with no evidence of stromal, vascular, or pleural invasion.

* Corresponding author: Nevena Đukić, Institute for Pulmonary Disease of Vojvodina, Clinic for tuberculosis and granulomatous diseases, Institutski put 4, 21204 Sremska Kamenica, Serbia
Phone: +381 21 480 5159; Fax: +381 21 527 960
E-mail: djukicnevena@yahoo.com

Submitted: 29 May 2011 / Accepted: 13 October 2011

TABLE 1. Presence of bronchioloalveolar component in lung adenocarcinoma versus degree of histochemical staining with Alcian Blue PAS.

Histology type	*Intensity	0	1	2	3
Adenocarcinomas With Bronchioloalveolar Component (n=30)		0	15	7	8
Adenocarcinomas Without Bronchioloalveolar Component (n=30)		29	0	0	1

*0= no staining, 1= mild staining, 2= moderate staining, 3= marked staining

Nine cases were classified into non-mucinous and only one case was recognized as mucinous BAC. A tumor was classified as mucinous if it contained a predominance of well-to moderately differentiated goblet or mucin-producing columnar tumor cells with clear, gray, or foamy material within its cytoplasm. These tumors showed extracellular viscous mucus that distended adjacent alveolar spaces. Also, this clear, gray or foamy material within mucin-producing columnar tumor cells and extracellular viscous mucus showed positive for Alcian Blue PAS staining (Figure 1, Table 1). The non-mucinous BACs were characterized by a proliferation of uniform cubo, low columnar, or peg shaped cells lining intact, slightly thickened alveolar walls. The histology grade was defined as well differentiated, moderately differentiated, or poorly differentiated on the basis of cytological features and architectural characteristics of the invasive component when present. A tumor was called infiltrative if it showed dense fibroelastic and desmoplastic connective tissue infiltrated by neoplastic cells-seen in glandular configurations, as nests of cells with no glandular differentiation, or individually. The BAC component was determined by comparing the amount of lepidic BAC versus infiltrative tumor. Each tumor was then assigned a BAC component score: 5 indicates 100% lepidic growth and 0% infiltration; 4 indicates 75% to 99% lepidic growth and 1% to 25% infiltration, 3 indicates 50% to 74% lepidic growth and 26% to 50% infiltration; 2 indicates 25% to 49% lepidic growth and 51% to 75% infiltration; and 1 indicates 0% to 24% lepidic growth and 76% to 100% infiltration.

Procedures

Following initial examination, the paraffin tissue block was re-cut, and serial sections were taken for immunohistochemical staining. Sections, 3µm thick, were cut from paraffin-embedded tissue for immunohistochemical staining. Initial sections were stained for Hematoxylin and Eosin to verify histology. After deparaffinization and antigen retrieval using Target Retrieval Solution (DAKO, CA, USA) for TTF-1, for 40 minute heating protocol in microwave oven and proteinase K (DAKO; CA; USA) for CK 7 for 5 minutes, sections were incubated with 3% hydrogen peroxide for 15 minutes to block

endogenous peroxidase activity. The specimen is then incubated with primary antibodies: Mouse monoclonal antibody against TTF-1 (clone 8G7G3/1, DAKO, CA, USA) were used at a dilution of 1:50 and ready to use mouse monoclonal antibody against CK 7 (clone OV-TL 12/30, DAKO, CA, USA) for 30 minutes, followed by sequential 30-minute incubation with a biotinylated link antibody and peroxidase-labelled streptavidin, which belong to modified labeled avidin-biotin technique-LSAB2/HRP System (DAKO; CA; USA). Staining was completed after incubation by Substrate Chromogen (AEC and DAB). DAB (3-3' diaminobenzidine) (DAKO; CA; USA) was used for 10 minutes and resulted in brown-colored precipitate at the TTF-1 nuclear antigen sites. AEC (3-amino-9-ethylcarbazole) (DAKO; CA; USA) was incubated for 30 minutes and resulted in red-coloured precipitate at the CK7 cytoplasmic and membrane antigen sites. Immunoreactivity of the normal lung tissue was used as a positive control. Immunoreactivity was evaluated according to the intensity of tumor cell staining (0 = no staining; 1 = mild staining; 2 = moderate staining; 3 = marked staining) as well as according to the percentage of tumor cells that were stained.

Statistical analysis

Group means were compared by student t test. The relationships between variables were described by correlation and multivariate regression analyses. $P < 0.05$ was considered statistically significant.

RESULTS

In this series of 30 Adenocarcinomas with BAC component, 10 (33.3%) could be classified as pure BAC by current WHO criteria (Table 2). Adenocarcinomas without BAC component showed moderate to strong positive TTF-1 and CK 7 reactivity (Table 3). All cases of non-mucinous BAC (n = 9)

TABLE 2. Classification of lung adenocarcinoma according to current WHO criteria.

Histology type	n	(%)
Adenocarcinomas Mixed Type with BAC Component	20	66.7
Pure Mucinous BAC	1	3.3
Pure Non-Mucinous BAC	9	30.0
Adenocarcinomas	30	100.0

TABLE 3. Presence of bronchioloalveolar component in lung adenocarcinomas versus degree of immunostaining tumor regions

BAC Component	*Intensity	TTF-1				CK7			
		0	1	2	3	0	1	2	3
Adenocarcinomas with		4	6	2	18	1	4	5	20
Adenocarcinomas without		3	6	6	15	3	0	9	18

*0= no staining, 1= mild staining, 2= moderate staining, 3= marked staining




FIGURE 1. Mucinous bronchioloalveolar carcinoma positive for Alcian Blue PAS (x20).

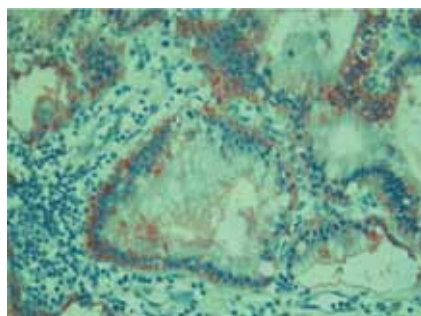


FIGURE 2. Bronchioloalveolar carcinoma that demonstrates diffuse and strong positive staining for TTF-1 (x20).

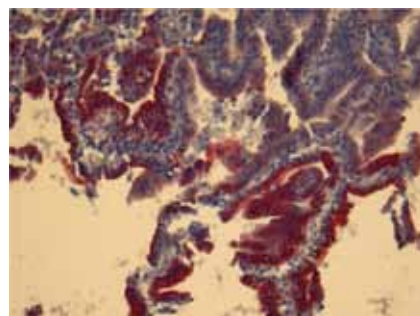


FIGURE 3. Bronchioloalveolar carcinoma that demonstrates strong immunoreactivity for CK 7 (x20).

showed moderate to strong TTF-1 reactivity and strong positive CK7 reactivity (Table 4). The one mucinous tumor showed a different Immunohistochemical profile: there was no TTF-1 reactivity and strong CK7 reactivity (Table 4). The adenocarcinomas mixed type with bronchioloalveolar component were examined and segregated according to the degree of cellular differentiation (histology grade), and most of them (21 of 30) were called moderately differentiated (Table 5). Most well differentiated tumors were given high BAC component scores (i.e., had small infiltrative components), and most tumors that were called poorly differentiated had relatively low BAC component scores (i.e., had a predominantly infiltrative component). Of the 30 cases evaluated, 2 were considered well differentiated, 21 were considered moderately differenti-

ated, and 7 were considered poorly differentiated (Table 5). Comparing the histology grade to TTF-1 staining within lepidic region of adenocarcinoma with BAC component, showed marked staining (2.7-3.0) in all cases (30 of 30) (Table 5, Figure 2). Although, in infiltrative regions TTF-1 marker showed moderate staining (2.0-2.5). TTF-1 showed best expression in well differentiated adenocarcinomas with BAC in both of the lepidic and infiltrative region (Table 5). Comparing the histology grade to CK 7 staining within lepidic region of adenocarcinoma with BAC component, it showed marked staining (3.0) in all adenocarcinoma with BAC component with no significant correlation to histology grade (Figure 3). But comparing the histology grade to CK 7 staining within infiltrative region of adenocarcinomas with BAC component it showed moderate to strong staining (2.6-2.8). CK 7 showed marked staining (3.0) in lepidic and infiltrative regions of well differentiated adenocarcinomas with BAC (Table 5).

TABLE 4. Degree of immunostaining in mucinous and non-mucinous bronchioloalveolar carcinoma, and mixed type adenocarcinomas with bronchioloalveolar component

Histology type	*Intensity	TTF-1				CK7			
		0	1	2	3	0	1	2	3
Non-mucinous Bronchioloalveolar Carcinoma (n=9)		0	1	1	7	0	0	1	8
Mucinous Bronchioloalveolar Carcinoma (n=1)		1	0	0	0	0	0	0	1
Mixed Type of Adenocarcinoma With Bronchioloalveolar Component (n=20)		2	5	1	11	1	3	5	11

*0= no staining, 1= mild staining, 2= moderate staining, 3= marked staining

TABLE 5. Histology grade versus Cytokeratin 7 (CK 7) and Thyroid Transcription Factor 1 (TTF-1) immunostaining adenocarcinoma mixed type with bronchioloalveolar component

Histology grade (n=30)	Lepidic		Infiltrative	
	CK7	TTF-1	CK7	TTF-1
WD (n= 2)	3.0	3.0	3.0	2.5
MD (n= 21)	3.0	2.9	2.6	2.2
PD (n= 7)	3.0	2.7	2.8	2.0

WD, well differentiated; MD, moderately differentiated; PD, poorly differentiated.

DISCUSSION

The WHO's recent reclassification of BAC has renewed interest in this subtype of pulmonary adenocarcinomas. In our series, however, only 10 of 34 pulmonary adenocarcinomas with BAC component fulfilled current WHO criteria for diagnosis of BAC. Bronchioloalveolar carcinomas can be classified into mucinous and non-mucinous subtype; tumors that exhibit both mucinous and non-mucinous histology patterns have been described as mixed subtype of BAC. Mucinous BACs display goblet or mucin-producing cells, whereas non-mucinous BACs show predominantly Clara cell or Type II pneumocyte differentiation. In our study, nine cases were classified as non-mucinous, and only one as mucinous bronchioloalveolar carcinoma. Sarantopoulos et al. showed that in their series of 45 adenocarcinomas with BAC component, only 7 were diagnosed as pure bronchioloalveolar carcinoma [3]. Lau et al. reviewed 67 cases of bronchioloalveolar carcinoma, 48 cases were classified into non-mucinous, and 12 as mucinous subtypes, as well as those that were mixed histology, displaying morphologic features of both [4].

Determination of the primary site of origin of adenocarcinoma is crucial for appropriate management. Bronchioloalveolar carcinoma can be present as multiple lung nodules similar to metastatic tumors to lung. Conversely, metastatic colonic adenocarcinoma to the lung can grow in a lepidic fashion similar to BAC. Immunohistochemical markers in conjunction with clinical history may be useful in distinguishing primary from metastatic adenocarcinoma in the lung. Determination of the cytokeratin (CK) and thyroid transcription factor-1 (TTF-1) immunohistochemical profile of a carcinoma is known to be useful aid in ascertaining the site of origin of an adenocarcinoma. We found that all nine cases of non-mucinous BACs were positive for CK7, 90% of them showed marked staining and also one case of mucinous BAC showed marked staining for CK7. In study by Shah et al. 14 cases of non-mucinous BAC and 19 cases of mucinous BAC showed diffuse CK 7 expression [5]. Tan et al. observed a CK7 positive in four of four cases, two of which showed ultrastructure evidence of mucinous differentiation [6]. Ritter et al. noted positive staining for CK7 in five of five non-mucinous BACs [7]. Goldstain et al. found that mucinous bronchioloalveolar adenocarcinomas rarely expressed TTF-1. The reason mucinous bronchioloalveolar adenocarcinoma cells are TTF-1 nonreactive is unknown. Possibly it is a reflection of the function of TTF-1 and the cells in which it is normally expressed [8]. TTF-1 marks both neoplastic and normal pulmonary bronchioloalveolar cells and is currently applied worldwide to determine, with a high degree of certainty, whether a lesion is primary to the lung or metastatic. TTF-1 expression is a tissue specific transcription factor that is expressed by epithelial cells in the thyroid and lung. Immunohistochemical positivity of BACs has been well established, with such tumors addressed in most primarily as a subset of general category of pulmonary adenocarcinomas. Expression of TTF-1 in the context of mucinous and non-mucinous subtypes of BACs, however, has not been well described. It has been suggested that mucinous pulmonary adenocarcinomas, including those with bronchioloalveolar type, tend to be TTF-1 negative. Pelosi et al described the role of TTF-1 immunoreactivity in non-small cell lung carcinoma including BAC and showed value of this marker in diagnosing pulmonary adenocarcinomas. Their study describes TTF-1 immunoreactivity in the lung predominantly as a product of the glandular component of normal and neoplastic lung cells. The most common type of BACs, non-mucinous variant, is thought to be derived from the type II pneumocyte/Clara cells. This cell is said to secrete lung surfactant and other proteins vital to normal lung function. TTF-1 immunoreactivity did not significantly affect patient survival, although patients with more than 75% immunoreactive neoplastic cells showed a trend for longer overall and disease-free survival [9].

In the present study all nine cases of non-mucinous BACs were positive for TTF-1, and 78% showed marked staining. One case, mucinous bronchioloalveolar carcinoma was negative for TTF-1 staining. Lau et al. noted that there was no detectable TTF-1 staining in 12 mucinous BACs, in contrast to the positive staining present in 36 (75%) of 48 BACs of non-mucinous subtype [4]. Kaufmann and Dietel noted similar absence of TTF-1 staining in their examination of mucinous pulmonary carcinomas; five of which were BACs [10]. Saad et al. reported that in non-mucinous bronchioloalveolar carcinoma they found strong (3+) and diffuse nuclear TTF-1 staining in more than 75% of 32 cases, and in mucinous bronchioloalveolar carcinoma TTF-1 was negative in majority of cases (85%). Non-mucinous and mucinous BACs exhibit disparate staining patterns with TTF-1, with non-mucinous BAC demonstrating greater positivity [11, 12]. TTF-1 immunostaining for all adenocarcinomas with BAC component showed significant greater TTF-1 immunoreactivity within lepidic portions of more infiltrative tumors. When the lepidic and infiltrative regions of neoplasms were compared, the regions of lepidic growth exhibited a somewhat higher degree of TTF-1 immunoreactivity. Our findings suggests that more well differentiated tumor cells (found within the lepidic regions of tumor growth) are more likely to retain the ability to express common antigens that more infiltrative or high-grade cells may lose. Tumors with a relatively higher percentage of lepidic regions were well-differentiated tumors.

CONCLUSION

The current study demonstrated that only 10 of 34 pulmonary adenocarcinomas with BAC component fulfilled current WHO criteria for diagnosis of BAC. Nine cases were classified into non-mucinous and only one case was recognized as mucinous BAC, it showed positive for Alcian Blue PAS staining. The findings in the present study confirm that mucinous BACs demonstrates the TTF-1 negative/CK7 positive immunophenotype, non-mucinous BACs showed TTF-1 positive/CK7 positive immunophenotype. This suggests that in the context of differentiating mucinous BACs from extrapulmonary mucinous tumors metastatic in the lung, evaluation of TTF-1 and CK7 expression may have limited diagnostic utility.

DECLARATION OF INTEREST

There was no financial support received for the work and the authors had no financial involvement or affiliation with any organization whose financial interests may be affected by material in the manuscript, or which might potentially bias it.

REFERENCES

- [1] Travis WD, Brambilla E, Muller-Hermelink H, Harris C. Pathology and genetics of tumors of the lung, pleura, thymus and heart. World Health Organization Classification of Tumors. Lyon: IARC Press, 2004, pp. 36-39.
- [2] Travis WD, Garg K, Franklin WA, Wistuba II, Sabloff B, Noguchi M. et al. Bronchioloalveolar Carcinoma and lung adenocarcinoma: the clinical importance and research relevance of the 2004 World Health Organization Pathologic Criteria. *J Thorac Oncol.* 2006;1: S13-S19
- [3] Sarantopoulos GP, Gui D, Shintaku P, Hong L, Wang YY, Yap CS, et al. Immunohistochemical analysis of lung carcinomas with pure or partial bronchioloalveolar differentiation. *Arch Pathol Lab Med.* 2004;128(4):406-14.
- [4] Lau SK, Desrochers MJ, Luthringer DJ. Expression of Thyroid Transcription Factor-1, Cytokeratin 7, and Cytokeratin 20 in bronchioloalveolar carcinomas: an Immunohistochemical evaluation of 67 cases. *Mod Pathol* 2002; 15:538-542.
- [5] Shah RN, Badve S, Papreddy K, Schindler S, Laskin WB, Yeldandi AV. Expression of cytokeratin 20 in mucinous bronchioloalveolar carcinoma. *Hum Pathol.* 2002;33(9):915-20.
- [6] Tan J, Sidhu G, Greco MA, Ballard H, Wiczorek R. Villin, cytokeratin 7, and cytokeratin 20 expression in pulmonary adenocarcinoma with ultrastructural evidence of microvilli with rootlets. *Hum Pathol.* 1998;29(4):390-6.
- [7] Ritter JH, Boucher LD, Wick MR. Peripheral pulmonary adenocarcinomas with bronchioloalveolar features: immunophenotypes correlate with histologic patterns. *Mod Pathol* 1998; 11: 566-572.
- [8] Goldstein NS, Thomas M. Mucinous and nonmucinous bronchioloalveolar adenocarcinomas have distinct staining patterns with thyroid transcription factor and cytokeratin 20 antibodies. *Am J Clin Pathol.* 2001;116(3):319-25.
- [9] Pelosi G, Frassetto F, Pasini F, Maisonneuve P, Sonzogni A, Ianuzzi A, et al. Immunoreactivity for thyroid transcription factor-1 in stage I non-small cell carcinomas of the lung. *Am J Surg Pathol.* 2001;25(3):363-72.
- [10] Kaufmann O, Dietel M. Thyroid Transcription Factor-1 is the superior Immunohistochemical marker for pulmonary adenocarcinomas and large cells carcinomas compared to surfactant proteins A and B. *Histopathology* 2000; 36:8-16.
- [11] Saad RS, Cho P, Silverman JF, Liu Y. Usefulness of Cdx2 in separating mucinous bronchioloalveolar adenocarcinoma of the lung from metastatic mucinous colorectal adenocarcinoma. *Am J Clin Pathol.* 2004;122(3):421-7.
- [12] Saad RS, Liu LY, Han Helen, Landreneau RJ, Silverman JF. Prognostic significance of thyroid transcription factor-1 expression in both early stage conventional adenocarcinoma and bronchioloalveolar carcinoma *Hum Pathol.* 2004; 35:3-7