



Pathologic morphology of acute experimental osteomyelitis

Nikolay S. Strelkov¹, Nikolay A. Kiryanov², Pavel O. Shklyaev¹, Yury M. Iryanov³

¹Department of Pediatric Surgery, Izhevsk State Medical Academy, Kommunarov str., 281, Izhevsk, 426034, Russia. ²Department of Pathology, Izhevsk State Medical Academy, Kommunarov str., 281, Izhevsk, 426034, Russia. ³Laboratory of Morphology, Russian Ilizarov Scientific Center for Restorative Traumatology and Orthopaedics, M.Ulyanova str., 6, Kurgan, 640014, Russia.

ABSTRACT

The goal of our work was to study the changes in the bone tissue, bone marrow and surrounding tissues in animals during early stages of experimental osteomyelitis. Osteomyelitis was simulated in 30 infant rabbits aged 3-4 months whose body weight accounted 1200-1600 grams through the insertion of 5-6 million of aureococcus into the marrow channel of a shinbone. The study of bone marrow, bone tissue and surrounding tissue was conducted 30 minutes, 6, 12, 24, 48 and 60 hours after the contamination with the help of light and electronic (transmission and scanning) microscopy. It was proved that the first changes are characterized by the evident changes in the vessel's walls which cause the swelling of bone marrow and suppurative inflammation in the bone tissue occurs only in the end of the 3d day of the experiment. These data confirm the necessity of osteoperforation during the first 24 hours of contamination in order to remove the swelling and to correct vessel disorders.

© 2013 Association of Basic Medical Sciences of FB&H. All rights reserved

KEY WORDS: osteomyelitis, experiment, early stages, osteoperforation

INTRODUCTION

Osteomyelitis is an inflammatory process localized in bone tissues and bone marrow. Nowadays the greatest importance is given to hematogenous osteomyelitis, which is predominantly found in children (85%). This type of osteomyelitis has its pathogenetic, clinical and anatomical peculiarities which are not fully determined up to the present moment [1, 2, 3, 4, 5]. Etiology of acute hematogenous osteomyelitis is currently well-studied [3, 6, 7, 8, 9]. Any microbe or its associations can cause inflammatory process in the bone marrow, however up to the present moment the most frequent pathogenic organism is *Staphylococcus aureus* (from 65% to 90%). It defines need of the early beginning of antibiotic treatment [1, 6, 9, 10, 11, 12, 13]. The primary infection sources are mucous membranes, umbilical ring, lymphoid ring and pustular skin diseases, etc. [2, 3, 7]. However, very often it's quite hard to determine the infection source. In spite of the clearness of the etiologic factor, the questions of acute hematogenous osteomyelitis pathogenesis are not

well defined till the present moment. There are two mostly reasonable theories of disease pathogenesis. Firstly, there is the phenomenon of bacterial bone marrow embolism [2, 3], which implicates the retention of germs within the blood vessels, the platelet-associated vasculitis formation and successive development of diffuse or local suppurative inflammation. Secondly, some local and general conditions (or risk factors) are crucially important, for example - anatomic and physiological peculiarities of a growing bone, the amplitude of blood supply, the presence of wide sinusoids and retarded blood flow within them - all this facilitates the microorganism fixation, cooling and sensibilization of an organism. Osteomyelitis is often associated with trauma [6]. The osteomyelitis morphology in children is thoroughly described in literature [3, 7]. However, the earliest changes occurred in the bone tissue (hours and first day) are not well-illustrated in the specialized literature. Thus, many authors notice that vascular disorders in bone tissue and bone marrow determine pathogenesis and future development of a disease. Some authors [3] attach great significance to the thrombosis, ischemia, which is connected with it and bone tissue necrosis. Other scientists attach the greatest importance to hemorrhages which form the positive environment for microorganisms' reproduction and for following occurrence of inflammatory process [8]. Some researches give the first place to the overhydration of bone

* Corresponding author: Nikolay A. Kiryanov, Department of Pathology, Izhevsk State Medical Academy, Kommunarov str., 281, Izhevsk, 426034, Russia. Phone: +7 (3412) 68 52 24; Fax: +7 (3412) 65 8167 e-mail: kirnik@igma.udm.ru

Submitted: 8 November 2012 / Accepted: 24 April 2013

marrow caused by the accumulation of tissue fluid which in its turn can cause circulation disorders and necrosis [3]. The information insufficiency of all these issues determined the necessity of a deep research of early stages of acute hematogenous osteomyelitis. We focused our attention on the peculiarities of vascular disorders within the bone marrow, bone tissue and surrounding soft tissues and their connection with the occurrence of inflammation and bone tissue destruction. Moreover, there is a need to confirm carrying out an early osteopuncture of the bone marrow channel with possibility of morphological research of a bone tissue at early stages of osteomyelitis [4, 14, 15].

MATERIAL AND METHODS

All experiments in this study were performed in accordance with guidelines for animal research and were approved by our academy Ethics Committee.

Experimental groups

Acute osteomyelitis was simulated in 30 infants rabbits aged 3-4 months whose body weight accounted 1200-1600 grams through the insertion of 5-6 million of aurococcus into the marrow channel of a shinbone. The gems were inserted together with 0.5 ml of acetylated collagen suspension (10mg/ml) and physiological saline of sodium chloride. The animals were taken out of the experiment after 30 minutes, 6, 12, 24, 48 and 60 hours after the contamination correspondently to perform histological research of shinbones and surrounding soft tissues. After macroscopic examination the fragments were sawed out from the bone in lengthwise and lateral directions at the levels of epiphyses, metaphyses, and diaphyses.

Morphological evaluation

After relevant manipulations histological samples were examined through the means of light and electronic (transmission and scanning) microscopy.

RESULTS

During first 30 minutes of the experiment the macroscopic changes in the bone were minimal. In the very beginning of experimental osteomyelitis a small edema of the bone marrow and singular small hemorrhages were revealed within the zone of a burr hole. During light microscopic examination a simple medical pattern of a bone marrow was noticed, namely preserved bone rods and small groupings of erythrocytes. During scanning electronic microscopic examination in the adipoid bone marrow the adipocytes and small areas of hemopoiesis were determined. During transmission electronic microscopic examination at this

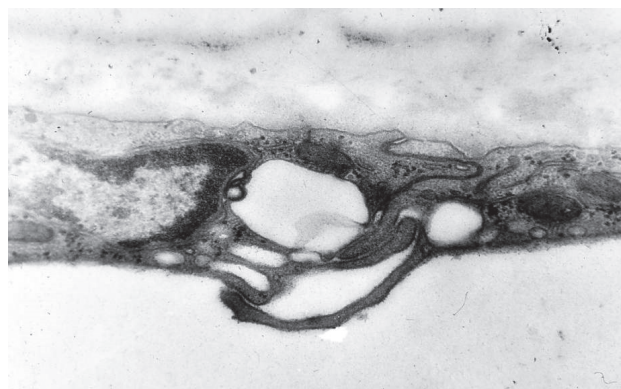


FIGURE 1. Formation of Interendothelium hatches and an endothelium pore in a blood capillary of BM. 30 min. of experiment. Transmission electron microscopy. Magnification x3300.

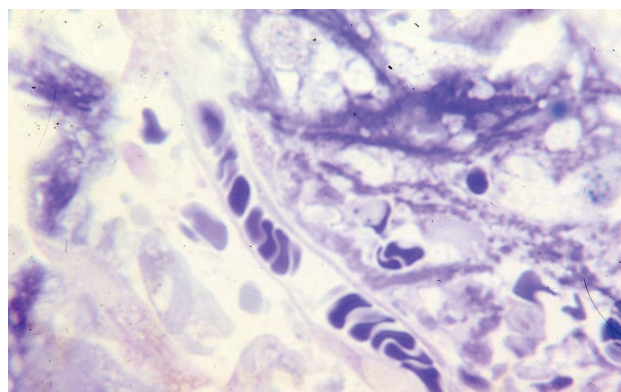


FIGURE 2. Sludge in arteriole of BM and perivascular edema. 6 hours of experiment. Semi-thin section. toluidine blue. Magnification x900.

experimental stage the mast cells with starting degranulation were registered. Herewith the specific granules which contain heparin, serotonin and histamine exposed through the means of exocytosis to the extracellular environment. Simultaneously the process of vessel wall permeability increased in the vessels of microcirculatory bloodstream. This was revealed first of all through the emergence of numerous micropinocytotic vesicles in luminal locuses of endotheliocyte cytoplasm in blood capillaries of bone marrow. Besides that the disintegration of inter-endothelial links within the walls of venules and capillaries was registered. The vacuoles of different calibers appeared in the locations of disintegration, this confirmed the reinforcement of vessels permeability (Figure 1). Within the walls of some micro vessels the inter-endothelial stomas and endothelial pores were formed, they were clearly seen with the help of the method of scanning electronic microscopy. The groupings of blood corpuscle, predominantly erythrocytes were found around vessels. During next 6 hours of experiment the diffuse disorders of microcirculatory bloodstream vessels were reg-

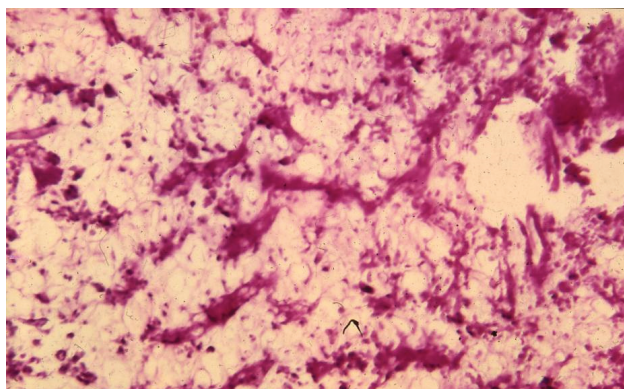


FIGURE 3. The sharpest swelling of BM in an inflammation zone. 12 hours of experiment. Hematoxylin and eosine. Magnification x80.

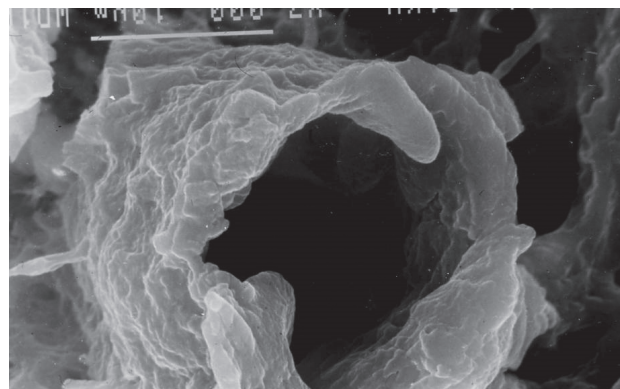


FIGURE 4. Considerable dissociation of interendothelium contacts in the vein of BM. 12 hours of experiment. . Scanning electron microscopy. Magnification x 3000.

istered. These disorders were characterized by the expansion of capillaries, arterioles and venules and by the occurrence of blood storage in all above-mentioned vessels. The signs of sludge-phenomenon were registered in small vessels together with the accumulation of liquid blood components in perivascular space (Figure 2). Simultaneously we registered the marginal position of leucocytes and the beginning of its adhesion to the luminal surface of endotheliocytes of venules and capillaries. The high level of neutrocytes' activity was registered; this was revealed through the formation of links not only with endothelium, but also with blood corpuscle, for example with erythrocytes. Destructive processes within the vessel wall were progressively growing and it caused the significant swelling of basal membrane, its shredding and fragmentation together with simultaneous formation of numerous vacuoles within disintegrated inter-endothelial links. Even during this period, the accumulation of lymphocytes and macrophages and the formation of cytoplasmic bridges between them in the focus of inflammation could be observed. This is the evidence of active functions of immunocompetent cells in the very beginning of the inflammatory process. During next 12 hours of experiment, the manifestation degree of vascular disorders was growing very fast, it was demonstrated first of all through paralytic expansion of microcirculatory bloodstream vessels and the formation of a significant swelling of the neighbor tissues (Figure 3). We also paid attention to the significant increase of germ's quantity, which were registered on semi-thin sections in large quantities often near mast cells, which were at the stage of degranulation. The examination performed with the help of electronic microscope revealed the germs in the blood vessels luminas. Simultaneously inter-endothelial links, digitules which encircled the germs were registered within the endotheliocyte. Destructive processes within the blood vessels wall were progressively increasing and they were

characterized by the damage primarily of marginal parts of endotheliocytes and the occurrence of myelin formations. Especially evident patterns were revealed in the process of blood vessels examination with the help of scanning electronic microscope. The blood vessel wall was not simply swollen and thick, but there were wide inter-endothelial pores which provided the exit from the bloodstream for liquid components of blood and blood corpuscle (Figure 4). The inner microrelief was smoothed due to the paralytic expansion of arterioles and venules; however numerous micropinocytotic vesicles appeared on the surface of capillaries which belonged to the sinusoid type. By the end of the first 24-hours of experiment the significant swelling of vessel walls and endotheliocytes vacolation within the bone marrow blood vessels were registered, this confirmed the development of destructive processes. The vessel wall destruction was especially evident during electronic microscopic examination. Thus, besides endotheliocytes vacolation severe changes were revealed through localized microplasmacitosis. Even in this period mucoid and fibrinoid vessel wall swelling was registered which helped to increase the vessel wall permeability (Figure 5). This could be the reason of occurrence of small and large hemorrhages against evident swelling and serous exudates which contained solitary neutrophilous leucocytes, monocytes and erythrocytes. We gave special attention to the thrombosis formation, because there is no reference concerning its formation period and its role on the bone marrow pathogenesis in the available literature. Our research has confirmed that vessel thrombosis is a rare case during first 24-hours, it can be revealed only by the end of first day when destructive processes in the blood vessel wall become more evident and frequent. During first two days of experiment the thrombosis (micro thrombosis) rapidly increased, however it differed from case to case. There were numerous micro blood clots in the vessel's luminas. The evidence of destruc-

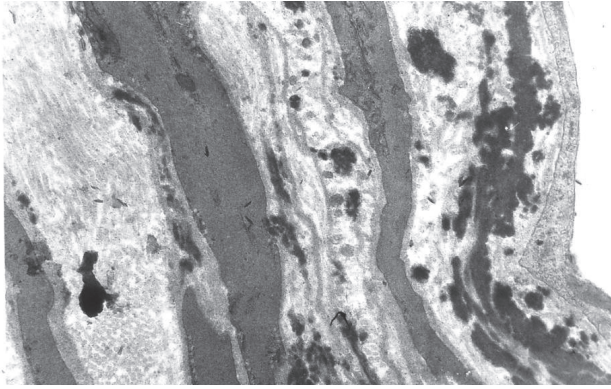


FIGURE 5. Fibrinoid swelling of a wall of a vein with accumulation of fibrin in the intima and between smooth muscle cells. 48 hours of experiment. Transmission electron microscopy. Magnification x15 000.

tive processes in the vessel wall increased significantly and was accompanied by fibrinoid necrosis, accumulation of the large quantity of fibrin in the intima and media, swelling and destruction of collagenous fibers, exactly these conditions can be connected with the increase of cell's reaction. This reaction was characterized by the occurrence of perivascular sockets formed from neutrocytes, lymphocytes and other cells from the inflammatory range, then these new formations spread to the neighbor areas and small and large focuses were formed among the bone marrow cells. As a rule there was a zone of perifocal accumulation of serous or serous fibrinous exudates. The fragments of destroyed stromal cells of the bone marrow were registered within exudates zone. Exudates were spread between bone trabecules and penetrated into Haversian channels. If during previous period we did not see the damage of bone rods, we had noticed plain resorption. However we didn't reveal osteoclastic bone tissue resolution. It seems that the mechanism of bone tissue destruction is primarily connected with its demineralization caused by the exudate's influence, but we can not exclude the ischemic factor which is connected with severe microcirculation disorders. Together with the starting processes of bone marrow destruction the first signs of osteoblastic activity reinforcement appeared by the end of the 2d day. These signs significantly increased during the 3d day and they were characterized both by the occurrence of osteoblasts and perivascular spaces near capillaries and the occurrence of ultrastructural signs of albuminous and synthetic processes revealed through the increase of endoplasmic net. During first three days of the experiment the inflammatory process in the bone was visualized as the groupings of gray and yellow exudates within bone marrow cavity, sometimes in subperiosteal space and sometimes in soft tissues of the limb. The method of light microscopic examination showed that primary suppurative exudate which con-

tained numerous neutrocytes was found both in the bone marrow channel and between bone rods. The plain bone resorption was evident in the parts of bone tissue which were close to the exudate. Exudates from bone marrow cavities spread into Haversian canals and formed a kind of sockets around the blood vessels and compressed them. During this stage of the experiment the reparative processes in the bone tissue increased, it was revealed through the occurrence of numerous osteoblasts with hyperplasia of albuminous and synthetic apparatus and the reinforcement of fibrillogenesis around the inflammation focus which was realized through the fibroblast's proliferation with newly formed collagenous fiber on their surface.

DISCUSSION

There through, when the microorganisms get into bone narrow channel they multiply very fast and their quantity rapidly increases during first 6-12 hours. These microorganisms and toxins, which they produce, cause mast cells degranulation and the secretion of biologically active substances, which in their turn cause vascular reaction as paralytic vasorelaxation of microcirculatory bloodstream, sludge-phenomenon formation and stasis. Formation of micro blood cloths within the vessels of microcirculatory bloodstream is mostly characteristic for the 2d and the 3d days of experiment, however it is not registered in all observations. Simultaneously destructive processes occur and develop within the blood vessels walls, they are caused by the toxins and biologically active substances and the tissue decay products. These destructive processes revealed as mucoid and fibrinoid swelling end up with blood vessel wall necrosis; it causes high vessel permeability and is accompanied by the outgate of liquid blood components to the neighbor tissues and the formation of swelling which is usually registered during first 24-hours of experiment. Later serous and serous fibrinous exudate formations occurred which became suppurative one by the end of the 3d day. Thus we can treat the inflammation in the bone marrow as dynamical process, which transforms serous exudate into fibrinous one and consequently into suppurative one and forms typical zonal structure.

CONCLUSION

This research shows the significance of vessel disorders at the early stages of the experimental osteomyelitis. Results of work demonstrate the spreading destruction of blood vessels walls in the bone marrow which causes significant bone marrow swelling. The inflammation occurs later and develops into suppurative and serous form during first 3 days. Current research confirms the necessity of osteo-

perforation during first 24 hours of hematogenous osteomyelitis to relieve the swelling and damages of the vessels.

DECLARATION OF INTEREST

The authors declare no conflict of interest.

REFERENCES

- [1] Dartnell J, Ramachandran M, Katchburian M. Haematogenous acute and subacute paediatric osteomyelitis: a systematic review of the literature. *J Bone Joint Surg Br.* 2012;94(5):584-595.
- [2] Ferroni A, Al Khoury H, Dana C, Quesne G, Berche P, Glorion C, Péjin Z. Prospective survey of acute osteoarticular infections in a French paediatric orthopedic surgery unit. *Clin Microbiol Infect.* 2012. doi: 10.1111/1469-0691.12031. [Epub ahead of print]
- [3] Ikpeme IA, Ngim NE, Ikpeme AA. Diagnosis and treatment of pyogenic bone infections. *Afr Health Sci.* 2010;10(1):82-88.
- [4] Shamsiev AM, Burgutov MD, Baibekov IM, Makhmudov ZM. [Surgical treatment of septicopyemic form of acute hematogenous osteomyelitis in children]. *Vestn Khir Im I I Grek.* 2010;169(6):51-53.
- [5] Sreenivas T, Nataraj AR, Menon J, Patro DK. Acute multifocal haematogenous osteomyelitis in children. *J Child Orthop.* 2011;5(3):231-235.
- [6] Carek PJ, Dickerson LM, Sack JL. Diagnosis and management of osteomyelitis. *Am Fam Physician.* 2001; 63(12):2413-2420.
- [7] Labbé JL, Peres O, Leclair O, Goulon R, Scemama P, Jourdel F et al. Acute osteomyelitis in children: the pathogenesis revisited? *Orthop Traumatol Surg Res* 2010; 96(3):268-275.
- [8] Song KM, Sloboda JF. Acute hematogenous osteomyelitis in children. *J Am Acad Orthop Surg.* 2001;9(3):166-175.
- [9] Weichert S, Sharland M, Clarke NM, Faust SN. Acute haematogenous osteomyelitis in children: is there any evidence for how long we should treat? *Curr Opin Infect Dis.* 2008;21(3):258-262.
- [10] Arnold JC, Cannavino CR, Ross MK, Westley B, Miller TC, Riffenburgh RH, Bradley J. Acute bacterial osteoarticular infections: eight-year analysis of C-reactive protein for oral step-down therapy. *Pediatrics.* 2012; 130(4): 821-828.
- [11] Lazzarini L, Mader JT, Calhoun JH. Osteomyelitis in long bones. *J Bone Joint Surg (Am)* 2004;86:2305-2318.
- [12] Peltola H, Pääkkönen M, Kallio P, Kallio MJ. Short- versus long-term antimicrobial treatment for acute hematogenous osteomyelitis of childhood: prospective, randomized trial on 131 culture-positive cases. *Pediatr Infect Dis J.* 2010;29(12):1123-1128.
- [13] Zaoutis T, Localio AR, Leckerman K, Saddlemire S, Bertoch D, Keren R. Prolonged intravenous therapy versus early transition to oral antimicrobial therapy for acute osteomyelitis in children. *Pediatrics.* 2009;123(2):636-642
- [14] Rusak PS, Vyshpinskiĭ IM, Brodskii BF. [Treatment of acute hematogenous osteomyelitis in children]. *Khirurgiia (Mosk).* 1991;(8):136-138.
- [15] Tiemann AH, Krenn V, Krukemeyer MG, Seyfert C, Jakobs M, Baumhoer D, Hofmann GO. [Infectious bone diseases]. *Pathologe.* 2011;32(3):200-209.