

# A histological study of the effect of exogenous melatonin on gentamicin induced structural alterations of proximal tubules in rats

Dina Kapić\*, Zakira Mornjaković, Esad Ćosović, Maida Šahinović

Institute of Histology and Embryology, Faculty of Medicine, University of Sarajevo, Ćekaluša 90, 71000 Sarajevo, Bosnia and Herzegovina

## ABSTRACT

The aim of this research was to assess the reactive changes of rat proximal tubules caused by gentamicin and the effect of relatively low doses of melatonin. 48 adult male Wistar rats were distributed into six groups of equal size which all received one of the following daily intraperitoneal injections: vehicle (5% ethanol in Ringer solution) during 11 days (C); gentamicin (80 mg/kg) during 8 days (G), two groups which concomitantly received gentamicin (80 mg/kg) during 8 days and melatonin in two different test doses (5 or 20 mg/kg) during 11 days (GM1, GM2) and two groups treated only with melatonin in two different doses (5 or 20 mg/kg) during 11 days (M1, M2). Histological analysis included qualitative and semi-quantitative light microscopy analysis of proximal tubules. Exogenous melatonin had no significant effect on the microstructure, independently of dosis. The changes of proximal tubules microstructure induced by gentamicin were expressed in the form of granulovacuolar degeneration, necrosis and desquamation. The grade of proximal tubular changes was smaller in animals who besides gentamicin received melatonin. Melatonin has a dose dependent protective effect on the structural alterations of proximal tubules of the kidney induced by gentamicin.

© 2014 Association of Basic Medical Sciences of FB&H. All rights reserved

KEY WORDS: gentamicin, melatonin, proximal tubules, rats, histological analysis

## INTRODUCTION

Gentamicin is an aminoglycoside antibiotic widely used in the treatment of infections caused by Gram negative bacterias [1, 2, 3]. The use of gentamicin is limited by its nephrotoxicity [4]. In fact, the treatment with this antibiotic, even in therapeutic doses, causes the damage of proximal tubules of the kidney [5]. Despite the introduction of newer antibiotics of lesser toxicity, gentamicin is still often used, because it's relatively low cost, and rapid bactericidal action [6, 7]. The mechanism of the genesis of gentamicin nephrotoxicity is still not completely clear, but it is assumed that the reactive oxygen species (ROS) are one of the main causative agents [8, 9]. This is the reason why it is considered that the negative action of gentamicin could be reduced with the concurrent use of an antioxidant agent. N-acetyl-5-metoxytryptamine (mela-

tonin), as the main product of the pineal gland, was shown to be a good protector in different models of kidney damage, e.g. ischemia-reperfusion injury [10] or changes induced by cisplatin [11]. Beside its most famous function – the regulation of the circadian rhythm [12], this molecule possesses other numerous functions including the immunomodulatory [13], the antiinflammatory [14], and the antioxidative role [15]. The facts that melatonin functions as an antioxidant and that it reduces oxidative damage on the physiological and pharmacological level [16] open the area of interest for use of melatonin in blocking the side effects of gentamicin. Therefore, the aim of this study was to test two different doses of melatonin regarding the gentamicin induced structural alterations of proximal tubules.

## MATERIAL AND METHODS

### Animals

Fourty eight adult male Wistar rats, weighing 200-300g, were maintained in standardized laboratory conditions with a temperature of  $23 \pm 2^\circ\text{C}$ , and a 12-hour light-dark cycle. Both standard rat chow and water were provided *ad libitum*.

\* Corresponding author: Dina Kapić,  
Institute of Histology and Embryology, Faculty of Medicine, University  
of Sarajevo, Ćekaluša 90, 71000 Sarajevo, Bosnia and Herzegovina  
Phone/Fax: +387 33 203 669  
e-mail: dina.kapic@mf.unsa.ba, dina.kapic@hotmail.com

Submitted: 28 March 2013 / Accepted: 23 January 2014

### Procedures

The rats were randomly assigned into six groups of equal size which all received one of the following daily intraperitoneal injections: group 1 (Control), the animals received vehicle (5% ethanol in Ringer solution) during 11 days, group 2 (G) rats that received gentamicin (80 mg/kg) during 8 days, group 3 (GM1) rats which received gentamicin (80 mg/kg) during 8 days and melatonin (5 mg/kg) 3 days before and 8 days concomitantly with gentamicin, group 4 (GM2) rats which received gentamicin (80 mg/kg) during 8 days and melatonin (20 mg/kg) 3 days before and 8 days concomitantly with gentamicin, group 5 (M1) rats that received melatonin (5 mg/kg) during 11 days and group 6 (M2) rats that received melatonin (20 mg/kg) during 11 days. The animals were sacrificed under ether anesthesia 24 hours after the last injection. Left kidneys were removed, fixed in 10% buffered formalin and then prepared for the qualitative and semiquantitative histological analysis using hematoxylin-eosin (H&E) and periodic acid - Schiff (PAS) staining. The study was carried out at the Institute of Histology and Embryology of the Faculty of Medicine of the University of Sarajevo, with the approval of the Local Ethics Committee. The histological analysis included qualitative and semiquantitative analysis of the proximal tubules of the kidney at the level of light microscopy. The semiquantitative analysis of the kidney sections was performed using the technique of Houghton et al. [17]. The changes seen were graded as follows: 0 = normal; 1 = areas of focal granulovacuolar epithelial cell degeneration and granular debris in tubular lumens with or without evidence of tubular epithelial cell desquamation in small foci (< 1% of total tubule population involved by desquamation); 2 = tubular epithelial necrosis and desquamation easily seen but involving less than half of cortical tubules; 3 = more than half of proximal tubules showing desquamation and necrosis but uninvolved tubules easily found; 4 = complete or almost complete proximal tubular necrosis.

### Statistical analysis

The chi-square test of independence was used to examine the dependence of the applied dose of melatonin on the grade of damage of proximal tubules. Probability values ( $p$ ) less than 0.05 were considered to be statistically significant.

## RESULTS

### Control group

The qualitative histological analysis revealed regular renal parenchymal structure. The proximal tubules appeared intact, having uniform tubular epithelial cells with a preserved brush border, the cytoplasm

having homogenous tinctorial properties, and the nuclei having regular size, position and chromasia (Figure 1A and 1B).

### G group

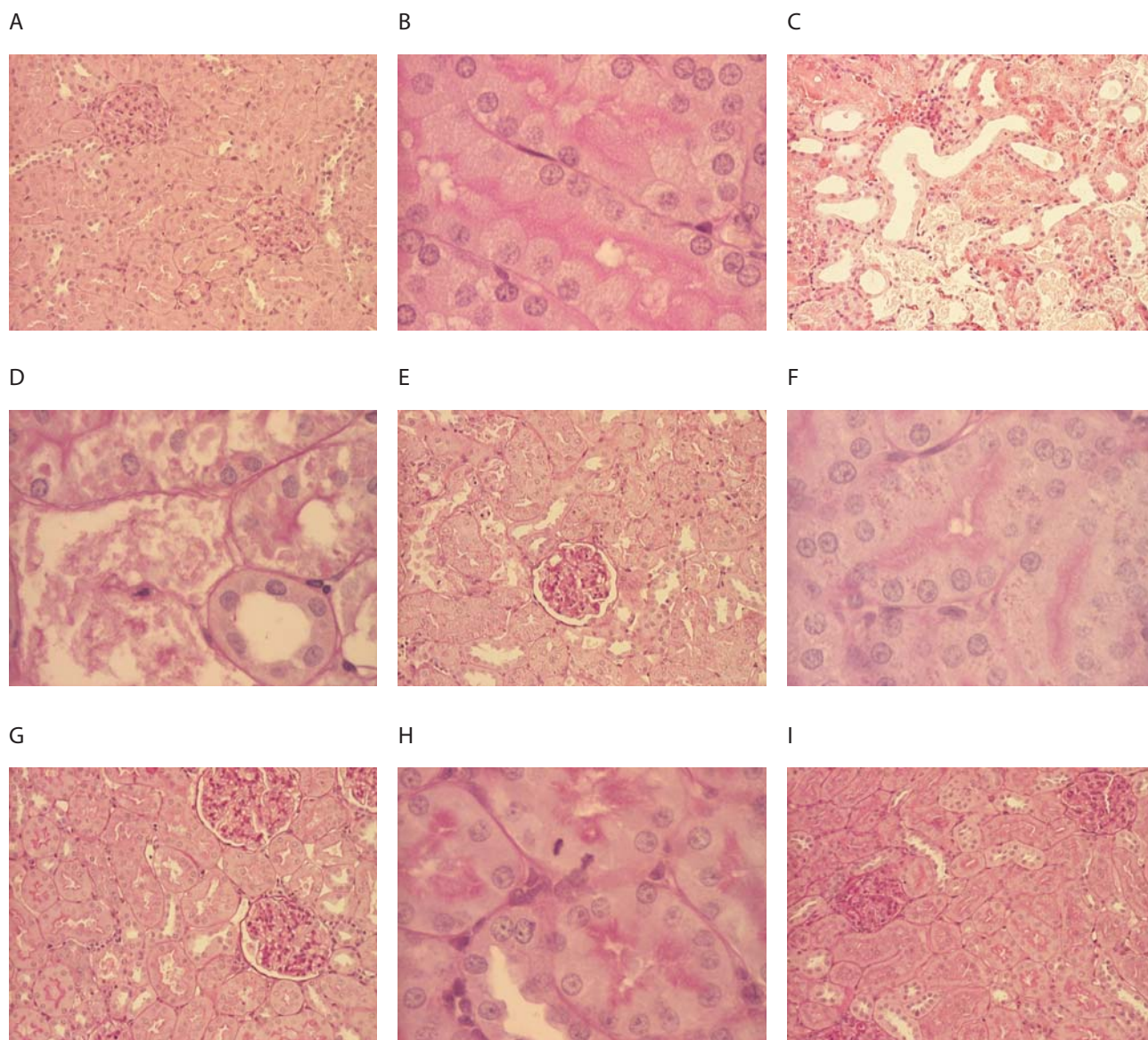
There were visible wide fields of heavy and extensive necrosis with numerous completely destroyed proximal tubules leaving only a bare basement membrane in the kidney cortex. Numerous proximal nephrocytes showed changed tinctorial properties – some cells showed enhanced acidophily while others were of pale appearance. The brush border was damaged on several places, and completely missing on others. In numerous nephrocytes it was possible to observe vacuolisation and/or the accumulation of PAS positive material in the form of differently sized and shaped granules, from barely visible round-oval granules to large, irregular agglomerations, which exceeded the size of the nucleus. It was also revealed that the nuclei were of different size, position and chromasia, and that several cells had lost their nuclei. One part of the tubules showed dilatation; in some tubules was evident the obliteration of the lumina by the presence of a necrotic cellular mass (Figure 1C and 1D).

### GM1 group

In the cortical parenchyma, we could observe relatively narrow areas of necrotically changed proximal tubules in comparison to areas of preserved structure. Histological changes of proximal tubular epithelial cells were more severe in the cortical than in the juxtamedullary tubules. The proximal nephrocytes showed signs of granulovacuolar degeneration and necrosis. The cytoplasm of the nephrocytes, showing necrosis, had changed tinctorial properties and the nuclei were pyknotic, and some nuclei showed signs of kariorexis. Necrotic cellular debris was observed in the lumina of some tubules. In a few nephrocytes it was possible to notice the presence of PAS positive granules of different size and shape, and it was possible to observe the vacuolisation of the cytoplasm. The brush border of some cells was completely missing and in some cells its structure was only partially damaged. We could also notice a few cells with mitotic figures. A mildly expressed oedema and an inflammatory infiltrate composed predominantly of lymphocytes were visible in the interstitium (Figure 1E and 1F).

### GM2 group

The architecture of the cortical parenchyma was mainly relatively preserved, and the fields with granulovacuolar degeneration, necrosis and/or desquamation were clearly spatially demarcated and extremely narrow. The proximal tubules were lined by simple columnar epithelium composed of acidophilic cells with no discrete cell margins between them. Their round uniform nuclei were positioned in the basal portion



**FIGURE 1.** Histological findings in kidneys of different groups. A control group (PAS, x100), B control group (PAS, x400), C gentamicin group (H&E, x100), D gentamicin group (PAS, x400), E gentamicin + melatonin (5 mg/kg) group (PAS, x100), F gentamicin + melatonin (5 mg/kg) group (PAS, x400), G gentamicin + melatonin (20 mg/kg) group (PAS, x100), H gentamicin + melatonin (20 mg/kg) group (PAS, x400), I melatonin (20 mg/kg) group (PAS x100).

of the cells. A well preserved brush border was visible on the apical pole. The basement membrane was continuous, had a regular structure and uniform thickness. Some nephrocytes were showing signs of granulovacuolar degeneration and necrosis with typical changes of the cytoplasm and nucleus. The cortical interstitial connective tissue had mainly a regular cellularity and only somewhere it was possible to find a sparse mononuclear inflammatory infiltrate (Figure 1G and 1H).

#### *M1 and M2 group*

Histological analysis of the cortex of the kidney in this two groups showed a regular architecture of the parenchyma. The acidophilic cells of the proximal tubules were having a uniform appearance, and their round nuclei were having typical basal position, tinctorial properties and size. The in-

terstitium had a preserved histological structure (Figure 1I). The result of the chi squared test of independence showed that the grade of proximal tubular damage (Table 1) induced by gentamicin was dependent on the applied dose of melatonin ( $\chi^2 = 20,12; p < 0.0005$ ).

**TABLE 1.** Histological degree of renal damage obtained by semi-quantitative analysis

GROUP	grade 0	grade I	grade II	grade III	grade IV
Control	8 (100%)	-	-	-	-
G	-	-	1 (12,5%)	7 (87,5%)	-
GM1	-	-	6 (75%)	2 (25%)	-
GM2	-	4 (50%)	4 (50%)	-	-
M1	8 (100%)	-	-	-	-
M2	8 (100%)	-	-	-	-

## DISCUSSION

The use of gentamicin is still very frequent in clinical practice despite its nephrotoxicity in 10-20% of therapeutic courses [7, 18]. Gentamicin induced nephrotoxicity is used in numerous studies as the model for the research of aminoglycoside toxicity. Taking into account that the ROS are regarded as one of the main causative factors of nephrotoxicity of gentamicin [8, 19], research has been done lately in order to develop therapies to reduce oxidative damage. In our research, the treatment with gentamicin at the dose of 80 mg/kg resulted with significant lesions of the epithelium of the proximal tubules which were changed in form of necrosis and granulovacuolar degeneration whereat grade 3 was recorded in 87.5% of animals. The interstitium was reactively changed - oedematous and infiltrated with mononuclear cells. The kidneys from the group of rats which were treated concomitantly with gentamicin and melatonin at the dose of 5 mg/kg showed clearly that melatonin had a protective effect on the gentamicin induced structural changes. Namely, the areas of the kidney cortex enclosing tubular necrosis and degeneration were narrower; the changes of the tubules were of lesser extent, while the interstitial mononuclear infiltrate and oedema were less prominent. Grade 2 of changes was observed in 75% of animals, and grade 3 only in 25%. Histological analysis of kidneys of the rats which were beside gentamicin treated with melatonin at the dose of 20 mg/kg showed that the changes in this group were the mildest. The protective effect of melatonin was even more pronounced comparing to the previous group, grade 2 of changes was recorded in one half of the animals and grade 1 in the other half. The kidneys of the rats treated with melatonin at either a dose of 5 mg/kg or 20 mg/kg did not differ histologically significantly and all the kidney sections were graded with 0. We noticed a difference in the score obtained by the semiquantitative analysis between the group of rats treated only with gentamicin and the control group, as well as between the group treated with gentamicin and the groups treated concomitantly with gentamicin and melatonin, while the degree of melatonin protection was dose dependent and highly significant ( $p < 0.0005$ ). The study of Sener and al. [20], that pursued the protective action of melatonin on morpho-functional changes of the kidney caused by the administration of gentamicin, showed that the rats treated only with gentamicin had elevated values of urea and creatinine, which was followed by morphological changes in the sense of severe degeneration of proximal tubular epithelial cells and their microvilli. The pretreatment with melatonin reduced the development of the mentioned changes, which is in accordance to our results. Shifow and al. [21] were examining the effect of melatonin on the development of biochemical and histological changes caused by gentamicin. The

values of urea and creatinin were increased in comparison to the control group, and the histological analysis showed loss of tubular epithelial cells with an intense granular degeneration, with the changes comprising more than 50% of the renal cortex that is the total tubular necrosis was observed (grade 4). The animals treated with melatonin had both lower serum values of urea and creatinine and a lower grade of structural changes. The research conducted by Özbek and al. [22] showed that melatonin attenuates the gentamicin induced morpho-functional changes. While the rats treated with gentamicin were graded between 2 and 4, 75% of the rats treated with gentamicin and melatonin had the grade of changes 0. The serum levels of  $\gamma$ -glutamyl transferase and the level of proteins in the urine were increased, while the values of superoxide dismutase, glutathion peroxidase and catalase in tissues were decreased in the group treated with gentamicin. In the group treated with gentamicin and melatonin a protective effect was observed regarding all these parameters. Also the results of Lee and al. [23] are in agreement with our results and show that melatonin has a renoprotective effect on the oxidative damage induced by gentamicin. Lately, research has been done in order to examine the protective effect of melatonin on gentamicin induced structural alterations, and thereby heterogenous doses were used. Nevertheless, none of these studies had as its main interest several doses of melatonin with the aim of comparing the effects and locating the optimal protective dose, what we have tried to accomplish.

## CONCLUSION

Our results show that the gentamicin induced structural alterations of the proximal tubules can be abated with pre-treatment and the concomitant application of melatonin, and that the level of protection is dose-dependent.

## DECLARATION OF INTEREST

The authors state that there is no conflict of interest.

## REFERENCES

- [1] Ali BH, Al Za'abi M, Blunden G, Nemmar A. Experimental gentamicin nephrotoxicity and agents that modify it: a mini-review of recent research. *Basic Clin Pharmacol Toxicol* 2011; 109(4):225-232.
- [2] Kahlmeter G, Dahlager JI. Aminoglycoside toxicity - a review of clinical studies published between 1975 and 1982. *J Antimicrob Chemother.* 1984;13 Suppl A:9-22.
- [3] Mingeot-Leclercq MP, Tulkens PM. Aminoglycosides: nephrotoxicity. *Antimicrob Agents Chemother.* 1999;43(5):1003-1012.
- [4] Lopez-Novoa JM, Quiros Y, Vicente L, Morales AI, Lopez-Hernandez FJ. New insights into the mechanism of aminoglycoside nephrotoxicity: an integrative point of view. *Kidney Int* 2011; 79(1):33-45.
- [5] Martínez-Salgado C, Eleno N, Tavares P, Rodríguez-Barbero A, García-Criado J, Bolaños JP, et al. Involvement of reactive oxygen

- species on gentamicin-induced mesangial cell activation. *Kidney Int* 2002; 62(5):1682-1692.
- [6] Kacew S, Bergeron MG. Pathogenic factors in aminoglycoside induced nephrotoxicity. *Toxicol Lett* 1990; 51(3):241-59.
- [7] Leehey DJ, Braun BI, Tholl DA, Chung LS, Gross CA, Roback JA, et al. Can pharmacokinetic dosing decrease nephrotoxicity associated with aminoglycoside therapy. *J Am Soc Nephrol* 1993; 4(1):81-90.
- [8] Cuzzocrea S, Mazzon E, Dugo L, Serraino I, Di Paola R, Britti D, De Sarro A, Pierpaoli S, Caputi A, Masini E, Salvemini D. A role for superoxide in gentamicin-mediated nephropathy in rats. *Eur J Pharmacol.* 2002;450(1):67-76.
- [9] Banday AA, Farooq N, Priyamvada S, Yusufi AN, Khan F. Time dependent effects of gentamicin on the enzymes of carbohydrate metabolism, brush border membrane and oxidative stress in rat kidney tissues. *Life Sci* 2008; 82(9-10):450-459.
- [10] Kurcer Z, Oguz E, Ozbilge H, Baba F, Aksoy N, Celik H, et al. Melatonin protects from ischemia/reperfusion-induced renal injury in rats: this effect is not mediated by proinflammatory cytokines. *J Pineal Res* 2007; 43(2):172-178.
- [11] Parlakpınar H, Sahna E, Ozer MK, Ozugurlu F, Vardi N, Acet A. Physiological and pharmacological concentrations of melatonin protect against cisplatin-induced acute renal injury. *J Pineal Res* 2002; 33(3):161-166.
- [12] Nowak R, McMillen IC, Redman J, Short RV. The correlation between serum and salivary melatonin concentrations and urinary 6-hydroxymelatonin sulphate excretion rates: two non-invasive techniques for monitoring human circadian rhythmicity. *Clin Endocrinol (Oxf)* 1987; 27(4):445-452.
- [13] Sutherland ER, Martin RJ, Ellison MC, Kraft M. Immunomodulatory effects of melatonin in asthma. *Am J Respir Crit Care Med* 2002; 166(8):1055-1061.
- [14] Mayo JC, Sainz RM, Tan DX, Hardeland R, Leon J, Rodriguez C, et al. Anti-inflammatory actions of melatonin and its metabolites, N1-acetyl-N2-formyl-5-methoxykynuramine (AFMK) and N1-acetyl-5-methoxykynuramine (AMK), in macrophages. *J Neuroimmunol* 2005; 165(1-2):139-149.
- [15] Hardeland R. Antioxidative protection by melatonin: multiplicity of mechanisms from radical detoxification to radical avoidance. *Endocrine* 2005; 27:119-130.
- [16] Reiter RJ, Tan DX, Sainz RM, Mayo JC, Lopez-Burillo S. Melatonin: reducing the toxicity and increasing the efficacy of drugs. *J Pharm Pharmacol* 2002; 54(10):1299-1321.
- [17] Houghton DC, Plamp CE 3rd, DeFehr JM, Bennett WM, Porter G, Gilbert D. Gentamicin and tobramycin nephrotoxicity: a morphologic and functional comparison in the rat. *Am J Pathol* 1978; 93: 137-151.
- [18] Martínez-Salgado C, López-Hernández FJ, López-Novoa JM. Glomerular nephrotoxicity of aminoglycosides. *Toxicol Appl Pharmacol* 2007; 223(1):86-98.
- [19] Yazar E, Elmas M, Altunok V, Sivrikaya A, Oztekin E, Birdane YO. Effects of aminoglycoside antibiotics on renal antioxidants, malondialdehyde levels, and some serum biochemical parameters. *Can J Vet Res* 2003; 67(3):239-240.
- [20] Sener G, Sehirli AO, Altunbas HZ, Ersoy Y, Paskaloglu K, Arbak S, et al. Melatonin protects against gentamicin-induced nephrotoxicity in rats. *J Pineal Res* 2002; 32(4):231-236.
- [21] Shifow AA, Kumar KV, Naidu MU, Ratnakar KS. Melatonin, a pineal hormone with antioxidant property, protects against gentamicin-induced nephrotoxicity in rats. *Nephron* 2000; 85(2):167-174.
- [22] Ozbek E, Turkoz Y, Sahna E, Ozugurlu F, Mizrak B, Ozbek M. Melatonin administration prevents the nephrotoxicity induced by gentamicin. *BJU Int* 2000; 85(6):742-746.
- [23] Lee IC, Kim SH, Lee SM, Baek HS, Moon C, Kim SH, et al. Melatonin attenuates gentamicin-induced nephrotoxicity and oxidative stress in rats. *Arch Toxicol* 2012; 86(10):1527-1536.