

Eucalyptus globulus extract protects upon acetaminophen-induced kidney damages in male rat

Sabah Dhibi*, Sakhria Mbarki, Abdelfettah Elfeki, Najla Hfaiedh

Laboratory Animal Eco Physiology, Faculty of Science Sfax, Road Soukra km 3.5 - PB n° 1171-3000, Sfax, Tunisia.

ABSTRACT

Plants have historically been used in treating many diseases. *Eucalyptus globules*, a rich source of bioactive compounds, and have been shown to possess antioxidative properties. The purpose of this study, carried out on male Wistar rats, was to evaluate the beneficial effects of *Eucalyptus globulus* extract upon acetaminophen-induced damages in kidney. Our study is realized in the Department of Biology, Faculty of Sciences of Sfax (Tunisia). 32 Wistar male rats; were divided into 4 batches: a control group (n=8), a group of rats treated with acetaminophen (900mg/kg) by intraperitoneal injection during 4 days (n=8), a group receiving *Eucalyptus globulus* extract (130 mg of dry leaves /kg/day) in drinking water during 42 days after 2 hours of acetaminophen administration (during 4 days) (n=8) and group received only *Eucalyptus* (n=8) during 42 days. After 6 weeks, animals from each group were rapidly sacrificed by decapitation. Blood serum was obtained by centrifugation. Under our experimental conditions, acetaminophen poisoning resulted in an oxidative stress evidenced by statistically significant losses in the activities of catalase (CAT), superoxide-dismutase (SOD), glutathione-peroxidase (GPX) activities and an increase in lipids peroxidation level in renal tissue of acetaminophen-treated group compared with the control group. Acetaminophen also caused kidney damage as evident by statistically significant ($p<0.05$) increase in levels of creatinine and urea and decreased levels of uric acid and proteins in blood. Histological analysis demonstrated alteration of proximal tubules, atrophy of the glomerule and dilatation of urinary space. Previous administration of *plant* extract is found to alleviate this acetaminophen-induced damage.

© 2014 Association of Basic Medical Sciences of FB&H. All rights reserved

KEY WORDS: Acetaminophen, *eucalyptus globulus*, oxidative stress, kidney.

INTRODUCTION

Acetaminophen, also known as paracetamol, is a widely used pharmaceutical drug [1]. The popularity of this drug was based on its reputation for low toxicity [2]. Since its introduction in the 1950s, acetaminophen (N-acetyl p-aminophenol) has increased in use as an analgesic and antipyretic drug for the treatment of minor non inflammatory conditions and to alleviate the symptoms of more severe conditions such as chronic inflammatory arthritis and cancer [3, 4]. However, acute overdose is fairly common and can lead to potentially fatal renal damages in humans and experimental animals [5]. Current evidence suggests that oxidative stress with increased generation of reactive oxygen species, depletion of reduced glutathione (GSH) and lipid peroxidation play a crucial role in the development of acetaminophen-induced renal damage

[6]. Indeed, several antioxidants were proved efficient in protecting the kidney against the deleterious effect of acetaminophen overdose [7]. *Eucalyptus globulus* was proved successful in protecting different organs against oxidative in various experimental models [8]. Eucalyptus, a native plant of Australia, includes more than 700 species. Some of them, including *Eucalyptus globulus*, were introduced in Europe and North Africa where they are well acclimated to the Mediterranean shores [9]. Eucalyptus is mainly cultivated for the paper and cosmetic industries, while some of them are used in traditional medicine. Certain species of Eucalyptus are even used in modern medicine [10, 11]. Many researches were conducted on the medicinal properties of *Eucalyptus globulus*. The leaf extract or essential oil from the leaves of *Eucalyptus globulus* were reported to possess antifungal, antibacterial, anti-inflammatory, antioxidant, and antihelminthic properties [12]. In addition, the beneficial effect of Eucalyptus was demonstrated in rats given toxic doses of acetaminophen. However, the therapeutic effect of *Eucalyptus globulus* against acetaminophen-induced nephrotoxicity has not yet been studied. Therefore, the present study was conducted to evaluate the preventive effects of *Eucalyptus globulus* in renal damage induced by acute acetaminophen toxicity in rats. For this pur-

* Corresponding author: Sabah Dhibi,
Laboratory Animal Eco Physiology, Faculty of Science Sfax,
Road Soukra km 3.5 - PB n° 1171-3000 Sfax, Tunisia
Phone: +216 97015050
Fax: +216 76 211 026
e-mail: s.dhibi@yahoo.fr

Submitted: 2 Februar 2014 / Accepted: 29 March 2014

pose, levels of urea, creatinine, uric acid and proteins in blood serum were measured. The oxidant–antioxidant status of renal tissue was assessed by measuring TBARS (thiobarbituric acid reactive substances) level and activities of antioxidant enzymes SOD (superoxide dismutase), GPX (glutathione peroxidase), CAT (catalase). Pieces of kidney tissue were stained with hematoxylin and eosin for histological assessment.

MATERIALS AND METHODS

Preparation of the eucalyptus extract

The leaves of *Eucalyptus globulus* were collected from rural area around Zaghouan, Tunisia with the help of a botanist at the University of Gafsa. The plant material was powdered and macerated in 80% aqueous-ethanol for one week with occasional shaking. The extract was filtered and concentrated to dark green residue under reduced pressure on a rotary evaporator, with an approximate yield of 6%. The resulting solution was mixed with water to make 1 l and given to rat as drinking solution (thus containing the equivalent of 1 g dry leaves/l) given that the rats were drinking approximately 20ml /day. We may assume that each 160 g animal ingested about the equivalent of 130 mg dry *Eucalyptus* leaves /day.

Experimental design

Three months-old Wistar male rats, (were obtained from Ecophysiology laboratory animal, Sfax, Tunisia) about 160 g body weight, fed on 15% proteins food pellets (SICO, Sfax, Tunisia), were kept in a breeding farm, at 22°C, with a stable hygrometry, under constant photoperiod. Animals were treated according to the Tunisian code of practice for the Care and Use of Animals for Scientific Purposes. 32 rats were divided into 4 batches: (C) was the control group (n=8); (A) was a group of rats treated with acetaminophen (900mg/kg) by intraperitoneal injection for 4 days as proposed by Mladenovic et al. [13] (n=8); (A+E) was a group pre-treated with *Eucalyptus globulus* extract (130 mg dry leaves /kg) given in drinking water (42 days) [14]; and injected with acetaminophen as group A (n=8), (E) was a group pre-treated with *Eucalyptus globulus* as sole beverage during 42 days (n=8). After 6 weeks, animals from each group were rapidly sacrificed by decapitation in order to minimize the handling stress. Blood serum was obtained by centrifugation (1500 x g, 15 min, 4°C) and the kidney were removed, cleaned of fat and stored at -80°C until use.

Preparation of kidney extracts

1 g of the organ, cut out in small pieces, was homogenized in 2 ml of Tris-buffered-saline (pH 7.4) using an Ultra-Turrax grinder. The homogenate was then centrifuged during 15 min at 4°C. Supernatants were stored at -80°C until use.

Biochemical assays

Level of lipids peroxidation was measured as thiobarbituric acid reactive substances (TBARS), according to Yagi [15]. For the assay, 125 µl of supernatant (S1) were mixed with 175 µl of 20% trichloroacetic acid containing 1% butyl-hydroxytoluene and centrifuged (1000 x g, 10 min, 4°C). Then, 200 µl of supernatant (S2) was mixed with 40 µl of HCl (0.6 M) and 160 µl of thiobarbituric acid (0.72 mM) and the mixture was heated at 80°C for 10 min. The absorbance was measured at 530 nm. The amount of TBARS was calculated using an extinction coefficient of 156 mM⁻¹ cm⁻¹ and expressed as nmoles/mg protein. The total superoxide-dismutase (SOD) activity was determined by measuring its ability to inhibit the photoreduction of nitrobluetetrazolium (NBT) [16]. One unit of SOD represents the amount inhibiting the photoreduction of NBT by 50%. The activity was expressed as units/mg protein, at 25°C. Glutathione-peroxidase (GPX) activity was assayed according to the method of Flohe and Gunzler [17]. The activity at 25°C was expressed as µmoles of GSH oxidized/min/g protein. Catalase (CAT) activity was measured according to Aebi [18]. The reaction mixture (1 ml) contained 100 mM phosphate buffer (pH = 7), 100 mM H₂O₂ and 20 µl (about 1-1.5 mg of protein) of kidney. H₂O₂ decomposition was followed at 25°C by measuring the decrease in absorbance at 240 nm for 1 min. Enzyme activity was calculated using an extinction coefficient of 0.043 mM⁻¹ cm⁻¹ and expressed in international units (I.U.) i.e., in µmoles H₂O₂ destroyed /min/mg protein. Protein content in tissue extracts was determined according to Lowry's method [19] using bovine serum albumine as standard. The level of glucose, cholesterol, triglycerides and the activity of alkaline phosphatase, lactate dehydrogenase (LDH), aspartate amino transferase (AST), alanine amino transferase (ALT), creatinine, urea, uric acid and proteins in serum were determined by kit methods (Spinreact) (www.spinreact.com).

Statistical analysis

Two independent experiments, each carried out on 24 rats, were performed. Data were expressed as mean ± standard deviation (SD). Statistical significance was assessed by Student's test, *p* < 0.05 being considered statistically significant.

Microscopic examination

Kidneys were quickly excised and fixed in 10% formalin neutral buffer solution. The trimmed tissues were first washed with tap water followed by dehydration through a graded alcohol series and then passed through xylol and paraffin series before being embedded in paraffin. The paraffin blocks were cut into 5–6 µm sections stained with hematoxylin and eosin and examined under a light microscope [20].

RESULTS

Serum markers of kidney damage

Acetaminophen treatment induced severe kidney damages evidenced in serum by a significant increase of creatinine and urea levels and a significant decrease of uric acid and proteins (Table 1). When acetaminophen-treated rats were also treated with *Eucalyptus globulus*, all these biomarkers were kept to almost normal values.

TABLE 1. Effects of Acetaminophen, *Eucalyptus globulus* on creatinine ($\mu\text{mol/l}$), urea (mmol/l), uric acid ($\mu\text{mol/l}$) and protein (g/l) levels in blood.

Group	C	A	AE	E
Creatinine	19.4 \pm 1.21	30.33 \pm 2.13**	17.7 \pm 1.02*	20.61 \pm 1.09*
Urea	6.37 \pm 0.38	9.02 \pm 0.56**	7.73 \pm 0.92**	8.17 \pm 0.63**
Protein	65.7 \pm 1.28	61.33 \pm 1.25**	66.23 \pm 1.23**	64.32 \pm 1.06**
Uric acid	112.83 \pm 9.76	85.17 \pm 10.95**	103.65 \pm 7.21**	86 \pm 5.94**

Values are the mean of 6 measurements \pm SD.; ** $p \leq 0.01$, as compared to control group (C); * $p \leq 0.01$, as compared to treated group (A).

Oxidative damages

TBARS levels in renal tissues were increased in acetaminophen-treated rats as compared to controls by +114% (Figure 1). Administration of *Eucalyptus globulus* extract reduced these TBARS levels.

Antioxidant activities

Activities of enzymes which protect against oxidative stress, i.e., SOD, CAT and GPX were found to be respectively reduced by -69.09%, -52.62%, -55.7% in kidney of acetaminophen-treated rats, as compared to controls (Figure 1). These changes, revealing a failing defence against an oxidative stress, were largely corrected in animals treated by *Eucalyptus globulus*.

Histopathological study

Microscopic observation of the kidneys revealed in control group normal morphology of renal parenchyma with well-defined glomeruli and tubules. However, the acetaminophen administration in a single dose of 900 mg/

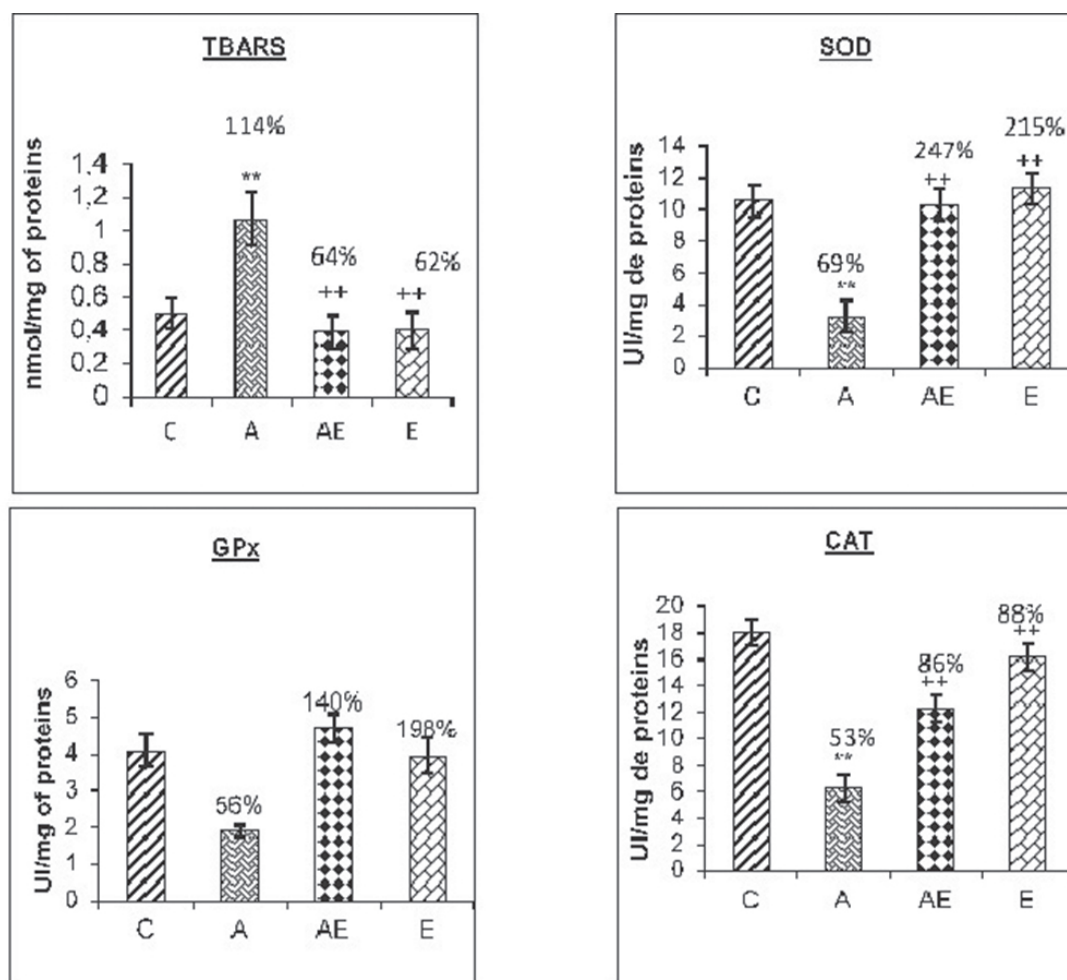


FIGURE 1. Levels of lipids peroxidation (expressed as TBARS, nmol/mg protein) and activities (I.U./mg protein) of superoxide dismutase (SOD), glutathione peroxidase (GPx) and catalase (CAT) in kidney after 6 weeks of treatment in controls (C), (A) Acetaminophen-treated rats, (AE) Acetaminophen-treated rats previously supplemented with *Eucalyptus globulus* extract, (E) rats supplemented with *Eucalyptus globulus* extract. Values are the mean of 6 measurements \pm SD.; * $p \leq 0.01$, compared to control group (C); ** $p \leq 0.01$, compared to treated group (A)

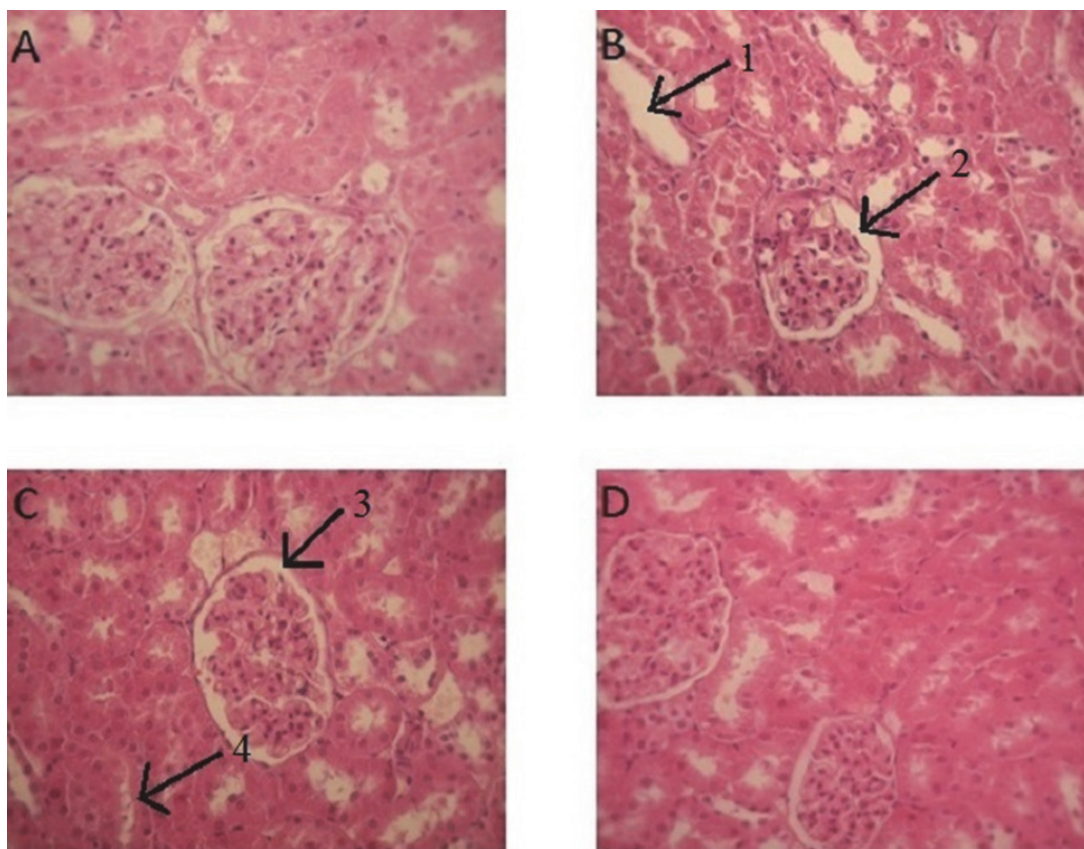


FIGURE 2. Photomicrographs of rat kidney (hematoxylin and eosin, 400x) from (A) control group showing normal renal architecture; (B) acetaminophen-treated group showing alterations of proximal tubules (1), atrophy of the glomerule and dilatation of urinary space (2); (C) *Eucalyptus globulus* plus acetaminophen group showing marked improvement in the histological picture with normal structure of the glomerule (3) and minimal tubules damage (4); (D) The normal kidney structure of rats treated with *Eucalyptus globulus* extract.

kg caused alteration of proximal tubules, atrophy of the glomerulus and dilatation of urinary space. *Eucalyptus globulus* treatment resulted in marked attenuation of the tubular damage with a better morphology of glomeruli as compared with the acetaminophen-treated group (Figure 2).

DISCUSSION

The aim of this study was to investigate the protective effect of *Eucalyptus globulus* on the acetaminophen-induced renal toxicity evidenced by biochemical measurements of oxidative damage and histopathological changes. In fact, our study clearly demonstrates that acute acetaminophen overdose 1) increases lipid peroxidation level, 2) weakens the antioxidant defense mechanisms leading to biochemical disturbances and 3) deteriorates the renal architecture as confirmed by histopathological observation. It has been suggested that acetaminophen-induced renal damage may be due to the metabolic formation of N-acetyl-p-benzoquinone-imine (NAPQI) which reacts with glutathione. This molecule is highly toxic and reacts with glutathione to form sulfur derivatives of cysteine and mer-

capturic acid before elimination in the urine [21, 22]. The supra-therapeutic doses saturate the conjugation pathways and the largest fraction of acetaminophen drift towards the cytochrome P-450 pathway leading to increased formation of toxic NAPQI. This depletes intracellular GSH and leads to alkylation of cellular macromolecules [23]. Depletion of glutathione may have two adverse consequences [24]. Previous studies, in agreement with the present one, have clearly demonstrated that acute acetaminophen overdose increases lipid peroxidation level and suppresses the antioxidant defence mechanisms in renal tissue. These results suggest that the intraperitoneal injection of acetaminophen caused disturbance in oxidant-antioxidant balance in order to disrupt redox homeostasis and develop an oxidative stress in kidney. As the increase in lipid peroxidation was associated with increase in ROS level and decreases in enzymatic antioxidants. It is likely that the renal peroxidative damage was a consequence of the damaging effects of ROS as well as failure of antioxidants to reestablish redox homeostasis [25, 26]. There are numerous reports showing that acetaminophen administration is closely followed by increase in lipid peroxidation products, leading to disturbance of cell membrane integrity [27].

In the present study, we found also that acetaminophen-induced renal damage by a reduction in glomerular filtration rate objective by an increased level of plasma, creatinine, urea concentration and total proteins [28]. Uric acid is decreased in blood of our rats treated. This compound, which is the final product of purine catabolism, also exerts antioxidative properties and may participate to the defence against an oxidative stress by scavenging ROS [29, 30]. Histopathological observations also substantiated the biochemical findings with improvements in renal histology after administration of plant extract [31]. Panatto et al [32] reported that the decrease in uric acid is related to the toxic effects of acetaminophen upon the nephron, which there by reduces its reabsorption and promotes its excretion. Other studies attribute the fall in the rate of plasma proteins caused by the administration of acetaminophen to the poor efficiency of damaged kidneys to filter and reabsorb the protein [33]. In our work, Eucalyptus treatment effectively protected against acetaminophen-induced nephrotoxicity by restoring almost normal activities of SOD, CAT and GPX. The attenuation of renal damage was confirmed by microscopic examination. These findings are in agreement with those reported earlier by others [34]. Previous studies showed that nutraceutical benefit of the extract of our plant have been attributed to the flavonoids, flavonols, and phenolics compounds [35, 36]. The localization of flavonoids in the membrane interiors and their resulting restrictions on the fluidity of membrane components could strictly hinder the diffusion of free radicals generated during acetaminophen oxidation, and there by decrease resulting damage effects [37, 38]. Therefore, Eucalyptus extract might play a key role in protection against acetaminophen intoxication by modulating the cellular GSH pool [39]. In this regard, we suggest that *Eucalyptus globulus* exerts an in vivo antioxidant activity against harmful reactive oxygen species generated following acetaminophen oxidation, and could therefore prevent kidney damage.

CONCLUSION

In conclusion, this report is the first study examining the effect of our extract on acetaminophen-induced impairment of antioxidant status and lipid peroxidation. Our results shows that could exert an in vivo antioxidant activity by hindering the lipid peroxidation process, restoring GSH depletion and reversing redox imbalance induced the toxicity of paracetamol.

DECLARATION OF INTEREST

The authors declare that there is no conflict of interest.

ACKNOWLEDGMENTS

This research was funded by the Tunisian Ministry of Higher Education and Scientific Research through Integrated Physiology Laboratory, Faculty of Science of Gafsa.

REFERENCES

- [1] Kumar G, Hota D, Nahar Saikia U, Pandhi P. Evaluation of analgesic efficacy, gastrotoxicity and nephrotoxicity of fixed-dose combinations of nonselective, preferential and selective cyclooxygenase inhibitors with paracetamol in rats. *Exp Toxicol Pathol* 2010; 62(6):653-662.
- [2] Lahouel M, Boulkour S, Segueni N, Fillastre JP. Effet protecteur des flavonoïdes contre la toxicité de la vinblastine, du cyclophosphamide et du paracétamol par inhibition de la peroxydation lipidique et augmentation du glutathion hépatique. *Pathologie Biologie* 2004; 52: 314-322.
- [3] Lane JE, Belson MG, Brown DK, Scheetz A. Chronic acetaminophen toxicity: a case report and review of the literature. *J Emerg Med*. 2002; 23(3): 253-256.
- [4] Larocque A, Bailey B. Evaluation of the risk of hepatotoxicity after acetaminophen ingestion: Where are we in 2010? *Réanimation*. 2010 ;19: 545-551.
- [5] Le Marec C. History of paracetamol. *The practitioner in Anesthesiology* 2005; 9 (4):321-328.
- [6] Liu Y-t, Lu B-n, Peng J-y. Hepatoprotective activity of the total flavonoids from *Rosa laevigata* Michx fruit in mice treated by acetaminophen. *Food Chemistry*. 2011; 125: 719-725.
- [7] Williams LJ, Pasco JA, Henry MJ, Sanders KM, Nicholson GC, Kotowicz MA. et al. Paracetamol (acetaminophen) use, fracture and bone mineral density. *Bone* 2011; 48(6):1277-81.
- [8] Gonzalez J, Cruz JM, Dominguez H, Parajo JC. Production of antioxidants from *Eucalyptus globulus* wood by solvent extraction of hemicellulose hydrolysates. *Food Chemistry* 2004; 84(2): 243-251.
- [9] Hasegawa T, Takano F, Takata T, Niiyama M, Ohta T. Bioactive monoterpene glycosides conjugated with gallic acid from the leaves of *Eucalyptus globulus*. *Phytochemistry*. 2008; 69:747-753.
- [10] Mason AP, Ibrahim K, Ingleby K, Munro CR, Wilson J. Mycorrhizal development and growth of inoculated *Eucalyptus globulus* (Labill) seedlings in wet and dry conditions in the glasshouse. *Forest Ecology and Management* 2000;128: 269-277.
- [11] Mulyaningsih S, Sporer F, Zimmermann S, Reichling J, Wink M. Synergistic properties of the terpenoids aromadendrene and 1,8-cineole from the essential oil of *Eucalyptus globulus* against antibiotic-susceptible and antibiotic-resistant pathogens. *Phyto-medicine* 2010;17: 1061-1066.
- [12] Nakhaee A, Bokaeian M, Saravani M, Farhangi A, Akbarzadeh A. Attenuation of oxidative stress in streptozotocin-induced diabetic rats by *Eucalyptus globulus*. *Indian Journal of Clinical Biochemistry*. 2009; 24(4): 419-425.
- [13] Mladenović D, Radosavljević T, Ninković M, Vučević D, Jesić-Vukićević R, Todorović V. Liver antioxidant capacity in the early phase of acute paracetamol-induced liver injury in mice. *Food Chem Toxicol*. 2009;47(4):866-870.
- [14] Soussi A, Hamden K, Marouane W, Bezzine S, Damak M, Murat JC, El Feki A. Oral administration of *Eucalyptus globulus* extract reduces the alloxan-induced oxidative stress in rats. *Chem Biol Interact* 2009;181(1): 71-76.
- [15] Yagi K. A simple fluorometric assay for lipoperoxide in blood plasma. *Biochem. Med* 1976;15: 212-216.
- [16] Sun Y, Oberley LW, Li Y. A simple method for clinical assay of superoxide dismutase. *Clin Chem* 1988; 34(3): 497-500.
- [17] Flohe L, Gunzler WA. Assays of glutathione peroxidase. *Methods Enzymol* 1984; 105: 114-121.

H. Aebi,

- [18] Aebi H. Catalase in Vitro. *Methods in Enzymology*, 1984; 105, 1984: 121-126.
- [19] Lowry OH, Rosebrough NJ, Farr AL, Randall RJ. Protein measurement with the Folin phenol reagent. *J Biol Chem* 1951;193: 265-275.
- [20] Gabe M. In vitro Techniques *Histology*.1967:225-229
- [21] Ghosh J, Das J, Manna PC, Sil PC. Acetaminophen induced renal injury via oxidative stress and TNF-production: therapeutic potential of arjunolic acid. *Toxicology* 2010; 268(1-2): 8-18.
- [22] Kumar G, Banu GS, Pappa PV, Sundararajan M, Pandian MR. Hepatoprotective activity of *Trianthema portulacastrum* L. against paracetamol and thioacetamide intoxication in albino rats. *J Ethnopharmacol*. 2004;92(1):37-40.
- [23] Srinivasan C, Williams WM, Ray MB, Chen TS. Prevention of acetaminophen-induced liver toxicity by 2(R,S)-n-propylthiazolidine-4(R)-carboxylic acid in mice. *Biochem Pharmacol*. 2001; 61(2):245-252.
- [24] Le Marec C. History of paracetamol. *The practitioner in Anesthesiology* 2005; 9 (4):321-328.
- [25] Abdel-Zaher AO, Abdel-Rahman MM, Hafez MM, Omran FM. Role of nitric oxide and reduced glutathione in the protective effects of aminoguanidine, gadolinium chloride and oleanolic acid against acetaminophen-induced hepatic and renal damage. *Toxicology*. 2007;234(1-2):124-134.
- [26] Fouad AA, Yacoubi MT, El-Bidawy MH. Therapeutic potential of hemin in acetaminophen nephrotoxicity in rats. *Environ Toxicol Pharmacol* 2009; 27 (2): 277-282.
- [27] Yousef MI, Omar AMS, El-Guendi IM, Abdelmegid LA. Potential protective effects of quercetin and curcumin on paracetamol-induced histological changes, oxidative stress, impaired liver and kidney functions and haematotoxicity in rat. *Food and Chemical Toxicology* 2010; 48(11): 3246-3261.
- [28] Ilic S, Drmic D, Zarkovic K, Kolenc D, Coric M, Brcic L. et al. High hepatotoxic dose of paracetamol produces generalized convulsions and brain damage in rats. A counteraction with the stable gastric pentadecapeptide BPC 157 (PL 14736). *J Physiol Pharmacol*. 2010;61(2):241-250.
- [29] Regoli F, Winston G. W. Quantification of total oxidant scavenging capacity of antioxidants for peroxynitrite peroxyl radicals and hydroxyl radicals. *Toxicol Appl Pharmacol* 1999;156 (2): 96-105.
- [30] Ames BN, Cathcart R, Schwiers E, Hochstein P. Uric acid provides an Antioxidant Defense in Humans Against oxidant and radical-caused aging and cancer: a Hypothesis. *Proc Natl Acad Sci U S A*. 1981; 78 (11):6858-6862.
- [31] Amakura Y, Umino Y, Tsuji S, Ito H, Hatano T, Yoshida, T. et al. Constituents and their antioxidative effects in eucalyptus leaf extract used as a natural food additive. *Food Chemistry*.2002;77:47-56
- [32] Panatto JP, Jeremias IC, Ferreira GK, Ramos AC, Rochi N, Gonçalves CL. et al. Inhibition of mitochondrial respiratory chain in the brain of rats after hepatic failure induced by acetaminophen. *Mol Cell Biochem*. 2011; 350(1-2):149-154.
- [33] Sugimoto K, Sakamoto S, Nakakawa K, Hayashi S, Harda N, Yamaji R, et al. Suppression of inducible nitric oxide synthase expression and amelioration of lipopolysaccharide-induced liver injury by polyphenolic compounds in *Eucalyptus globulus* leaf extract. *Food Chemistry* 2011; 125: 442-446.
- [34] Amakura Y, Yoshimura M, Sugimoto N, Yamazaki T, Yoshida T. Marker constituents of the natural antioxidant *Eucalyptus* leaf extract for the evaluation of food additives. *Biosci Biotechnol Biochem*. 2009;73(5):1060-1065.
- [35] Sugimoto K, Nakagawa K, Hayashi S, Yoshimura M, Amakura Y, Yoshida T. et al. Hydrolyzable tannins as antioxidants in the leaf extract of *Eucalyptus globulus* possessing tyrosinase and hyaluronidase inhibitory activities. *Food Sci. Technol. Res.* (2009) 15 (3): 331-336.
- [36] Georgé S, Brat P, Alter P, Amiot MJ. Rapid determination of polyphenols and vitamin C in plant-derived products. *J Agric Food Chem*. 2005; 53(5):1370-1373.
- [37] Gonzalez J, Cruz JM, Dominguez H, Parajo JC. Production of antioxidants from *Eucalyptus globulus* wood by solvent extraction of hemicellulose hydrolysates. *Food Chemistry* 2004; 84(2): 243-251.
- [38] Jurczuk M1, Brzóska MM, Moniuszko-Jakoniuk J, Gałazyn-Sidorczuk M, Kulikowska-Karpińska E. Antioxidant enzymes activity and lipid peroxidation in liver and kidney of rats exposed to cadmium and ethanol. *Food Chem Toxicol* 2004; 42(3): 429-438
- [39] Eyles A, Davies NW, Mitsunaga T, Mihara R, Mohammed C. Role of *Eucalyptus globulus* wound wood extractives: evidence of superoxide dismutase-like activity. *For. Path.* 2004; 34: 225-232.