

# Craniosynostosis - Recognition, clinical characteristics, and treatment

Nina Kajdic<sup>1,2</sup>, Peter Spazzapan<sup>2</sup>, Tomaz Velnar<sup>2\*</sup>

<sup>1</sup>Chair of Surgery, Medical Faculty, University of Ljubljana, Ljubljana, Slovenia, <sup>2</sup>Department of Neurosurgery, University Medical Centre Ljubljana, Ljubljana, Slovenia

## ABSTRACT

Craniosynostosis is a developmental craniofacial anomaly, resulting in impairment of brain development and abnormally shaped skull. The main cause of craniosynostosis is premature closure of one or more cranial sutures. It usually occurs as an isolated condition, but may also be associated with other malformations as part of complex syndromes. When left untreated, craniosynostosis can cause serious complications, such as developmental delay, facial abnormality, sensory, respiratory and neurological dysfunction, anomalies affecting the eye, and psychological disturbances. Thus, early diagnosis, expert surgical techniques, postoperative care, and adequate follow-up are of vital importance in treating craniosynostosis.

KEY WORDS: Craniosynostosis; development; classification; diagnosis; treatment

DOI: <http://dx.doi.org/10.17305/bjbms.2017.2083>

*Bosn J Basic Med Sci. 2018;18(2):110-116. © 2018 ABMSFBH*

## INTRODUCTION

During the embryonic development, the cranial vault develops from the mesenchymal tissue. It is first arranged as a capsular membrane around developing brain. Gradually, the outer mesenchymal layer is formed through the process of intramembranous ossification [1-5]. This intramembranous bone growth depends mainly on the direction of the forces that are defined by the growth of the brain. In the developmental period, the brain is surrounded by dural fibers, which are closely related and strongly attached to the sutural system. Calvarial sutures are formed during the embryonic development at the sites of approximation of the membranous bones and later represent the major sites of bone expansion. This process is a combination of i) deposition of osteoid at the sutural margins, ii) surface apposition and resorption (remodeling) of the bone, and iii) centrifugal displacement by the expanding brain [4-10].

The fusion of the sutures is mainly regulated by the dura mater, which interacts with the overlying tissues of the cranial vault. The dura mater provides many important regulators of growth, such as intercellular signals (for example, signaling

mediated by fibroblast growth factor [FGF] and transforming growth factor beta [TGF- $\beta$ ] have been suggested to be vital in this process), mechanical signals, and cells which undergo transformation and migrate to the sutures. This complex signaling cascade can be disrupted by a large number of genetic mutations, leading to an abnormal development of the cranial sutures [9-14]. Finally, this may result in a premature fusion of one or more sutures, which is called craniosynostosis [5,8].

## CRANIOSYNOSTOSIS

A craniosynostosis is a developmental anomaly which occurs as a consequence of abnormal and non-physiological sutural fusion. In a newborn, the membranous bones of the cranial vault are separated by the intervening sutures. Such arrangement enables the infant's skull to pass more easily through the birth canal and allows the compensatory growth of skull during the brain growth. When one or more sutures are prematurely closed, the compensatory growth starts perpendicular to the patent sutures since the brain still grows and expands in the direction of lower resistance. The result is an abnormally shaped skull and also, in more severe cases, increased intracranial pressure (ICP), as well as sensory, respiratory and neurological dysfunctions [1,8,9,15,16]. The prevalence of craniosynostosis is 1 in 2100-2500 births [17,18]. According to different studies, the cumulative prevalence of craniosynostoses has risen significantly with no obvious

\*Corresponding author: Tomaz Velnar, Department of Neurosurgery, University Medical Centre Ljubljana, Zaloska 7, 1000 Ljubljana, Slovenia. Phone: +386 1 522 3250. Fax: +386 1 522 22 18. E-mail: [tvelnar@hotmail.com](mailto:tvelnar@hotmail.com)

Submitted: 28 March 2017/Accepted: 17 April 2017

cause [19]. Both environmental factors (e.g., intrauterine fetal head constraint, abnormal position, oligohydramnios, prenatal exposures to teratogens, maternal smoking, and antiepileptic drugs such as valproic acid and phenytoin) and genes (single gene mutations, chromosome abnormalities, and polygenic background) may all be predisposing factors for the disease. Genetic causes account for approximately 20% of all craniosynostoses and are associated with many complications. Most of the genes linked to craniosynostosis are inherited in an autosomal dominant manner. However, in about 50% of the cases, new mutations may also occur [15,20-23]. Craniosynostoses are classified according to the sutures and the frequencies of these different types of craniosynostoses are as follows: Sagittal ( $\approx 60\%$ ), coronal ( $\approx 25\%$ ), metopic ( $\approx 15\%$ ), and lambdoid ( $\approx 2\%$ ) [1,24,25].

## CLASSIFICATION OF CRANIOSYNOSTOSES

Different classifications of craniosynostosis are used depending on the underlying mechanism, presence of other disorders, or number of fused sutures. For instance, if a craniosynostosis develops due to a primary defect of the ossification process it is called primary craniosynostosis. On the other hand, secondary craniosynostosis is the result of known systemic diseases with hematologic or metabolic dysfunction, such as rickets and hypothyroidism. Secondary craniosynostosis can also develop in newborns with microcephaly due to a failure of brain growth or following shunt placement in children with hydrocephalus. Furthermore, craniosynostosis can be classified into syndromic, e.g., as part of Apert, Crouzon, or Pfeiffer syndrome, and more commonly encountered, non-syndromic craniosynostosis, where it develops as an isolated disorder. Simple craniosynostosis is a term used when only one suture fuses prematurely, while complex craniosynostosis is used to describe a premature fusion of multiple sutures [8,26-30].

## DIAGNOSTICS

The diagnosis of a typical craniosynostosis is usually clinical and it is commonly diagnosed in the first year of life. The clinical assessment determines the following: i) whether a craniosynostosis is present, ii) whether there are additional features suggesting an associated syndrome, and iii) whether urgent or elective management is required [15,31]. At first, a careful medical history is obtained. To determine the etiology of craniosynostosis, the focus is on the family history of unusual head shapes, prenatal exposure to teratogens (e.g., valproic acid), and evidence of intrauterine constraint due to multiple pregnancy, primiparity, abnormal fetal position, or oligohydramnios. The history also includes possible complications of pregnancy, as

well as the evidence of achieved milestones during early life. The clinical examination is an important part where typical signs are looked for, especially possible congenital anomalies (e.g., a broad, radially deviated thumb in Pfeiffer syndrome or syndactyly in Apert syndrome), dysmorphic features of the face (hyper or hypotelorism, hypoplasia of midface, asymmetry, the position, shape and size of the ears), the skull shape from all directions, and the measurement of the head circumference for calculating the cephalic index (the ratio of maximum breadth to maximum length of the skull). Any sutural ridging, prominent blood vessels on the scalp, and the size, shape and tension of the fontanels should also be assessed. For evaluating ICP, ophthalmological examination is of great importance. In cases with increased ICP, papilledema is present [32]. When assessing the functional consequences of the condition, the most important clinical information includes possible airway obstruction, feeding difficulties, eye protection, and signs of increased ICP. Although, the diagnosis of craniosynostoses in typical cases can be made after clinical evaluation, many surgeons also confirm the diagnosis radiologically, especially when a surgical treatment is planned [15,33].

The computed tomography (CT) with three-dimensional (3D) reconstruction is considered the most complete and accurate imaging to diagnose craniosynostosis [34]. With this method, all sutures can be assessed for patency. In addition, the CT scanning allows evaluating the brain for possible structural abnormalities (e.g. ventriculomegaly, agenesis of the corpus callosum, and craniocerebral asymmetry). However, because of the radiation risk, this method should be indicated carefully [15,35].

In comparison to CT, plain radiography is less accurate in visualizing the cranial sutures. It is nevertheless a cost-effective method in infants with a low risk of craniosynostosis. One of its benefits is that general anesthesia is not required [33].

The magnetic resonance imaging (MRI) is an excellent technique for the evaluation of brain, albeit less accurate in visualizing the cranial sutures compared to CT. Generally, MRI is reserved for patients in which CT reveals cerebral anomalies [15,33]. Furthermore, it is an important imaging modality in combination with ultrasound (US) examination, especially in infants with suspected intracranial anomalies and associated complications of craniosynostosis (i.e., syndromic craniosynostoses). Recently, a novel MRI technique has been described, namely gradient- and spin-echo (GRASE) imaging. GRASE imaging can identify the cranial sutures similarly to other 2D imaging modalities. This type of MRI technique minimizes the soft tissue contrast and enhances the bone-soft tissue boundaries. It can therefore reveal normal cranial sutures as hyperintense signal distinguished from the signal void of the cranial bones [36].

US examination is a fast, low-cost, radiation-free method that requires no sedation. However, it is applicable only in cases

with open fontanelles. Standard ultrasonography of the calvarial sutures, in the absence of other craniofacial malformations, may be a feasible method for diagnosing simple, non-syndromic craniosynostosis *in utero* [37]. An important advantage of ultrasonography is the possibility to visualize and follow-up the cranial sutures on every examination, to obtain the best scan for measuring the skull and one or more prematurely fused sutures. In the experienced hands, US may be as reliable as CT [38]. The diagnosis is possible after the first trimester [39].

When a syndromic craniosynostosis is suspected, genetic testing is usually performed. Based on some results, genetic testing of FGF receptor genes (*FGFR3* and *FGFR2*) is advised. It is recommended to all patients presenting with coronal or multisuture synostosis, since these two types are often genetically determined [15,21]; the *FGFR2* and *FGFR3* as well as the genes for transcription factors (i.e., *TWIST* and *MSX2*) are the most frequently mutated genes in these disorders [5,6,8,21]. During the last decades, the understanding of molecular and genetic pathways associated with common forms of craniosynostosis has been increased. To date, mutations in 57 genes have been identified as an underlying cause of craniosynostosis. These genes and transcription factors are fundamental in the skull morphogenesis and, among others, include the FGF genes, *TWIST*, *MSX2*, bone morphogenetic protein (BMP) genes, *TGFB2*, *ERF* of ETS transcription factor family, *RUNX2*, *EFNB1*, *FAM20C*, and *LMX1B* gene [40-43].

## TYPICAL FEATURES OF VARIOUS TYPES OF CRANIOSYNOSTOSES

The typical features of various types of craniosynostoses are briefly described below (Table 1 and Figure 1).

### Scaphocephaly

In this type of synostosis, there is a premature fusion of the sagittal suture. It is commonly observed in premature infants. The head is typically elongated in the anterior-posterior direction and shortened in the bilateral direction. In some children, frontal bossing is present and the ridging of the sagittal suture is palpable. Boys are more frequently affected than girls, with a ratio of 3.5:1 [31,35,44,45].

### Anterior plagiocephaly

Anterior plagiocephaly results from a premature fusion of the coronal suture. On the affected side, the forehead is flattened because of arrested growth, and higher supraorbital margins form a characteristic sign on radiographs, known as the Harlequin sign. On the opposite side, the forehead is pushed forward. Additional findings include flat cheeks on the side of synostosis and nasal septum deviation towards the

**TABLE 1.** Clinical features of various types of craniosynostoses

Type of craniosynostosis	Typical characteristics
Scaphocephaly	<ul style="list-style-type: none"> <li>- Premature fusion of the sagittal suture</li> <li>- Elongated head in the anterior-posterior and shortened in the bilateral direction</li> <li>- Frontal bossing is present</li> <li>- Boys more frequently affected (3.5:1)</li> </ul>
Anterior plagiocephaly	<ul style="list-style-type: none"> <li>- Premature fusion of the coronal suture</li> <li>- Forehead flattened on the affected side</li> <li>- High supraorbital margins (Harlequin sign)</li> <li>- Forehead pushed forward on the unaffected side</li> <li>- Nasal septum deviation towards the normal side</li> <li>- More common in girls (2:1)</li> </ul>
Posterior plagiocephaly	<ul style="list-style-type: none"> <li>- Unilateral lambdoid synostosis</li> <li>- Frontal and occipital bossing</li> <li>- Ipsilateral ear and mastoid displaced downward</li> <li>- Head shape from above may resemble a trapezoid</li> </ul>
Positional plagiocephaly	<ul style="list-style-type: none"> <li>- Ipsilateral ear and forehead displaced anteriorly</li> <li>- Parallelogram shape of the head</li> <li>- Ipsilateral occipital flattening accompanied by contralateral occipital bossing</li> <li>- Male to female ratio 3:1</li> </ul>
Trigonocephaly	<ul style="list-style-type: none"> <li>- Premature fusion of the metopic suture</li> <li>- Occipital part is broad, forehead is narrow and pointed</li> <li>- Triangular shape of the head</li> <li>- Hypotelorism</li> <li>- Bilateral coronal synostosis</li> <li>- Short skull</li> </ul>
Brachycephaly	<ul style="list-style-type: none"> <li>- Forehead and occipital part flattened</li> <li>- Frontal bone prominent and elongated in vertical direction</li> <li>- Hypertelorism</li> <li>- Harlequin malformation of the orbits</li> </ul>

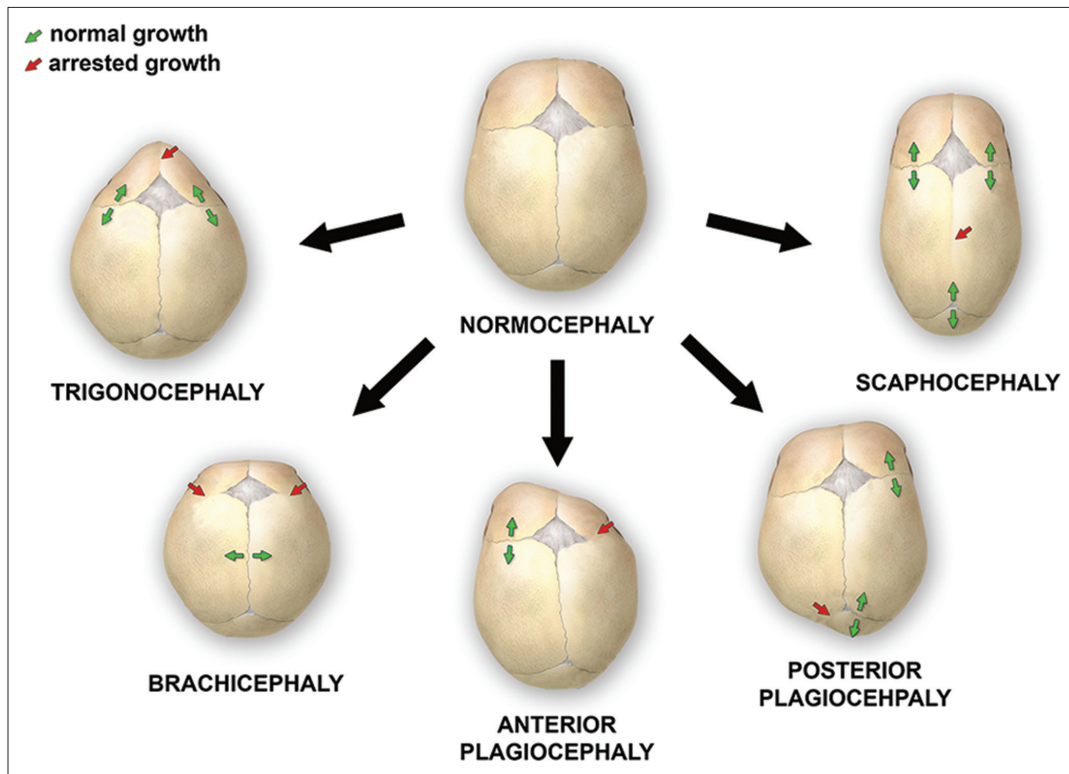
normal side. It is more common in girls than in boys (ratio 2:1). In the case when bicoronal fusion closes prematurely, the condition is called brachycephaly. Here, the head is typically shorter and wider [18,31,35,44-46].

### Posterior plagiocephaly

Posterior plagiocephaly is a unilateral lambdoid synostosis. Frontal and occipital bossing can develop contralateral to the affected side. The ipsilateral ear and mastoid can be displaced downward. In the majority of cases, the ear is also displaced in the anteroposterior direction. Clinically, the shape of the head from above can resemble a trapezoid [16,47,48].

### Positional plagiocephaly

It is essential yet sometimes difficult to distinguish between synostotic and positional plagiocephaly, which is more common. The latter is caused by repeated pressure to the same area before or after birth. The ipsilateral ear and forehead are usually displaced anteriorly, giving the head a parallelogram shape. The ipsilateral occipital flattening can be accompanied by a contralateral occipital bossing. The male-to-female ratio is 3:1. The effects of the positional plagiocephaly are primarily cosmetic and do not require surgical intervention [16,48].



**FIGURE 1.** Various deformations of the skull, associated with single-suture synostoses

The number of infants with this type of plagiocephaly has risen over the past several years, which has been associated with the “back to sleep” campaign to reduce the incidence of sudden infant death syndrome (SIDS). The presence of torticollis, prematurity, and gross motor delay can also predispose an infant to positional plagiocephaly [16,44,48,49].

### Trigonocephaly

Trigonocephaly results from a premature fusion of the metopic suture. The back of the head is broad and the forehead is narrow and pointed. When viewed from above, the forehead has a triangular shape. The orbits are abnormally close together (hypotelorism) [16,31,35].

### Brachycephaly

Brachycephaly is a bilateral coronal synostosis. As a result of the fused coronal suture, the skull is short. The forehead and occipital part are flattened and the frontal bone is prominent and elongated in a vertical direction. The orbits are abnormally separated (hypertelorism) and the Harlequin malformation of the orbits is seen on radiographs [33].

## INFLUENCE ON CHILD DEVELOPMENT

Craniosynostosis, especially the syndromic type, is often associated with a higher risk of impaired cognitive

development. This is due to restricted growth of the brain and a secondary deformation of the brain tissue caused by overgrown sutures and increased ICP. Many studies have examined the neurological status of children with craniosynostoses. Recently, a longitudinal study was launched, testing children at the start of their schooling. The study followed the neuropsychological development of 182 children with a simple form of craniosynostosis and of a control group, from early childhood to school age [50]. The results showed that, on average, children with a simple form of craniosynostosis exhibited a mild cognitive and academic deficit [50,51].

The developmental gap varies depending on the subtype of craniosynostosis. Children with metopic, unicoronal, or lambdoid synostosis have a higher likelihood of learning disabilities in comparison to children with sagittal synostosis. The highest variations have been found in the intelligence quotient and in computer skills. On the other hand, speech and reading were not significantly affected. In 58% of children, learning difficulties were not detected. Understanding the cognitive development of a child helps in determining the potential risk for developmental gap. With prompt identification and support programs, the cognitive and academic deficit may be prevented or at least considerably reduced [35,50,51].

## TREATMENT AND COMPLICATIONS

Similarly to the underlying causes and clinical characteristics, the treatment of craniosynostoses is also very

heterogeneous. Most of the uncomplicated, non-syndromic forms may be treated electively. On the other hand, some cases of the syndromic forms require urgent interventions. In severe cases, the focus is on maintaining the airway and nutritional support, eye protection and normal ICP [15].

The most important factors in determining the extent of surgery and surgical modality are the patient age and presentation [52]. Although the surgical treatment of craniosynostoses is most commonly used, the conservative approach may be adopted first, especially in patients with positional plagiocephaly and in cases in which unilateral synostosis is not very pronounced. Normally, the positional plagiocephaly may not require a treatment, although remodeling helmets are beneficial in some severe deformities. In addition, a minimally invasive approach, especially endoscopic suturectomy, may be used in some cases to correct the positional deformities surgically. The remodeling helmets can be used for very young patients (i.e., younger than 6 months) alone or in combination with suturectomy [52-54].

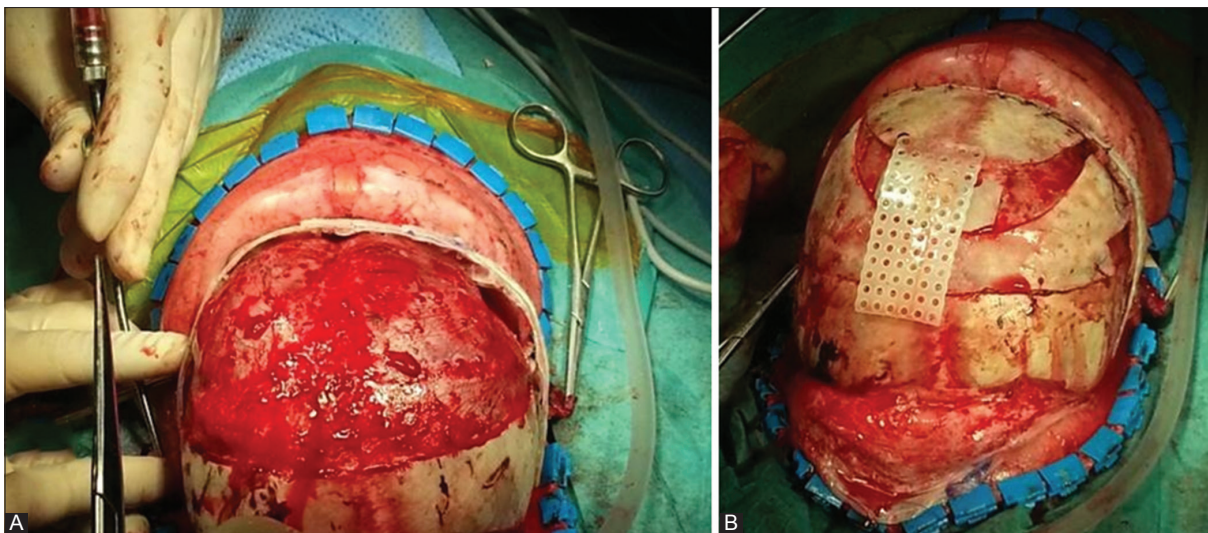
The main objectives are to achieve a normal brain development by providing sufficient space within the skull and a cosmetically acceptable appearance [16,31,35]. The optimal period for the operation remains a subject of debate and is considered to be between 6 and 12 months of age in the case when no signs of increased ICP are present [55]. In addition, this time period represents the most active phase of the brain and head development and is thus optimal for a surgical correction of the head shape and re-ossification of bone defects [56].

According to the clinical criteria and surgical capabilities, an open craniotomy and reconstruction or an endoscopic procedure are considered. After the operation, additional corrections with the helmets may be required and this usually lasts from 4 to 6 months. Both open surgery and endoscopy have

advantages and disadvantages. The endoscopic intervention is more appropriate until the age of 6 months. In that period, the cranial bones are still sufficiently flexible and can be manipulated by the endoscope. After 6 months, open surgery is preferred due to the stiffness of the bones. The advantage of endoscopic intervention is a shorter duration of surgery, less blood loss, and faster postoperative recovery. However, frequently, it should be combined with a postoperative use of a remodeling helmet and is suitable only for very young children. After 6 month of age, this technique is usually not effective. The upper limit is about 5-6 months of age and open surgery should be employed thereafter [52-54], because open surgery is more suitable for children older than 6 months as well as for those with complex or syndromic synostosis (Figure 2). Moreover, this approach still provides better possibilities of wide remodeling of the cranial vault and skull base [35,57].

The complications of surgical treatment include postoperative hyperthermia as the most common complication, next infections such as meningitis, subgaleal and subcutaneous hematoma, rupture of the dura mater, cerebrospinal fluid leakage, and blood loss. Several complications may occur in patients in which a reoperation is needed (Table 2). In general, the complications vary depending on the type of surgery. The endoscopically supported removal of cranial sutures is the intervention with minimal complications even though it does not allow a complete remodeling [58]. The mortality and morbidity rate is 0.1% and may reach up to 50% in the case of severe blood loss [59].

After surgery, the treatment is not completed. It is necessary to follow up the patients regularly and to control the growth and circumference of the head, observe possible symptoms of increased ICP and other potential complications. Only through regular follow-ups it is possible to detect prematurely



**FIGURE 2.** The surgical reconstruction of anterior plagiocephaly. During the operation, the child is placed in a supine position. A coronal skin incision is performed and after the periosteal dissection, the fused right coronal suture is recognized. The bone flap is removed and an extensive remodeling of the orbital bone and forehead follows (A). The final appearance of the skull after the completed surgical reconstruction, filling of bone defects, and their connection with resorbable plates (B).

**TABLE 2.** Possible complications of surgical treatment in craniosynostoses

Complications of surgery
Wound infection
Intraoperative bleeding
Postoperative hematoma (subgaleal, subdural)
Intraoperative/postoperative hyperthermia
Dural tear
Cerebrospinal fluid leak
Meningitis
Postoperative mortality: 2.6%
Postoperative morbidity: 12%

fusing cranial sutures in time and offer the child a reoperation; nevertheless, this is still performed only rarely [33].

## CONCLUSION

Craniosynostosis is a rare craniofacial anomaly which may lead to various complications, deformations, and neurological impairment during the child's development. Early identification and appropriate treatment are therefore vital. The aim of the surgical treatment is to enable the normal brain development and to achieve an acceptable cosmetic effect.

## DECLARATION OF INTERESTS

The authors declare no conflict of interests.

## REFERENCES

[1] Kjaer I. Neuro-osteology. *Crit Rev Oral Biol Med* 1998;9(2):224-44. <https://doi.org/10.1177/10454411980090020501>.

[2] Chai Y, Maxson RE Jr. Recent advances in craniofacial morphogenesis. *Dev Dyn* 2006;235(9):2353-75. <https://doi.org/10.1002/dvdy.20833>.

[3] Nah HD, Pacifici M, Gerstenfeld LC, Adams SL, Kirsch T. Transient chondrogenic phase in the intramembranous pathway during normal skeletal development. *J Bone Miner Res* 2000;15(3):522-33. <https://doi.org/10.1359/jbmr.2000.15.3.522>.

[4] Gong SG. Cranial neural crest: Migratory cell behaviour and regulatory networks. *Exp Cell Res* 2014;325(2):90-5. <https://doi.org/10.1016/j.yexcr.2014.03.015>.

[5] Kouskoura T, Fragou N, Alexiou M, John N, Sommer L, Graf D, et al. The genetic basis of craniofacial and dental abnormalities. *Schweiz Monatsschr Zahnmed* 2011;121(7-8):636-46.

[6] Twigg SR, Wilkie AO. A Genetic-pathophysiological framework for craniosynostosis. *Am J Hum Genet* 2015;97(3):359-77. <https://doi.org/10.1016/j.ajhg.2015.07.006>.

[7] Zhao X, Qu Z, Tickner J, Xu J, Dai K, Zhang X. The role of SATB2 in skeletogenesis and human disease. *Cytokine Growth Factor Rev* 2014;25(1):35-44. <https://doi.org/10.1016/j.cytogfr.2013.12.010>.

[8] Slater BJ, Lenton KA, Kwan MD, Gupta DM, Wan DC, Longaker MT. Cranial sutures: A brief review. *Plast Reconstr Surg* 2008;121(4):170e-8. <https://doi.org/10.1097/01.prs.0000304441.99483.97>.

[9] van Adrichem LN, Hoogeboom AJ, Wolvius EB. Genetics of craniofacial development. [Article in Dutch]. *Ned Tijdschr Tandheelkd* 2008;115(2):61-8.

[10] Morriss-Kay GM, Wilkie AO. Growth of the normal skull vault and

its alteration in craniosynostosis: Insights from human genetics and experimental studies. *J Anat* 2005;207(5):637-53. <https://doi.org/10.1111/j.1469-7580.2005.00475.x>.

[11] Ogle RC, Tholpady SS, McGlynn KA, Ogle RA. Regulation of cranial suture morphogenesis. *Cells Tissues Organs* 2004;176(1-3):54-66. <https://doi.org/10.1159/000075027>.

[12] Chim H, Manjila S, Cohen AR, Gosain AK. Molecular signaling in pathogenesis of craniosynostosis: The role of fibroblast growth factor and transforming growth factor-β. *Neurosurg Focus* 2011;31(2):E7. <https://doi.org/10.3171/2011.5.FOCUS1197>.

[13] Opperman LA. Cranial sutures as intramembranous bone growth sites. *Dev Dyn* 2000;219(4):472-85. [https://doi.org/10.1002/1097-0177\(2000\)9999:9999<::AID-DVDY1073>3.0.CO;2-F](https://doi.org/10.1002/1097-0177(2000)9999:9999<::AID-DVDY1073>3.0.CO;2-F).

[14] Delashaw JB, Persing JA, Jane JA. Cranial deformation in craniosynostosis. A new explanation. *Neurosurg Clin N Am* 1991;2(3):611-20.

[15] Johnson D, Wilkie AO. Craniosynostosis. *Eur J Human Genet* 2011;19(4):369-76. <https://doi.org/10.1038/ejhg.2010.235>.

[16] Sharma RK. Craniosynostosis. *Indian J Plast Surg* 2013;46(1):18-27. <https://doi.org/10.4103/0970-0358.113702>.

[17] Boulet SL, Rasmussen SA, Honein MA. A population-based study of craniosynostosis in metropolitan Atlanta, 1989-2003. *Am J Med Genet A* 2008;146A(8):984-91. <https://doi.org/10.1002/ajmg.a.32208>.

[18] Lajeunie E, Le Merrer M, Bonaiti-Pellie C, Marchac D, Renier D. Genetic study of nonsyndromic coronal craniosynostosis. *Am J Med Genet* 1995;55(4):500-4. <https://doi.org/10.1002/ajmg.1320550422>.

[19] Cornelissen M, Ottelander BD, Rizopoulos D, van der Hulst R, Mink van der Molen A, van der Horst C, et al. Increase of prevalence of craniosynostosis. *J Craniomaxillofac Surg* 2016;44(9):1273-9. <https://doi.org/10.1016/j.jcms.2016.07.007>.

[20] Sanchez-Lara PA, Carmichael SL, Graham JM Jr, Lammer EJ, Shaw GM, Ma C, et al. Fetal constraint as a potential risk factor for craniosynostosis. *Am J Med Genet A* 2010;152A(2):394-400. <https://doi.org/10.1002/ajmg.a.33246>.

[21] Wilkie AO, Byren JC, Hurst JA, Jayamohan J, Johnson D, Knight SJ, et al. Prevalence and complications of single-gene and chromosomal disorders in craniosynostosis. *Pediatrics* 2010;126(2):e391-400. <https://doi.org/10.1542/peds.2009-3491>.

[22] Carmichael SL, Ma C, Rasmussen SA, Honein MA, Lammer EJ, Shaw GM; National Birth Defects Prevention Study. Craniosynostosis and maternal smoking. *Birth Defects Res A Clin Mol Teratol* 2008;82(2):78-85. <https://doi.org/10.1002/bdra.20426>.

[23] Gedzelman E, Meador KJ. Antiepileptic drugs in women with epilepsy during pregnancy. *Ther Adv Drug Saf* 2012;3(2):71-87. <https://doi.org/10.1177/2042098611433192>.

[24] Kimonis V, Gold JA, Hoffman TL, Panchal J, Boyadjiev SA. Genetics of craniosynostosis. *Semin Pediatr Neurol* 2007;14(3):150-61. <https://doi.org/10.1016/j.spenn.2007.08.008>.

[25] Greenwood J, Flodman P, Osann K, Boyadjiev SA, Kimonis V. Familial incidence and associated symptoms in a population of individuals with nonsyndromic craniosynostosis. *Genet Med* 2014;16(4):302-10. <https://doi.org/10.1038/gim.2013.134>.

[26] Kang SG, Kang JK. Current and future perspectives in craniosynostosis. *J Korean Neurosurg Soc* 2016;59(3):247-9. <https://doi.org/10.3340/jkns.2016.59.3.247>.

[27] Saal HM. Genetic evaluation for craniofacial conditions. *Facial Plast Surg Clin North Am* 2016;24(4):405-25. <https://doi.org/10.1016/j.fsc.2016.06.001>.

[28] Ryoo HG, Kim SK, Cheon JE, Lee JY, Wang KC, Phi JH. Slit ventricle syndrome and early-onset secondary craniosynostosis in an infant. *Am J Case Rep* 2014;15:246-53. <https://doi.org/10.12659/AJCR.890590>.

[29] Cohen MM Jr. Sutural biology and the correlates of craniosynostosis. *Am J Med Genet* 1993;47(5):581-616. <https://doi.org/10.1002/ajmg.1320470507>.

- [30] Panchal J, Uttchin V. Management of craniosynostosis. *Plast Reconstr Surg* 2003;111(6):2032-48. <https://doi.org/10.1097/01.PRS.0000056839.94034.47>.
- [31] Esparza J, Hinojosa J, Garcia-Recuero I, Romance A, Pascual B, Martínez de Aragón A, et al. Surgical treatment of isolated and syndromic craniosynostosis. Results and complications in 283 consecutive cases. *Neurocirugía (Astur)* 2008;19(6):509-29. [https://doi.org/10.1016/S1130-1473\(08\)70201-X](https://doi.org/10.1016/S1130-1473(08)70201-X).
- [32] Governale LS. Craniosynostosis. *Pediatr Neurol* 2015;53(5):394-401. <https://doi.org/10.1016/j.pediatrneurol.2015.07.006>.
- [33] Zaleckas L, Neverauskienė A, Daugelavicius V, Sidlovskaitė-Baltakė D, Raugalas R, Vištartaitė B, et al. Diagnosis and treatment of craniosynostosis: Vilnius team experience. *Acta Med Litu* 2015;22(2):111-21. <https://doi.org/10.6001/actamedica.v22i2.3126>.
- [34] Tartaro A, Larici AR, Antonucci D, Merlino B, Colosimo C, Bonomo L. Optimization and diagnostic accuracy of computerized tomography with tridimensional spiral technique in the study of craniosynostosis. [Article in Italian]. *Radiol Med* 1998;96(1-2):10-7.
- [35] Burokas L. Craniosynostosis: Caring for infants and their families. *Crit Care Nurse* 2013;33(4):39-50. <https://doi.org/10.4037/ccn2013678>.
- [36] Kim HJ, Roh HG, Lee IW. Craniosynostosis: Updates in radiologic diagnosis. *J Korean Neurosurg Soc* 2016;59(3):219-26. <https://doi.org/10.3340/jkns.2016.59.3.219>.
- [37] Stelnicki EJ, Mooney MP, Losken HW, Zoldos J, Burrows AM, Kapucu R, et al. Ultrasonic prenatal diagnosis of coronal suture synostosis. *J Craniofac Surg* 1997;8(4):252-8. <https://doi.org/10.1097/00001665-199707000-00004>.
- [38] Accardi MC, Lo Magno E, Ermito S, Dinatale A, Cacciatore A, Cavaliere A, et al. Echotomography of craniosynostosis: Review of literature. *J Prenat Med* 2009;3(2):31-3.
- [39] Miller C, Losken HW, Towbin R, Bowen A, Mooney MP, Towbin A, et al. Ultrasound diagnosis of craniosynostosis. *Cleft Palate Craniofac J* 2002;39(1):73-80. [https://doi.org/10.1597/1545-1569\(2002\)039<0073:UDOC>2.0.CO;2](https://doi.org/10.1597/1545-1569(2002)039<0073:UDOC>2.0.CO;2).
- [40] Kosty J, Vogel TW. Insights into the development of molecular therapies for craniosynostosis. *Neurosurg Focus* 2015;38(5):E2. <https://doi.org/10.3171/2015.2.FOCUS155>.
- [41] Marie PJ, Kaabeche K, Guenou H. Roles of FGFR2 and twist in human craniosynostosis: Insights from genetic mutations in cranial osteoblasts. *Front Oral Biol* 2008;12:144-59. <https://doi.org/10.1159/000115036>.
- [42] Ciurea AV, Toader C. Genetics of craniosynostosis: Review of the literature. *J Med Life* 2009;2(1):5-17.
- [43] Katsianou MA, Adamopoulos C, Vastardis H, Basdra EK. Signaling mechanisms implicated in cranial sutures pathophysiology: Craniosynostosis. *BBA Clin* 2016;6:165-76. <https://doi.org/10.1016/j.bbacli.2016.04.006>.
- [44] Ursitti F, Fadda T, Papetti L, Pagnoni M, Nicita F, Iannetti G, et al. Evaluation and management of nonsyndromic craniosynostosis. *Acta Paediatr* 2011;100(9):1185-94. <https://doi.org/10.1111/j.1651-2227.2011.02299.x>.
- [45] Shillito J Jr, Matson DD. Craniosynostosis: A review of 519 surgical patients. *Pediatrics* 1968;41(4):829-53.
- [46] Spazzapan P, Bosnjak R, Velnar T. Craniofacial reconstruction of the skull in anterior plagiocephaly: A case report. *Br J Med Med Res* 2016;18(2):1-7. <https://doi.org/10.9734/BJMMR/2016/28075>.
- [47] Haas-Lude K, Wolff M, Will B, Bender B, Krimmel M. Clinical and imaging findings in children with non-syndromic lambdoid synostosis. *Eur J Pediatr* 2014;173(4):435-40. <https://doi.org/10.1007/s00431-013-2186-1>.
- [48] Mulliken JB, Vander Woude DL, Hansen M, LaBrie RA, Scott RM. Analysis of posterior plagiocephaly: Deformational versus synostotic. *Plast Reconstr Surg* 1999;103(2):371-80. <https://doi.org/10.1097/00006534-199902000-00003>.
- [49] Aarnivala H, Vuollo V, Harila V, Heikkinen T, Pirttiniemi P, Holmström L, et al. The course of positional cranial deformation from 3 to 12 months of age and associated risk factors: A follow-up with 3D imaging. *Eur J Pediatr* 2016;175(12):1893-903. <https://doi.org/10.1007/s00431-016-2773-z>.
- [50] Speltz ML, Collett BR, Wallace ER, Starr JR, Craddock MM, Buono L, et al. Intellectual and academic functioning of school-age children with single-suture craniosynostosis. *Pediatrics* 2015;135(3):e615-23. <https://doi.org/10.1542/peds.2014-1634>.
- [51] Starr JR, Collett BR, Gaither R, Kapp-Simon KA, Craddock MM, Cunningham ML, et al. Multicenter study of neurodevelopment in 3-year-old children with and without single-suture craniosynostosis. *Arch Pediatr Adolesc Med* 2012;166(6):536-42. <https://doi.org/10.1001/archpediatrics.2011.1800>.
- [52] Chong S, Wang KC, Phi JH, Lee JY, Kim SK. Minimally invasive suturectomy and postoperative helmet therapy: Advantages and limitations. *J Korean Neurosurg Soc* 2016;59(3):227-32. <https://doi.org/10.3340/jkns.2016.59.3.227>.
- [53] Rottgers SA, Lohani S, Proctor MR. Outcomes of endoscopic suturectomy with postoperative helmet therapy in bilateral coronal craniosynostosis. *J Neurosurg Pediatr* 2016;18(3):281-6. <https://doi.org/10.3171/2016.2.PEDS15693>.
- [54] Jimenez DF, Barone CM. Endoscopic technique for sagittal synostosis. *Childs Nerv Syst* 2012;28(9):1333-9. <https://doi.org/10.1007/s00381-012-1768-y>.
- [55] Utria AF, Munding GS, Bellamy JL, Zhou J, Ghasemzadeh A, Yang R, et al. The importance of timing in optimizing cranial vault remodelling in syndromic craniosynostosis. *Plast Reconstr Surg* 2015;135(4):1077-84. <https://doi.org/10.1097/PRS.0000000000001058>.
- [56] Garza RM, Khosla RK. Nonsyndromic craniosynostosis. *Semin Plast Surg* 2012;26(2):53-63. <https://doi.org/10.1055/s-0032-1320063>.
- [57] Honeycutt JH. Endoscopic-assisted craniosynostosis surgery. *Semin Plast Surg* 2014;28(3):144-9. <https://doi.org/10.1055/s-0034-1384810>.
- [58] Esparza J, Hinojosa J. Complications in the surgical treatment of craniosynostosis and craniofacial syndromes: Apropos of 306 transcranial procedures. *Childs Nerv Syst* 2008;24(12):1421-30. <https://doi.org/10.1007/s00381-008-0691-8>.
- [59] Czerwinski M, Hopper RA, Gruss J, Fearon JA. Major morbidity and mortality rates in craniofacial surgery: An analysis of 8101 major procedures. *Plast Reconstr Surg* 2010;126(1):181-6. <https://doi.org/10.1097/prs.obo13e3181da87df>.