

RESEARCH ARTICLE

# Histopathologic degenerative score as a predictor of minimal clinically important difference in pain and functionality following surgical treatment for disc herniation

Hakija Bečulić <sup>1,2</sup>, Emir Begagić <sup>3\*</sup>, Sabina Šegalo <sup>4</sup>, Fatima Juković-Bihorac <sup>5</sup>, Emsel Papić <sup>4</sup>, Ragib Pugnija <sup>2</sup>, Amina Džidić-Krivić <sup>6</sup>, Adem Nuhović <sup>7</sup>, Goran Lakičević <sup>8</sup>, Semir Vranić <sup>9</sup>, and Mirza Pojskić <sup>10</sup>

Lumbar disc herniation (LDH) often results in significant pain and disability, and histopathologic (HP) evaluation of intervertebral discs (IVDs) offers critical insights into treatment outcomes. This prospective observational study explores HP changes in IVDs and their association with clinical outcomes following surgical treatment for LDH. A cohort of 141 patients undergoing MRI-confirmed LDH surgery underwent HP evaluation using a semi-quantitative HP degeneration score (HDS). Preoperatively and at a six-month follow-up, the comprehensive clinical assessment included the Oswestry disability index (ODI) and visual analog scale (VAS), with a minimal clinically important difference (MCID) calculated from ODI and VAS. Results indicated significant associations between higher HDS and adverse clinical outcomes, including persistent pain and greater disability post-surgery. Specifically, an HDS  $\geq 7$  was predictive (OR = 6.25, 95% CI: 2.56–15.23) of disability outcomes measured with MCID-ODI (AUC: 0.692, 95% CI: 0.609–0.767,  $P < 0.001$ ), and HDS  $\geq 8$  was predictive (OR = 1.72, 95% CI: 1.04–2.77) of persistent pain measured with MCID-VAS (AUC = 0.628, 95% CI: 0.598–0.737,  $P = 0.008$ ), highlighting the diagnostic potential of HDS in assessing postoperative recovery. This study underscores the potential of HP evaluation using HDS to provide valuable insights into disease progression and outcomes in LDH patients, complementing conventional radiologic methods. The findings support the application of personalized treatment strategies based on HP findings while acknowledging challenges in interpretation and clinical implementation.

**Keywords:** Degenerative disc disease, histopathology, intervertebral disc displacement, pain measurement, treatment outcome.

## Introduction

The intervertebral disc (IVD) is a specific and vulnerable anatomical structure that is subject to degenerative processes and changes caused by various factors such as load, range of motion of the lumbar spine, and localization [1]. IVD degeneration (IDD) is the main cause of lower back pain, and one of the main causes of disability [2, 3]. The basis for the occurrence of degenerative disc disease is formed from birth and consists of a series of complex pathophysiologic processes that contribute to the development of degenerative spinal diseases such as lumbar disc herniation (LDH) [4, 5].

Specific changes in the biology of the IVD have been associated with LDH. These changes include decreased water retention in the *nucleus pulposus* (NP), increased content of type I

collagen in the NP and inner *annulus fibrosus* (AF), degradation of extracellular matrix components, activation of apoptosis, expression of matrix metalloproteinases, and activation of inflammatory pathways [6–8]. Of particular note is the link between inflammatory signaling and nerve pain in LDH, which underscores the immunologic privileging of IVD [9, 10]. As the NP protrudes into the epidural space, changes in vascular permeability and vasodilation promote the recruitment of immune cells and the release of inflammatory cytokines [11, 12]. Histological characteristics associated with IDD include increased cell density (chondrocyte proliferation), frequent granular changes, structural alterations (tears and fissures), and a significant accumulation of mucopolysaccharides (mucinous degeneration) with dark blue areas surrounding chondrocyte

<sup>1</sup>Department of Neurosurgery, Cantonal Hospital Zenica, Zenica, Bosnia and Herzegovina; <sup>2</sup>Department of Anatomy, School of Medicine, University of Zenica, Zenica, Bosnia and Herzegovina; <sup>3</sup>Department of General Medicine, School of Medicine, University of Zenica, Zenica, Bosnia and Herzegovina; <sup>4</sup>Department of Laboratory Technologies, Faculty of Health Studies, University of Sarajevo, Sarajevo, Bosnia and Herzegovina; <sup>5</sup>Department of Pathology, Cantonal Hospital Zenica, Zenica, Bosnia and Herzegovina; <sup>6</sup>Department of Neurology, Cantonal Hospital Zenica, Zenica, Bosnia and Herzegovina; <sup>7</sup>Department of General Medicine, School of Medicine, University of Sarajevo, Sarajevo, Bosnia and Herzegovina; <sup>8</sup>Department of Neurosurgery, University Hospital Mostar, Zenica, Bosnia and Herzegovina; <sup>9</sup>College of Medicine, QU Health, Qatar University, Doha, Qatar; <sup>10</sup>Department of Neurosurgery, University Hospital Marburg, Marburg, Germany.

\*Correspondence to Emir Begagić: [begagicem@gmail.com](mailto:begagicem@gmail.com)

DOI: 10.17305/bb.2024.10877

© 2025 Bečulić et al. This article is available under a Creative Commons License (Attribution 4.0 International, as described at <https://creativecommons.org/licenses/by/4.0/>).

clusters [13]. These parameters formed the basis for the development of a semiquantitative HP degenerative score (HDS) by Boos et al. [14]. Despite being explored in a limited number of studies, histologic analysis of IVD offers valuable insights into the pathophysiological mechanisms and histopathologic (HP) changes that are often not detectable by conventional radiologic methods [15].

This study investigates how HP changes in IVDs correlate with clinical findings and outcomes following surgical treatment for LDH. It explores the relationship between microscopic alterations in disc tissues and post-surgical pain management and functional recovery. By analyzing these HP findings, the study evaluates their prognostic significance and potential to guide personalized treatment approaches for LDH patients undergoing surgery. The research aims to enhance prognostic tools beyond conventional diagnostic methods like magnetic resonance imaging (MRI), providing deeper insights into the underlying mechanisms of LDH to optimize patient outcomes.

## Materials and methods

### Study design, sample size, and subjects

This prospective observational study included patients who had undergone surgery for a hernia of the IVD at the Department of Neurosurgery of the Cantonal Hospital Zenica (Bosnia and Herzegovina) between July 2022 and June 2023. Patients were included if they required surgery due to LDH, were older than 18 years, were residents of the Zenica-Doboj Canton (ZDC), and had MRI records and data available. Patients were excluded if they had lumbar spine trauma, spondylolisthesis, recurrent IVD prolapse, failed back surgery syndrome, or an infection.

The sample size was calculated using the prevalence of patients who underwent surgical treatment during 2022. The total number of patients with indications for surgical intervention was 143 in the ZDC, Bosnia and Herzegovina. According to the Federal Institute of Statistics in 2022, the total population in the ZDC was 364,433 (<https://fzs.ba/>). The sample size was determined using the following equation [16]:

$$n = \frac{NZ^2p(1-p)}{(N-1)E^2 + Z^2p(1-p)} \quad (1)$$

where  $n$  represents the sample size,  $N$  is the total population,  $Z$  is the value for a 95% confidence level ( $Z = 1.96$ ),  $p$  is the estimated prevalence rate in the population ( $p \approx 0.000395$ ), and  $E$  represents the desired precision ( $E = 0.00005$ ). Based on the calculation, the representative sample size is 141 patients.

### Data collection

The dataset from medical records included demographic, occupational, lifestyle, and clinical variables. Gender was categorized as male or female. Age was recorded both continuously and categorically, with groups formed using the median age. Education was categorized into elementary, secondary, and college, and living environments into urban and rural. Vertebral bodies (L2/L3, L3/L4, L4/L5, L5/S1) were examined via MRI (Magnetom Avanto 1.5 T, Siemens, Erlangen, Germany). Anthropometric measures included height (meters), weight

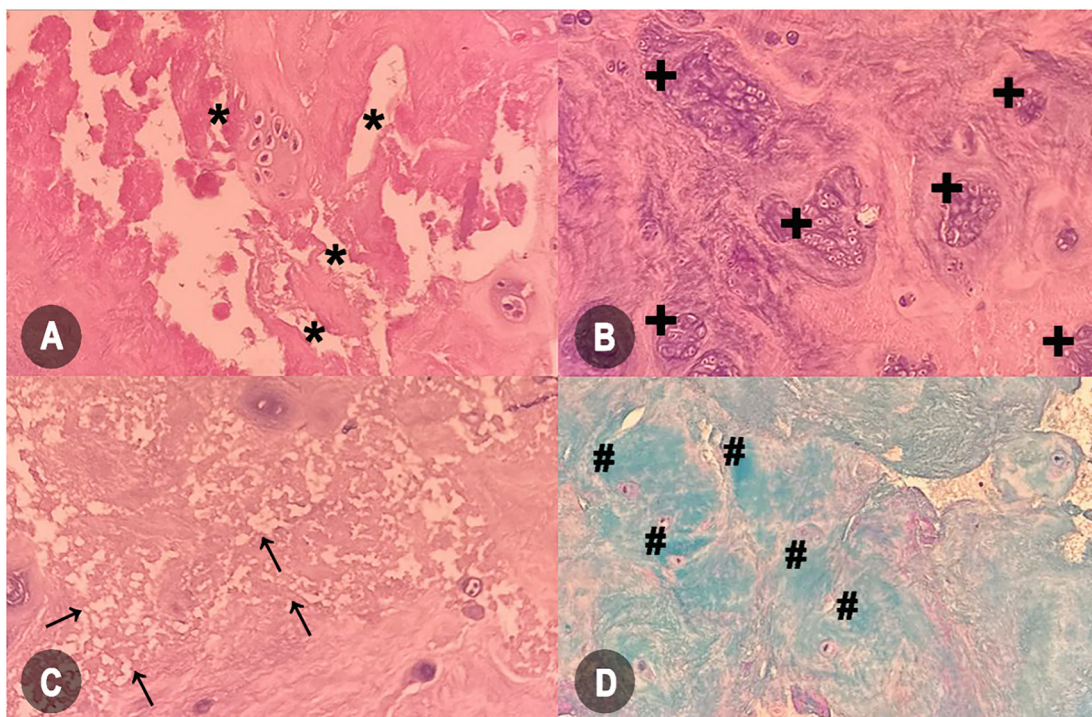
(kilograms), and body mass index (BMI) in  $\text{kg}/\text{m}^2$ . BMI categories were defined as underweight ( $<18.5$ ), normal weight ( $18.5-24.9$ ), overweight ( $25-29.9$ ), and obese ( $\geq 30$ ) [17]. Before surgery, workplace data and occupational risks were gathered from anamnestic records, including details on shift work, overtime, employment sector, income, employment duration, tobacco and alcohol use, physical activity, and sleep duration. Comorbidities included type 1 or type 2 diabetes, hypertension, depression, disc herniation at another level, lumbar spinal stenosis, or autoimmune conditions, confirmed by a specialist physician.

### HP analysis

A posterior lumbar discectomy was performed to remove extruded or sequestered disc material (DM) from the patient. The excised DM was preserved and sent for HP examination. For analysis, the specimen was placed in a 4% formaldehyde solution with a pH of 7.4 for 12–16 h. Thin sections ( $4 \mu\text{m}$ ) were prepared from the formalin-fixed material, embedded in paraffin, placed on adequate glass slides, and stained with hematoxylin and eosin (H&E) and Alcian blue to determine the changes in tissue morphology using a semiquantitative method, the HDS [14]. For each subscale, values were assigned as follows (Figure 1): cell density (chondrocyte proliferation) with scores ranging from 0 (no evidence of proliferation) to 5 (presence of significant clusters  $>15$  cells); structural changes (tears and clefts) with scores ranging from 0 (absence) to 4 (evidence of scarring or tissue defects); granular changes and mucosal degeneration with scores ranging from 0 (absence) to 3 (marked presence). The evaluation provided information on the degree of degeneration on an HDS scale of 0–15, calculated by summing the values of the subscales.

### Clinical evaluation and follow-up

The clinical evaluation included preoperative and follow-up assessments of pain intensity, motor and sensory function, and disability due to disc herniation. Follow-up was conducted six months ( $\pm 15$  days) post-surgery. Pain was measured with the visual analog scale (VAS) from 0 to 10, where higher scores indicate greater pain intensity [18]. Motor function (MF) was assessed using the Medical Research Council Muscle Power Scale (MRC-MPS) with the following ratings: 0 - no visible contraction, 1 - visible minimal contraction, 2 - movement without overcoming gravity, 3 - active movement overcoming gravity, 4 - movement overcoming some resistance, and 5 - normal strength [19]. Sensory impairment was assessed using a sensitivity assessment scale (SAS) for L1-S3 dermatomes with values ranging from 0 (absent) to 2 (normal) [20]. Disability caused by disc herniation was evaluated using the Oswestry disability index (ODI) scale, consisting of ten domains rated on a Likert-type scale from 0 to 5. The total score ranges from 0 to 50, with a higher score indicating greater disability among the patients under investigation [21]. Pain levels were gauged using VAS, ranging from 0 to 10, where higher scores denoted more intense pain. The minimal clinically important difference (MCID) system, established by Power et al. [22], was employed to assess diagnostic precision. This system identified a decrease



**Figure 1. Microscopic features illustrating intervertebral disc degeneration.** (A) Structural modifications marked by tears and clefts (marked with \*); (B) Increase in cell density, signifying chondrocyte proliferation granular alterations (marked with +); (C) Granular alterations (marked with arrows); (D) Significant escalation in acid mucopolysaccharides, indicating mucous degeneration (marked with #) (Images A, B, and C are hematoxylin and eosin stained; image D is Alcian blue stain; magnification 20 $\times$ ).

of 22 points in ODI scores post-surgery compared to preoperative levels as indicative of a positive outcome. MCID was similarly computed for VAS values, with a reduction of 2.5 points signifying a beneficial result [23].

#### Ethical statement

Ethical approval was obtained from the Ethics Committee of the Zenica Cantonal Hospital (number 00-03-35-915-8/22). All patients were informed about the purpose and significance of the study and signed a written informed consent form. The personal data of the patients were protected, and the principles of the Declaration of Helsinki were followed.

#### Statistical analysis

The Statistical Package for the Social Sciences (SPSS) software (IBM Inc., USA, version 27.0) and MedCalc (MedCalc Software, Ostend, Belgium, version 22) were used for the statistical analysis. Deviations from a normal distribution were assessed using the Kolmogorov–Smirnov test. Significant differences in categorical variables were determined using the chi-square test, while the Wilcoxon test was used for continuous variables. The influence of the above variables on the degree of degeneration measured by HDS was assessed by multivariate or logistic regression analysis with odds ratio (OR) with a 95% confidence interval (CI). For continuous variables, linear regression was performed. Diagnostic accuracy was evaluated using receiver operating characteristic (ROC) curve analysis, specifically through the calculation of the area under the curve (AUC). Statistical significance was set at  $P \leq 0.05$ .

## Results

The dataset included 83 men (58.9%) and 58 women (41.1%) with a median age of 44 years (IQR: 37–55). A majority of patients (52.5%) were older than 44 years. Educationally, 18.4% had completed primary school, 53.9% secondary school, and 27.7% college. Geographically, 44.0% were from urban areas and 56.0% from rural areas. The median height was 1.8 m (IQR: 1.7–1.8), weight was 80.5 kg (IQR: 66.6–89.8), and BMI was 25.0 kg/m<sup>2</sup> (IQR: 23–28). Among them, 50.1% were of normal weight, 40.4% were overweight, and 9.2% were obese. Disc herniation occurred in 22.0% at L3/L4, 46.8% at L4/L5, and 31.2% at L5/S1.

HP analysis indicated chondrocyte proliferation (median: 3, IQR: 2–3), tissue tears and clefts (median: 1, IQR: 1–2), granular changes, and mucous degeneration (median: 1, IQR: 0–1), and an HDS median of 6 (IQR: 5–9) (Figure 2). Males (OR = 2.21, 95% CI: 1.78–2.99,  $P < 0.001$ ) and patients under 44 years (OR = 1.97, 95% CI: 1.59–2.45,  $P < 0.001$ ) had higher odds of HDS. Greater height ( $\beta = 0.01$ , 95% CI: 0.00–0.01,  $P = 0.002$ ), weight ( $\beta = 0.11$ , 95% CI: 0.09–0.14,  $P < 0.001$ ), and BMI ( $\beta = 0.98$ , 95% CI: 0.83–1.14,  $P < 0.001$ ) were linked to higher HDS scores. Overweight (OR = 2.19, 95% CI: 1.69–2.83,  $P < 0.001$ ) and obesity (OR = 2.24, 95% CI: 1.50–3.34,  $P < 0.001$ ) were also associated with increased odds of HDS. LDH at L4/L5 (OR = 2.54, 95% CI: 1.69–3.82,  $P < 0.001$ ) and L5/S1 (OR = 1.55, 95% CI: 1.27–1.89,  $P < 0.001$ ) showed significant associations with HDS (Table 1).

The median MF scores increased from 3 (IQR: 3–4) to 4 (IQR: 3–5) ( $P = 0.001$ ), and sensitive function (SF) scores from 1 (IQR: 1–2) to 2 (IQR: 1–2) ( $P = 0.003$ ). MF scores showed a strong



Table 1. Baseline characteristics of the cohort

Variable		N (%) or Median (Q1:Q3)	Regression analysis (HDS)	
			OR or $\beta$ (95% CI)	P value
Gender	Men	83 (58.9)	2.21 (1.78; 2.99)	<0.001
	Women	58 (41.1)	Reference	-
Age (years)		47.0 (37.0–55.0)	0.15 (0.12; 0.18)*	<0.001
Age (categories)	$\geq 44$	74 (52.5)	Reference	-
	<44	67 (47.5)	1.97 (1.59; 2.45)	<0.001
Education	Primary school	26 (18.4)	1.53 (0.76; 1.90)	0.249
	Secondary school	76 (53.9)	1.23 (0.51; 1.77)	0.457
	College/Faculty	39 (27.7)	Reference	-
Life environment	Urban	62 (44.0)	1.43 (0.84; 1.64)	0.365
	Rural	79 (56.0)	Reference	-
Height (m)		1.8 (1.7–1.8)	0.01 (0.00; 0.01)*	0.002
Weight (kg)		80.5 (66.6–89.8)	0.11 (0.09; 0.14)*	<0.001
BMI (kg/m <sup>2</sup> )		25.0 (23.0–28.0)	0.98 (0.83; 1.14)*	<0.001
BMI (categories)	Normal weight	71 (50.1)	Reference	-
	Overweight	57 (40.4)	2.19 (1.69; 2.83)	<0.001
	Obesity	13 (9.2)	2.24 (1.50; 3.34)	<0.001
Affected vertebral level	L3/L4	31 (22.0)	Reference	-
	L4/L5	66 (46.8)	2.54 (1.69; 3.82)	<0.001
	L5/S1	44 (31.2)	1.55 (1.27; 1.89)	<0.001

\*:  $\beta$  coefficients along with 95% CIs (derived from linear regression analysis), while the remaining values not marked with “\*” represent OR with 95% CIs obtained through logistic regression analysis or multinomial regression analysis. HDS: Histopathological degenerative score; BMI: Body mass index.

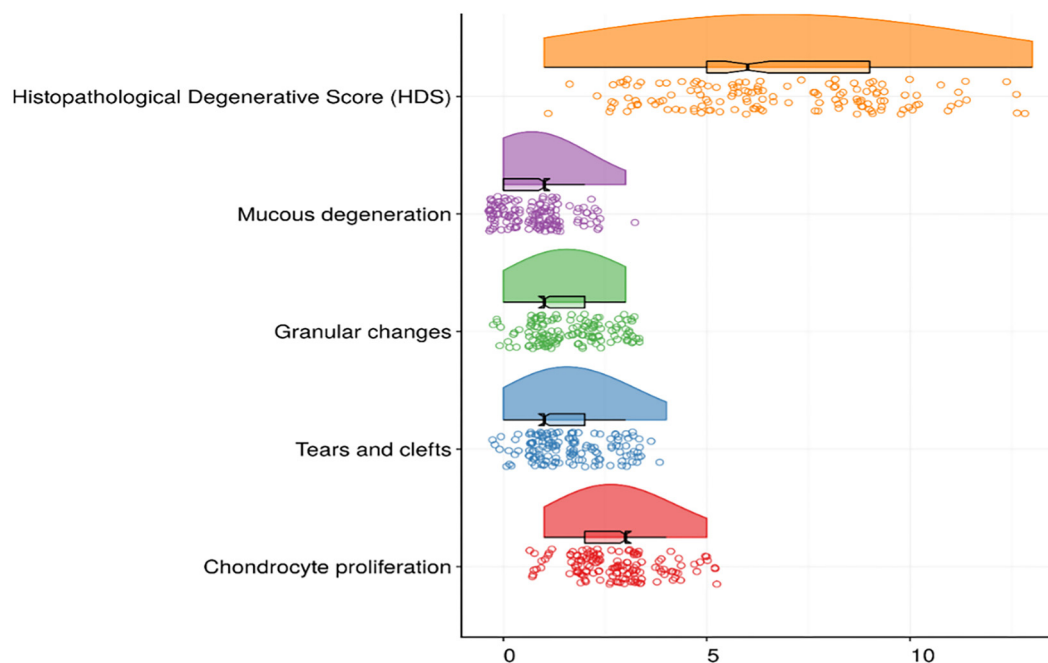
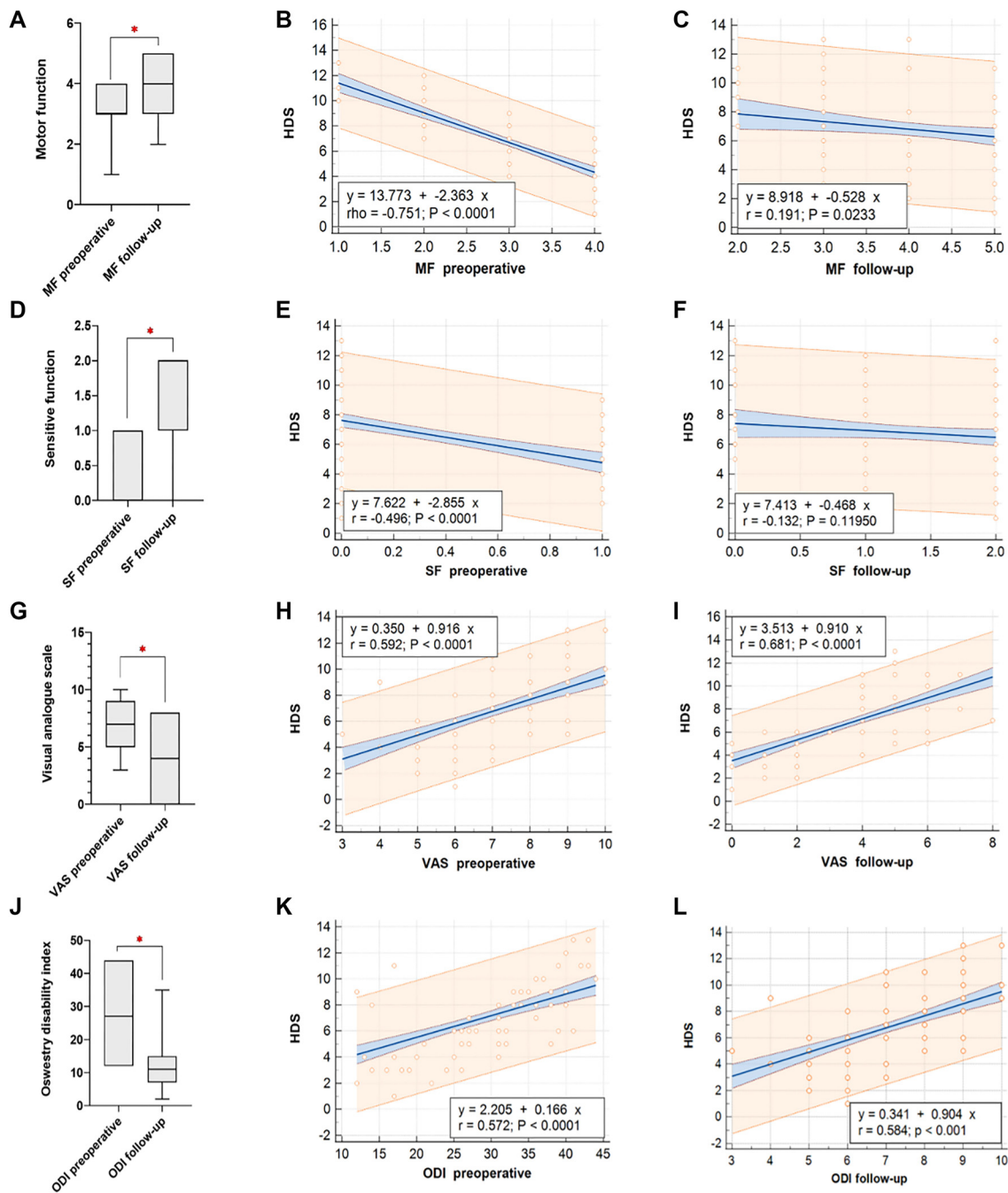


Figure 2. Results of histopathologic analysis of intervertebral discs with median values of domains and total histopathological degenerative score.

negative correlation with HDS preoperatively ( $r = -0.751$ ,  $P < 0.001$ ) (Figure 3B), while SF scores demonstrated a moderate negative correlation ( $r = -0.469$ ,  $P < 0.001$ ) (Figure 3E). Both MF and SF correlations with HDS decreased in follow-up

examinations (Figure 3C and 3F). VAS decreased from a median of 7 (IQR: 5–9) preoperatively to 4 (IQR: 2–5) postoperatively ( $P < 0.001$ ) (Figure 3G). ODI decreased from a median of 27 (IQR: 19–35) to 11 (IQR: 7–15) ( $P < 0.001$ ) (Figure 3J).



**Figure 3.** (A) Comparative analysis of MF, (D) SF, (G) VAS, (J) ODI both before surgery and during subsequent follow-up evaluations. Correlations between the Health-related Quality of Life, Determination score (HDS) and preoperative MF are depicted in (B), while (C) depicts correlations during the follow-up MF assessment. The correlation between SF preoperatively and at follow-up is displayed in (E) and (F). (H) and (I) represent the correlation of VAS scores with preoperative and follow-up assessments respectively. Lastly, (K) and (L) present the correlation between ODI scores and HDS both before surgery and during follow-up evaluations. MF: Motor function; SF: Sensitive function; VAS: Visual analogue scale; ODI: Oswestry disability index; HDS: HP degeneration score.

Higher preoperative VAS scores were associated with increased follow-up HDS ( $r = 0.592$ ,  $P < 0.001$ ), as were higher ODI scores ( $r = 0.584$ ,  $P < 0.001$ ) (Figure 3L).

Work in shifts ( $B = 0.757$ ,  $P = 0.012$ ), longer employment durations ( $B = 1.203$ ,  $P < 0.001$ ), tobacco consumption ( $B = 2.911$ ,  $P < 0.001$ ), and physical activity ( $B = -0.919$ ,  $P = 0.005$ ) were associated with HDS (Table 2). Factors such

as diabetes mellitus ( $B = 1.341$ ,  $P = 0.028$ ), hypertension ( $B = 1.502$ ,  $P < 0.001$ ), depression ( $B = 1.590$ ,  $P = 0.038$ ), and spinal lumbar stenosis ( $B = 2.349$ ,  $P < 0.001$ ) were associated with higher HDS scores (Table 3).

In the ODI-measured MCID, 76.6% of patients showed improvement at six months. Participants who improved had a median HDS score of 9.0 (95% CI: 9.0–11.0), while those who did

**Table 2. Factors related to occupation, behavior, and habits**

Variable		N (%)	Multivariate regression analysis (HDS)	
			$\beta$ coefficient (95% CI)	P value
Work in shifts	No	44 (31.2)	0.757 (0.166; 1.348)	0.012
	Yes	97 (68.8)		
Overtime work	No	66 (46.8)	0.504 (−0.047; 1.060)	0.073
	Yes	75 (53.2)		
Sector	Public	78 (55.3)	0.521 (−0.018; 1.060)	0.058
	Private or self-employed	63 (44.7)		
Income	Below average	75 (53.2)	−0.472 (−1.030; 0.867)	0.097
	Above average	66 (46.8)		
Length of employment (years)	<5	26 (18.4)	1.203 (0.752; 1.654)	<0.001
	6–15	76 (53.9)		
	>16	39 (27.7)		
Tobacco consumption	No	70 (49.6)	2.911 (2.195; 3.626)	<0.001
	Yes	71 (50.4)		
Alcohol consumption	No	55 (39.0)	0.107 (−0.426; 0.639)	0.693
	Yes	86 (61.0)		
Physical activity	No	102 (72.3)	−0.929 (−1.572; −0.286)	0.005
	Yes	39 (27.7)		
Sleep (hours)	<7 hours	59 (41.8)	−0.171 (−0.820; 0.478)	0.603
	≥7 hours	82 (58.2)		

HDS: Histopathologic degenerative score; CI: Confidence interval.

**Table 3. Factors related to comorbidities**

Variable		N (%)	Multivariate regression analysis (HDS)	
			$\beta$ coefficient (95% CI)	P value
Diabetes mellitus	No	110 (78.0)	1.341 (0.149; 2.533)	0.028
	Yes	31 (22.0)		
Hypertension	No	80 (56.8)	1.502 (0.820; 2.184)	<0.001
	Yes	61 (43.3)		
Depression	No	129 (91.5)	1.590 (0.092; 3.089)	0.038
	Yes	12 (8.5)		
Disc herniation on other levels	No	78 (55.3)	0.570 (−0.184; 1.324)	0.137
	Yes	63 (44.7)		
Spinal lumbar stenosis	No	124 (87.9)	2.349 (1.124; 3.574)	<0.001
	Yes	17 (12.1)		
Other autoimmune diseases	No	133 (94.3)	1.489 (−0.072; 3.050)	0.061
	Yes	8 (5.7)		

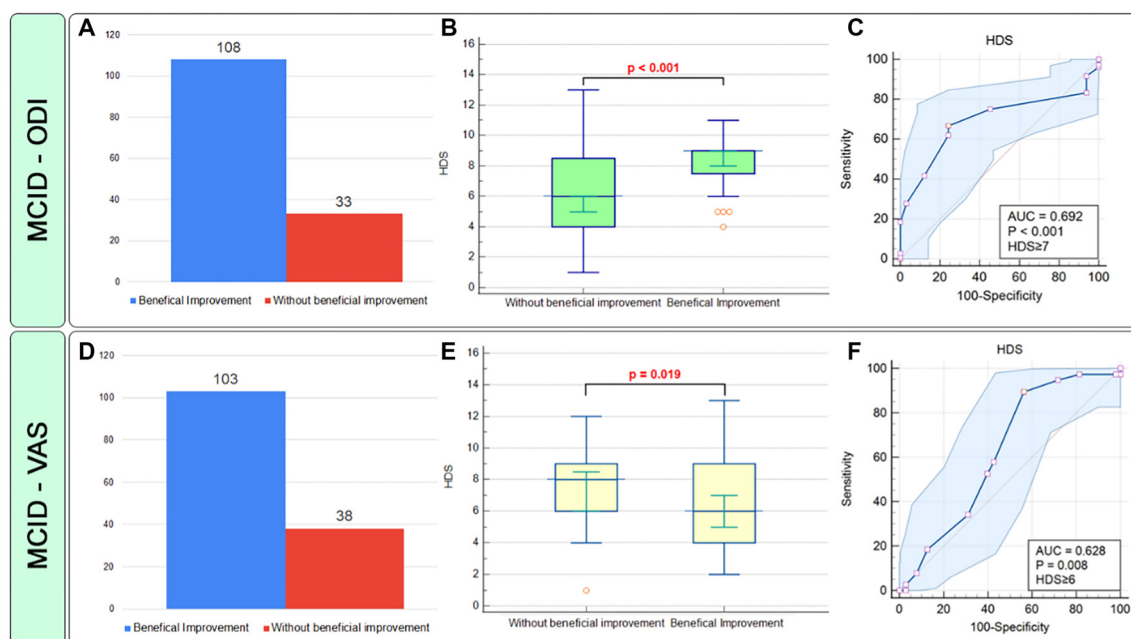
HDS: Histopathologic degenerative score; CI: Confidence interval.

not had a median score of 6.0 (95% CI: 6.0–8.0) (Figure 4B). The AUC was 0.692 (95% CI: 0.609–0.767), significant at  $P < 0.001$  (Figure 4C). An HDS criterion of  $\geq 7$  had a sensitivity of 89.47% and a specificity of 43.69%. A significant association was found between  $\text{HDS} \geq 6$  and MCID-ODI (OR = 6.25, 95% CI: 2.56–15.23). In VAS-assessed MCID, 73% of patients showed improvement. Those without improvement had a median HDS of 8.0 (95% CI: 8.0–9.0), compared to 6.0 (95% CI: 6.0–8.0) for those with improvement ( $P = 0.019$ ) (Figure 4E). The AUC was 0.628 (95% CI: 0.598–0.737,  $P = 0.008$ ) (Figure 4F), with an HDS

criterion of  $\geq 6$ , having 66.67% sensitivity and 75.76% specificity. A significant association was found between  $\text{HDS} \geq 6$  and MCID-VAS (OR = 1.72, 95% CI: 1.04–2.77).

## Discussion

In our study, the HDS emerged as a potential predictor of patient outcomes following surgical intervention for LDH. We observed that an HDS threshold of  $\geq 7$  exhibited good diagnostic and prognostic capabilities in evaluating patient disability



**Figure 4.** Prognostic accuracy evaluation of the histopathological degeneration score (HDS) utilizing the MCID criteria, assessed through the ODI and visual analog scale (VAS) over a six-month follow-up period. The figure depicts: (A) Frequencies of beneficial improvement concerning MCID-ODI; (B) HDS values based on MCID (ODI) and Receiver Operating Characteristic (ROC) curve analysis; (C) Frequencies of beneficial improvement concerning MCID-VAS; (D) HDS values categorized by MCID-VAS groups, and (E) ROC analysis based on MCID-VAS. HDS: Histopathological degeneration score; MCID: Minimal clinically important difference; VAS: Visual analogue scale; ODI: Oswestry disability index; ROC: Receiver operating characteristic.

outcomes. Additionally,  $HDS \geq 8$  was significantly associated with the persistence of pain six months post-treatment. To our knowledge, this is the first study to establish MCID-based cut-off values for HDS, specifically related to disability and pain outcomes.

The results of this study reveal a statistically significant correlation between HDS and motor and sensory function, as well as with the degree of pain and disability in patients undergoing surgical treatment for disc herniation. These findings align with previous research highlighting the intricate relationship between HP findings and clinical outcomes. For example, Oprea et al. [24] demonstrated that the mean surface area of chondrons, a marker of disc degeneration, correlated with lumbar VAS scores ( $r = 0.376$ ) and moderately with Modic Changes ( $r = 0.500$ ), findings that closely correspond with the results observed here. Moreover, Oprea et al. [24] identified a significant association between the degree of IVD degeneration and the Japanese Orthopedic Association Score (JOAS), which assesses neuromuscular function, supporting the predictive value of HDS. Similarly, Middendorp et al. [25] found a correlation between ODI scores and the grade of disc degeneration, further substantiating the impact of HDS on patient disability outcomes. Peletti-Figueiró et al. [26] and Bečulić et al. [27] independently confirmed a positive correlation between the extent and progression of IVD degeneration, respectively, reinforcing the notion that disease progression significantly influences LDH outcomes. However, not all studies agree with these findings; for instance, Willburger et al. [28] reported no significant correlation between sensory impairment and motor strength with the histologic composition of herniated material.

Addressing the inflammatory etiology of pain is crucial in the conservative postoperative treatment of disc herniation patients, as emphasized by Lyu et al. [29]. Additionally, experimental studies such as those by Willburger et al. [28] and Ishikawa et al. [30] provide further evidence of the link between degenerative changes in DM and the severity of pain experienced by patients, supporting the clinical relevance of these findings.

To the best of our knowledge, this is the first study to identify factors related to the severity of disc degeneration based on HP analysis. This research revealed that HDS is associated with various risk factors, including sex, age, anthropometric measures, and occupational exposures, providing a novel perspective on the interplay between microscopic degenerative changes in DH. These risk factors have previously been linked to the severity of symptoms caused by LDH, predominantly through radiological findings [31–34]. This comparison with HP analysis and HDS scoring supports this method as a valuable approach for evaluating the severity of IVD degeneration.

HP analysis emerges as a valuable adjunctive tool in understanding the complexities of LDH, particularly in cases where surgical intervention may not be feasible. By discerning correlations between histologic findings and patient demographics, including age, gender, and anthropometric measures, this approach offers tailored insights into LDH pathogenesis, especially in inoperable or limited surgical option cases [35, 36]. Furthermore, HP analysis enables a personalized medicine approach by correlating histologic observations with clinical parameters such as motor and sensory function, pain intensity, and functional disability, thereby informing postoperative or



post-biopsy pharmacological treatment strategies [37] to optimize patient care and outcomes.

Despite its utility, HP analysis presents inherent challenges. The invasive nature of tissue sampling procedures poses potential risks and discomfort to patients, necessitating careful consideration of ethical and safety concerns. Furthermore, the accessibility of HP facilities may be limited in certain healthcare settings, posing barriers to widespread implementation [38]. Additionally, the semiquantitative nature of histological findings introduces variability, necessitating standardized protocols and rigorous quality assurance measures. Moreover, the resource-intensive nature of HP analysis, both in terms of time and cost [38], may constrain its widespread application and necessitate judicious patient selection.

The study's strengths include its prospective design, detailed inclusion criteria, and robust ethical considerations. However, limitations include the study's single-center nature, which may limit generalizability, and the semi-quantitative method of HP analysis, which could introduce variability in results.

## Conclusion

In conclusion, our study establishes HDS as a potential predictor of post-surgical outcomes for LDH, with thresholds  $\geq 7$  and  $\geq 8$  indicating significant diagnostic and prognostic value for disability and pain persistence at six months. Despite its potential for personalized medicine insights, challenges such as procedural invasiveness, variability in HP interpretation, and resource constraints should be carefully considered.

**Conflicts of interest:** Authors declare no conflicts of interest.

**Funding:** Authors received no specific funding for this work.

Submitted: 24 June 2024

Accepted: 19 July 2024

Published online: 20 July 2024

## References

- Bečulić H, Begagić E, Džidić-Krivić A, Pugonja R, Jaganjac B, Imamović-Bošnjak M, et al. The impact of patient-specific positions on the relationship between iliac blood vessels and lumbar intervertebral discs: anatomical significance and clinical implications. *Anatomia* 2024;3(1):16–28. <https://doi.org/10.3390/anatomia3010003>.
- Mbarki W, Bouchouicha M, Tshienda FT, Moreau E, Sayadi M. Herniated Lumbar disc generation and classification using cycle generative adversarial networks on axial view MRI. *Electronics* 2021;10(8):982. <https://doi.org/10.3390/electronics10080982>.
- Nicol V, Verdagner C, Daste C, Bissierix H, Lapeyre E, Lefèvre-Colau M-M, et al. Chronic low back pain: a narrative review of recent international guidelines for diagnosis and conservative treatment. *J Clin Med* 2023;12(4):1685. <https://doi.org/10.3390/jcm12041685>.
- Jaganjac B, Džidić-Krivić A, Bečulić H, Šljivo A, Begagić E, Šišić A. Magnetic resonance morphometry of the lumbar spinal canal in Zenica - Doboš Canton in Bosnia and Herzegovina. *Med Glas (Zenica)* 2023 Aug 1;20(2):263–68. <https://doi.org/10.17392/1575-23>.
- Munda M, Velnar T. Stem cell therapy for degenerative disc disease: bridging the gap between preclinical promise and clinical potential. *Biomol Biomed* 2024 Mar 11;24(2):210–8. <https://doi.org/10.17305/bb.2023.9518>.
- Roughley PJ, Alini M, Antoniou J. The role of proteoglycans in aging, degeneration and repair of the intervertebral disc. *Biochem Soc Trans* 2002 Nov;30(Pt 6):869–74. <https://doi.org/10.1042/bst0300869>.
- Chen Q, Wang Z, Zhang S. Exploring the latest advancements in physical therapy techniques for treating cervical spondylosis patients: a narrative review. *Biomol Biomed* 2023 Sep 4;23(5):752–9. <https://doi.org/10.17305/bb.2023.9049>.
- Ye L, Gao Z, Rohani S. Intervertebral disk regeneration in a rat model by allopurinol-loaded chitosan/alginate hydrogel. *Biomol Biomed* 2023 Jul 3;23(4):661–70. <https://doi.org/10.17305/bb.2022.8550>.
- Shu CC, Smith MM, Smith SM, Dart AJ, Little CB, Melrose J. A histopathological scheme for the quantitative scoring of intervertebral disc degeneration and the therapeutic utility of adult mesenchymal stem cells for intervertebral disc regeneration. *Int J Mol Sci* 2017;18(5):1049. <https://doi.org/10.3390/ijms18051049>.
- Zielinska N, Podgórski M, Haładaj R, Polguy M, Olewnik L. Risk factors of intervertebral disc pathology—a point of view formerly and today—a review. *J Clin Med* 2021;10(3):409. <https://doi.org/10.3390/jcm10030409>.
- Karchevskaya AE, Poluektov YM, Korolishin VA. Understanding intervertebral disc degeneration: background factors and the role of initial injury. *Biomedicines* 2023;11(10):2714. <https://doi.org/10.3390/biomedicines11102714>.
- Sudo H. Intervertebral disc degeneration and regeneration: new molecular mechanisms and therapeutics. *Cells* 2024;13(2):153. <https://doi.org/10.3390/cells13020153>.
- Staszkievicz R, Gładysz D, Sobański D, Bolechala F, Golec E, Dammermann W, et al. The impacts of intervertebral disc degeneration of the spine, alcohol consumption, smoking tobacco products, and glycemic disorders on the expression profiles of Neurotrophins-3 and -4. *Biomedicines* 2024;12(2):427. <https://doi.org/10.3390/biomedicines12020427>.
- Boos N, Weissbach S, Rohrbach H, Weiler C, Spratt KF, Nerlich AG. Classification of age-related changes in lumbar intervertebral discs: 2002 Volvo Award in basic science. *Spine (Phila Pa 1976)* 2002 Dec 1;27(23):2631–44. <https://doi.org/10.1097/00007632-200212010-00002>.
- Le Maitre CL, Dahia CL, Giers M, Illien-Junger S, Cicione C, Samartzis D, et al. Development of a standardized histopathology scoring system for human intervertebral disc degeneration: an Orthopaedic Research Society Spine Section Initiative. *JOR Spine* 2021 Jun;4(2):e1167. <https://doi.org/10.1002/jsp2.1167>.
- Gogtay NJ. Principles of sample size calculation. *Indian J Ophthalmol* 2010 Nov-Dec;58(6):517–8. <https://doi.org/10.4103/0301-4738.71692>.
- Weir CB, Jan A. BMI classification percentile and cut off points. In: *StatPearls*. Treasure Island (FL): StatPearls Publishing LLC; 2024.
- Chiarotto A, Maxwell LJ, Ostelo RW, Boers M, Tugwell P, Terwee CB. Measurement properties of visual analogue scale, numeric rating scale, and pain severity subscale of the brief pain inventory in patients with low back pain: a systematic review. *J Pain* 2019 Mar;20(3):245–63. <https://doi.org/10.1016/j.jpain.2018.07.009>.
- John J. Grading of muscle power: comparison of MRC and analogue scales by physiotherapists. *Int J Rehabil Res* 1984;7(2):173–81. <https://doi.org/10.1097/00004356-198406000-00005>.
- Maynard FM, Jr., Bracken MB, Creasey G, Ditunno Jr., JF, Donovan WH, Ducker TB, et al. International standards for neurological and functional classification of spinal cord injury. *Spinal Cord* 1997 May;35(5):266–74. <https://doi.org/10.1038/sj.sc.3100432>.
- Fairbank JC, Pynsent PB. The Oswestry disability index. *Spine (Phila Pa 1976)* 2000 Nov 15;25(22):2940–52. <https://doi.org/10.1097/00007632-200011150-00017>.
- Power JD, Perruccio AV, Canizares M, McIntosh G, Abraham E, Attabib N, Bailey CS, et al. Determining minimal clinically important difference estimates following surgery for degenerative conditions of the lumbar spine: analysis of the Canadian Spine Outcomes and Research Network (CSORN) registry. *Spine J* 2023;23(9):1323–33. <https://doi.org/10.1016/j.spinee.2023.05.001>.
- Myles PS, Myles DB, Gallagher W, Boyd D, Chew C, MacDonald N, et al. Measuring acute postoperative pain using the visual analog scale: the minimal clinically important difference and patient acceptable symptom state. *Br J Anaesth* 2017 Mar 1;118(3):424–9. <https://doi.org/10.1093/bja/aew466>.
- Oprea M, Popa I, Cimpean AM, Raica M, Poenaru DV. Microscopic assessment of degenerated intervertebral disc: clinical implications



- and possible therapeutic challenge [Internet]. In Vivo 2015 Jan-Feb;29(1):95–102. <https://pubmed.ncbi.nlm.nih.gov/25600536/>.
- [25] Middendorp M, Vogl TJ, Kollias K, Kafchitsas K, Khan MF, Maataoui A. Association between intervertebral disc degeneration and the Oswestry Disability Index. *J Back Musculoskelet Rehabil* 2017;30(4):819–23. <https://doi.org/10.3233/BMR-150516>.
- [26] Peletti-Figueir ÓM, Aguiar IS, Paesi S, Machado DC, Echeverrigaray S, Roesch-Ely M. Histological markers of degeneration and regeneration of the human intervertebral disk. *Coluna/Columna* 2017;16:42–7. <https://doi.org/10.1590/s1808-185120171601170833>.
- [27] Bečulić H, Skomorac R, Jusić A, Alic F, Imamovic M, Mekic-Abazovic A, et al. Impact of timing on surgical outcome in patients with cauda equina syndrome caused by lumbar disc herniation. *Med Glas (Zenica)* 2016 Aug 1;13(2):136–41. <https://doi.org/10.17392/861-16>.
- [28] Willburger RE, Ehiosun UK, Kuhnen C, Krämer J, Schmid G. Clinical symptoms in lumbar disc herniations and their correlation to the histological composition of the extruded disc material. *Spine* 2004;29(15):1655–61. <https://doi.org/10.1097/01.BRS.0000133645.94159.64>.
- [29] Lyu F-J, Cui H, Pan H, Cheung KMC, Cao X, Iatridis JC, et al. Painful intervertebral disc degeneration and inflammation: from laboratory evidence to clinical interventions. *Bone Res* 2021;9(1):7. <https://doi.org/10.1038/s41413-020-00125-x>.
- [30] Ishikawa T, Watanabe A, Kamoda H, Miyagi M, Inoue G, Takahashi K, et al. Evaluation of Lumbar intervertebral disc degeneration using T1 $\rho$  and T2 magnetic resonance imaging in a rabbit disc injury model. *Asian Spine J* 2018 Apr;12(2):317–24. <https://doi.org/10.4184/asj.2018.12.2.317>.
- [31] Udby PM, Modic M, Elmore S, Carreon LY, Andersen MØ, Karppinen J, et al. The clinical significance of the modic changes grading score. *Global Spine J* 2024;14(3):796–803. <https://doi.org/10.1177/21925682221123012>.
- [32] Zhao J, Zeng L, Zhao S. Associations of recurrent lumbar disc herniation after percutaneous endoscopic Lumbar discectomy with age, body mass index, modic change, disc degeneration and sacral slope: a quantitative review. *Exp Ther Med* 2024 May;27(5):195. <https://doi.org/10.3892/etm.2024.12483>.
- [33] Mateos-Valenzuela AG, González-Macías ME, Ahumada-Valdez S, Villa-Angulo C, Villa-Angulo R. Risk factors and association of body composition components for lumbar disc herniation in Northwest, Mexico. *Sci Rep* 2020 Oct 28;10(1):18479. <https://doi.org/10.1038/s41598-020-75540-5>.
- [34] Juković-Bihorac F, Bečulić H, Begagić E, Pugonja R, Radovanovic J, Džidic-Krivic A, et al. Histopathological spectrum of Lumbar disc changes in obesity: analysis of intervertebral discs in lumbar hernia patients in Zenica-Doboj Canton, Bosnia and Herzegovina. *Med Glas (Zenica)* 2024 Feb 1;21(1):140–6. <https://doi.org/10.17392/1698-23>.
- [35] Jung B, Han J, Song J, Ngan A, Essig D, Verma R. Interventional therapy and surgical management of Lumbar disc herniation in spine surgery: a narrative review. *Orthop Rev (Pavia)* 2023;15:88931. <https://doi.org/10.52965/001c.88931>.
- [36] Heider FC, Mayer HM. [Surgical treatment of lumbar disc herniation]. *Oper Orthop Traumatol* 2017 Feb;29(1):59–85. <https://doi.org/10.1007/s00064-016-0467-3>.
- [37] Butylina M, Wahl-Figlash K, Kothmayer M, Gelles K, Pusch O, Pietschmann P. histopathology of the intervertebral disc of nothobranchius furzeri, a fish model of accelerated aging. *Biology* 2023;12:1305. <https://doi.org/10.3390/biology12101305>.
- [38] Wu AS, Fournay DR. Histopathological examination of intervertebral disc specimens: a cost-benefit analysis. *Can J Neurol Sci* 2007 Nov;34(4):451–5. <https://doi.org/10.1017/S0317167100007344>.

## Related articles

### 1. Extreme lateral interbody fusion (XLIF) in a consecutive series of 72 patients

Mirza Pojskic et al., *BJBMS*, 2020

### 2. Surgical anatomy of microsurgical 3-level anterior cervical discectomy and fusion C4–C7

Domagoj Gajski et al., *BJBMS*, 2021

### 3. Stem cell therapy for degenerative disc disease: Bridging the gap between preclinical promise and clinical potential

Matic Munda and Tomaz Velnar, *Biomol Biomed*, 2023