

Evaluation of conventional imaging techniques on preoperative localization in primary hyperparathyroidism

Mesut Ozkaya¹, Umut Elboga^{2*}, Ertan Sahin³, Ebuzer Kalender², Hakan Korkmaz¹, H. Deniz Demir², Y. Zeki Celen², Suna Erkilic⁴, Avni Gokalp⁵, Gokturk Maralcan⁵

¹Department of Endocrinology, Gaziantep University, Gaziantep, Turkey. ²Department of Nuclear Medicine, Gaziantep University, Gaziantep, Turkey. ³Department of Nuclear Medicine, Namik Kemal University, Tekirdag, Turkey. ⁴Department of Pathology, Gaziantep University, Gaziantep, Turkey. ⁵Department of Surgery, Gaziantep University, Gaziantep, Turkey

ABSTRACT

We aimed to evaluate the diagnostic and preoperative localization capacity of ^{99m}Tc methoxyisobutyl nitrile (MIBI) parathyroid scintigraphy and ultrasonography (USG) in enlarged parathyroid glands in the primary hyperparathyroidism (pHPT), as well as the relationship between the success rate of these techniques and biochemical values. We retrospectively evaluated 39 patients with clinical and biological evidence of pHPT who referred to the university hospital for MIBI parathyroid scintigraphy. Patients were examined with USG and double-phase MIBI parathyroid scintigraphy for the detection of enlarged parathyroid glands. Preoperative serum intact parathyroid hormone (iPTH) levels, calcium (Ca), phosphate and alkaline phosphatase measurements were obtained. A total of 45 parathyroid lesions in 39 patients were reviewed. Thirty-four patients had a single adenoma and five patients with multi-gland disease had 11 abnormal parathyroid glands including three adenomas, whereas the remaining 8 glands showed hyperplasia. The overall sensitivities of MIBI parathyroid scintigraphy, USG, and combined techniques were 85.3%, 72.5% and 90.4%, respectively; the positive predictive values (PPV) were 89.7%, 85.2%, and 92.6%, respectively. The most successful approach for detection of enlarged parathyroid glands in hyperparathyroidism is the concurrent application of USG and MIBI parathyroid scintigraphy modalities. The concomitance of thyroid diseases decreases the sensitivity of both MIBI parathyroid scintigraphy and USG in enlarged parathyroid glands.

KEY WORDS: Hyperparathyroidism; MIBI parathyroid scintigraphy; USG; iPTH; calcium

DOI: <http://dx.doi.org/10.17305/bjbms.2015.207>

Bosn J Basic Med Sci. 2015;15(1):61-66. © 2015 ABMSFBIH

INTRODUCTION

Primary hyperparathyroidism (pHPT) is a disease characterized by idiopathic, pathological hyper functioning of one or more parathyroid glands, leading to excessive parathyroid hormone (PTH) secretion [1]. The main cause of primary hyperparathyroidism is a solitary adenoma, followed by multiple adenomas, hyperplastic glands, and, very rarely, carcinomas [2]. Successful treatment of primary hyperparathyroidism involves identification and excision of enlarged parathyroid glands [3]. Noninvasive imaging techniques, such as ultrasonography (USG), ^{99m}Tc methoxyisobutyl nitrile (MIBI) parathyroid scintigraphy, and magnetic resonance (MR), are commonly used for the identification of enlarged parathyroid

glands. All these imaging methods have had varying rates of success along with a lack of the requisite sensitivity to justify the application of any single imaging modality for routine use before surgical neck exploration [4]. Among these techniques, MIBI parathyroid scintigraphy and USG are the main imaging modalities for the preoperative localization of parathyroid adenomas [5]. In this study, we aimed to retrospectively assess the sensitivity of USG, MIBI parathyroid scintigraphy and the combination of both modalities for preoperative localization of enlarged parathyroid glands as well as their relationship with biochemical results for pHPT patients.

MATERIALS AND METHODS

Patients

In this study, we retrospectively evaluated patients with clinical and biological evidence of hyperparathyroidism who referred to the university hospital over a 4-year period (June 2007 to June 2011) for MIBI parathyroid

*Corresponding author: Umut Elboga, MD
Department of Nuclear Medicine, School of Medicine, Gaziantep University, Gaziantep, Turkey, Phone: +90-342-360 60 60
Fax: +90-342-360 39 28
E-mail: umutelboga@hotmail.com

scintigraphy. Patients had a pre-surgical diagnosis of pHPT, with corresponding laboratory findings: high serum calcium (Ca), low serum phosphate (P) values, high intact parathyroid hormone (iPTH), and the presence of normal renal functions with normal urea and creatinine levels. The study included 39 patients (27 women and 12 men; mean age 41 ± 8.3 ; age range 19–58 years) who were referred to the nuclear medicine department for MIBI parathyroid scintigraphy because of the suspicion of primary hyperparathyroidism. Patients were examined with USG and double-phase MIBI parathyroid scintigraphy in order to detect enlarged parathyroid glands. The diagnosis was confirmed by surgical resection, quick PTH, frozen section and histopathology after MIBI parathyroid scintigraphy and sonography studies. The study was approved by the Medical Ethics Committee of the School of Medicine, University of Gaziantep.

Scintigraphy

Scintigraphy was performed as a dual-phase single-tracer examination. About 740 MBq of ^{99m}Tc -MIBI was administered to patients intravenously. Following an intravenous injection of ^{99m}Tc -MIBI, planar static images of the anterior view of the neck and upper thorax were obtained with the patient placed in the supine position. Each image was acquired in a 256x256 pixel matrix of 5-min duration. Two images, the initial one at 20 min post-injection (thyroid phase) and the second at 60-120 min (parathyroid phase), were obtained. A gamma camera equipped with a low-energy high-resolution (LEHR) parallel hole collimator was used for image acquisition. SPECT imaging was performed only in patients in whom planar imaging failed to localize the abnormal gland. A positive study was defined when a solitary focus of ^{99m}Tc -MIBI greater than background neck activity was noted on the early or delayed imaging. The site of such uptake was also noted.

Ultrasonography

The ultrasound system used for this study was a General Electric (GE) medical system, a gray scale real-time ultrasound machine, fitted with a 7.5 MHz transducer. The patients were examined in the supine position with hyperextended cervical spine. Ultrasound examinations were performed by two nuclear medicine specialists experienced in neck USG imaging. The examiner was unaware of any prior imaging results using other techniques, including MIBI parathyroid scintigraphy. An enlarged parathyroid gland was recognized as a homogeneously echogenic structure with less echogenicity than the thyroid gland.

Surgery and Histological Interpretation

The surgical materials were reviewed retrospectively by pathologist without any acquaintance with the

semi-quantitative scintigraphic results. Each lesion was classified as either adenoma or hyperplasia. The volume of each gland was calculated by measuring three greatest diameters according to the ellipsoid volume formula.

Laboratory parameters

Levels of serum calcium and phosphate were determined using the spectrophotometric method. Intact parathyroid hormone (iPTH) level was measured with specific chemiluminescence immunoassays. Baseline values of all laboratory parameters had been determined about 1-2 weeks before MIBI parathyroid scintigraphy was done.

Statistics

The collected data were entered into SPSS version 12. Data were expressed as a mean \pm SD. Sensitivity was defined as the ratio of true positive tests to the sum of true-positive and false-negative tests. The differences in sensitivity were compared using McNemar's test for paired data. Quantitative data comparisons were performed with Student's t-test, Chi-square, and Mann-Whitney U-test. P values of less than 0.05 were considered statistically significant.

RESULTS

Thirty-nine patients (27 women and 12 men; mean age 41 ± 8.3 ; age range 19–58 years) underwent surgery for parathyroidectomy. Upon surgical exploration, a total of 45 enlarged parathyroid glands were found in 39 patients; 34 patients had a single adenoma while 5 had a multi-gland disease. Seven of the 39 patients had coexisting thyroid disorders. Thyroid pathology was detected by USG and MIBI parathyroid scintigraphy preoperatively. In the patients with thyroid disorder; 12 enlarged parathyroid glands (9 adenomas and 3 hyperplasias) were detected during surgical exploration. The definitive histological examination revealed that 34 patients had a single adenoma and 5 patients with multi-gland disease had 11 abnormal parathyroid glands including 3 adenomas, whereas the remaining 8 glands showed parathyroid hyperplasia. We found that adenomas were more commonly seen in women, while hyperplasia was more prevalent in men, but these findings were not statistically significant ($p > 0.05$). In all patients, the mean serum levels of calcium, phosphates and iPTH were 11.4 ± 1.5 mg/dl, 2.6 ± 0.9 and 282.9 ± 117.1 pg/ml, respectively. Among 34 patients with a single adenoma, MIBI parathyroid scintigraphy and USG correctly identified the pathology in 90.9% and 87.1% of cases, respectively. Parathyroid adenomas were detected with 96.9% certainty when USG and MIBI parathyroid scintigraphy modalities were applied concurrently (Table 1). Of a total of 11 parathyroid lesions in 5 multi-gland patients, MIBI parathyroid

scintigraphy and USG correctly identified 63.6% (7/11) and 45.4% (5/11) pathologies, respectively. Parathyroid glands were detected with 72.7% (8/11) accuracy when both USG and MIBI parathyroid scintigraphy modalities were applied together. Of the twelve enlarged parathyroid glands in patients with thyroid disorders, MIBI parathyroid scintigraphy and USG correctly detected 41.6% (5/12) and 25% (3/12), respectively. There was a significant difference in the detection sensitivity of parathyroid lesions between patients with and without thyroid pathology for both MIBI parathyroid scintigraphy and USG ($p > 0.05$). One multi-gland patient had two hyperplastic parathyroid glands that were detected neither by MIBI parathyroid scintigraphy nor USG. These glands were localized in the upper pole of both lobes, and one of them weighed less than 0.5 g. In the detection of hyperplastic parathyroid glands, MIBI parathyroid scintigraphy was found to be superior to USG, but the finding is not statistically significant ($p > 0.05$). In our study that included 45 enlarged parathyroid glands in 39 patients, MIBI parathyroid scintigraphy had 85.3% sensitivity, while USG had sensitivity of 72.5%, and their combined use had a sensitivity of 90.4% (Table 2). The localisation of the 37 total parathyroid adenomas were as following: twenty-one (56.8%) were associated with the right lobe (16 in the lower pole, 5 in the upper pole), 16 (43.2%) were associated with the left lobe (13 in the lower pole, 3 in the upper pole). The scintigraphic and ultrasonographic images of the right inferoposterior parathyroid adenoma were shown in Figure 1.

The correlation analysis of scintigraphy and ultrasonography findings with the laboratory parameters and parathyroid gland size

The range of iPTH levels in adenoma cases was between 129 and 578 pg/ml, while it ranged it 142-298 pg/ml in hyperplasia cases. The range of serum calcium levels for

TABLE 1. Preoperative localization tests for patients with a single adenoma

	N	TP	FP	FN	S (%)	PPV (%)
MIBI	34	30	1	3	90.9	96.7
USG	34	27	3	4	87.1	90.0
Combine (MIBI+USG)	34	32	1	1	96.9	96.9

N: Numbers of parathyroid glands; TP: True Positive, FP: False Positive, FN: False Negative, S: Sensitivity, PPV: Positive Predictive Value; $S = TP / (TP + FN)$, $PPV = TP / (TP + FP)$

TABLE 2. Preoperative localization tests for enlarged parathyroid glands

	N	TP	FP	FN	S (%)	PPV (%)
MIBI	45	35	4	6	85.3	89.7
USG	45	29	5	11	72.5	85.2
Combined (MIBI+USG)	45	38	3	4	90.4	92.6

N: Numbers of parathyroid glands; TP: True positive, FP: False positive, FN: False negative, S: Sensitivity, PPV: Positive predictive value; $S = TP / (TP + FN)$, $PPV = TP / (TP + FP)$

adenoma was between 10.4 and 14.3 mg/dl, and for hyperplasia it was between 10.1 and 12.7 mg/dl. Both iPTH and serum calcium levels showed significant differences between scintigraphy-positive and -negative patients ($p = 0.01$; $p = 0.013$). iPTH levels showed significant differences between USG-positive and -negative patients ($p = 0.011$), but no significant differences could be found in the serum calcium levels between patients with positive and negative USG examinations ($p = 0.24$). According to the results of the histopathology, the range of the glands' weight for adenomas was between 285 and 4360 mg, while it was between 160 and 1245 mg for hyperplasia cases. The weight of the glands was significantly associated with the detection rate of either MIBI parathyroid scintigraphy or USG in localizing the enlarged parathyroid gland ($p = 0.001$; $p = 0.021$). The comparison of biochemical parameters and gland weight between patients with positive and negative USG/MIBI parathyroid scintigraphy results is shown in Table 3. There were six parathyroid glands (four of them with hyperplasia, two of them with adenoma) that were detected neither by MIBI parathyroid scintigraphy nor USG. Five of them weighted under 0.5 g.

DISCUSSION

The main pathology in pHPT is insufficient sensitivity of the pathologically altered parathyroid gland to inhibition by ambient calcium [6]. The most frequent reasons for pHPT

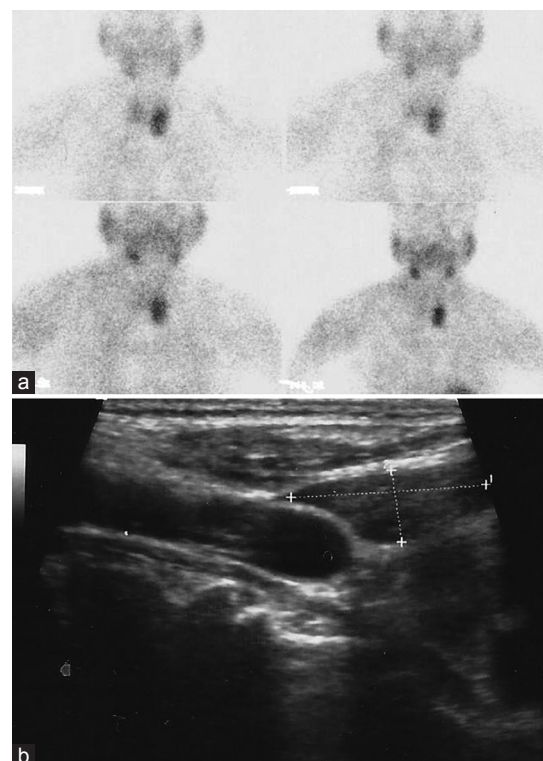


FIGURE 1. The left inferoposterior parathyroid adenoma detected by scintigraphic (a) and ultrasonographic (b) images

TABLE 3. Comparison of biochemical parameters and weight of the glands weight in patients with positive and negative USG-scintigraphy results

Variables	USG			MIBI-Scintigraphy		
	P (M±SEM)	N (M±SEM)	p-values	P (M±SEM)	N (M±SEM)	p-values
PTH (pg/ml)	239.2±84.9	156.8±27.2	0.011 (S)	261.6±97.3	132.8±53.7	0.01 (S)
Ca (mg/dl)	11.3±1.02	10.8±0.96	0.24 (NS)	12.1±1.09	10.9±0.61	0.013 (S)
Weight (mg)	1887,1±1075,3	910,8±813,4	0.021 (S)	1773,1±1135,3	795,4±622,4	<0.001 (S)

P: Positive, N: Negative, S: Significant, NS: Non-significant

include parathyroid adenoma and hyperplasia. In our study, enlarged parathyroid glands were found more frequently in women, the finding being in concordance with the existing literature. Surgery is the only curative therapy for pHPT and should be considered for each patient. Imaging techniques of parathyroid glands play the crucial role in preoperative planning of surgical procedures. USG and MIBI parathyroid scintigraphy are the principal imaging techniques and are frequently used together for the preoperative location of pathological parathyroid glands [5,7-9]. In our study, MIBI parathyroid scintigraphy and USG had 85.3% and 72.5% sensitivity, respectively. These results show that MIBI parathyroid scintigraphy was superior to USG in localizing enlarged parathyroid glands. The superiority of MIBI parathyroid scintigraphy to USG might be attributed to the additional functional features of scanning technique based on the metabolic activity of the parathyroid gland. Although there are studies similar to our study in the literature, there are also many studies showing the superiority of USG. In our study, the sensitivity of USG was higher than in some previous research [10-12], the result probably altered by the fact that examiners in the study were two experienced nuclear medicine specialists having the opportunity to consult each other in the case of equivocal images. Our research showed that the most successful technique for detection of enlarged parathyroid glands is the pragmatic combination of USG and MIBI parathyroid scintigraphy modalities. MIBI parathyroid scintigraphy had 85.3% sensitivity, while USG had 72.5%. On the other hand, the combined application of USG and MIBI parathyroid scintigraphy had 90.4% sensitivity. A preoperative approach that integrates both the anatomic information provided by USG and the physiologic information gathered by MIBI parathyroid scintigraphy has been shown to predict the presence and location of solitary adenomas more accurately than either technique alone. The single-tracer dual-phase technique depends on the washout time of MIBI parathyroid scintigraphy between the thyroid gland and the functionally abnormal parathyroid gland. There is a wide range in reported sensitivity for adenoma (from 58% to 100%) and hyperplasia (from 33% to 78%) in the literature [13-16]. In our study, the sensitivity of MIBI parathyroid scintigraphy was found to be 90.9% for patients with a single adenoma. It is believed that false-negative MIBI parathyroid scintigraphy is associated with small parathyroid

adenomas and multi-glandular disease, and the expression of p-glycoprotein, or multi-drug resistance (MDR)-related protein [17-19]. It is also related to delayed activity washout from the thyroid gland as in multi-nodular goiters and Hashimoto's thyroiditis. Enlarged multi-nodular thyroid glands can also limit the sonographic evaluation of parathyroid adenomas [5]. On the contrary, coexistent benign or malignant thyroid disease has also been associated with false-positive results [19]. In our study, there was a significant difference in detection of parathyroid lesions between patients with and without thyroid pathology for both types of scintigraphy.

The changes in levels of iPTH, calcium, and phosphate, observed in hyperparathyroidism, are an indication of the increased metabolism of pathologic parathyroid gland(s). It has been reported that the gland hypermetabolism found in hyperparathyroidism causes increased tissue perfusion [20]. An increase in the uptake and retention of MIBI is an expected result of the increase in gland perfusion. Increases in both perfusion and functional activity and targeting of abundant mitochondria-rich oxyphil cells seem to be relevant mechanisms of uptake. Some investigators have shown a correlation between serum iPTH levels and MIBI uptake in primary and secondary hyperparathyroidism [11,21-23]. Also, it has been reported that MIBI uptake is increased in cases with high serum Ca [24-26]. Our study confirms that MIBI parathyroid scintigraphy is more likely to be positive in patients with the highest iPTH and calcium levels. In our study, iPTH levels were significantly different in patients with positive and negative USG examinations, while there were no significant differences in serum calcium levels. Another factor that might influence scintigraphic and USG detection of abnormal parathyroid glands seem to be their weight. An abnormal parathyroid gland, as a heavier gland, is more likely to be localized by these techniques than a lighter one. Parathyroid adenomas smaller than 500 mg are not often visualized by using MIBI parathyroid scintigraphy [27-29]. It has also been reported that the results of USG are affected positively by the weight of abnormal glands in some studies [30,31]. In our study, the range of glands' weight for adenoma was between 285 and 4360 mg, while it was between 160 and 1245 mg for hyperplasia. We found that the weight of glands was significantly associated with the detection rate of either MIBI parathyroid scintigraphy or USG in localizing enlarged parathyroid glands. ($p = 0.001$; $p = 0.024$, respectively).

CONCLUSION

We conclude that the most successful approach for detection of enlarged parathyroid gland in hyperparathyroidism is the concurrent application of USG and MIBI parathyroid scintigraphy modalities in order to detect enlarged parathyroid glands in hyperparathyroidism. The increased preoperative serum iPTH and the glands' weight were correlated with positive MIBI parathyroid scintigraphy and USG study of pathologically altered glands.

DECLARATION OF INTERESTS

The authors declare no conflict of interests.

REFERENCES

- [1] Del Rio P, Cataldo S, Sommaruga L, Arcuri MF, Massa M, Sianesi M. Localization of pathological glands site in primary hyperparathyroidism: ten years experience with MIBI scintigraphy. *G Chir* 2008;29(4):186-189.
- [2] Marx SJ. Hyperparathyroid and hypoparathyroid disorders. *N Engl J Med* 2000;343 (25):1863-1875. <http://dx.doi.org/10.1056/NEJM200012213432508>.
- [3] Satava RM, Beahrs OH, Scholz DA. Success rate of cervical exploration for hyperparathyroidism. *Arch Surg* 1975;110(5):625-628. <http://dx.doi.org/10.1001/archsurg.1975.01360110171028>.
- [4] Doppman JL. Preoperative localization of parathyroid tissue in primary hyperparathyroidism. In: Bilzেকian JP, editor. *The Parathyroids*. New York: Raven Press, Ltd; 1994. P. 553-565.
- [5] Johnson NA, Tublin ME, Ogilvie JB. Parathyroid imaging: technique and role in the preoperative evaluation of primary hyperparathyroidism. *AJR Am J Roentgenol* 2007;188:1706-1715. <http://dx.doi.org/10.2214/AJR.06.0938>.
- [6] Hendy GN. Molecular mechanisms of primary hyperparathyroidism. *Rev Endocr Metab Disord* 2000;1(4):297-305. <http://dx.doi.org/10.1023/A:1026518502081>.
- [7] Henry JF, Iacobone M, Mirallie E, Deveze A, Pili S. Indications and results of video-assisted parathyroidectomy by a lateral approach in patients with primary hyperparathyroidism. *Surgery* 2001;130(6):999-1004. <http://dx.doi.org/10.1067/msy.2001.119112>.
- [8] Jacobson SR, Van Heerden JA, Farley DR, Grant C, Thompson GB, Mullan BP, et al. Focused cervical exploration for primary hyperparathyroidism without intraoperative parathyroid hormone monitoring or the use of the gamma probe. *World J Surg* 2004;28:1127-1131. <http://dx.doi.org/10.1007/s00268-004-7469-2>.
- [9] Profanter C, Wetscher GJ, Gabriel M, Sauper T, Rieger M, Kovacs P. CT-MIBI image fusion: a new preoperative localization technique for primary, recurrent and persistent hyperparathyroidism. *Surgery* 2004;135(2):157-162. [http://dx.doi.org/10.1016/S0039-6060\(03\)00396-9](http://dx.doi.org/10.1016/S0039-6060(03)00396-9).
- [10] Neumann DR, Esselstyn CB Jr, Go RT, Wong CO, Rice TW, Obuchowski NA. Comparison of double-phase ^{99m}Tc-sestamibi with ¹²³I-^{99m}Tc-sestamibi subtraction SPECT in hyperparathyroidism. *Am J Roentgenol* 1997;169(6):1671-1674. <http://dx.doi.org/10.2214/ajr.169.6.9393188>.
- [11] Haber RS, Kim CK, Inabnet WB. Ultrasonography for preoperative localization of enlarged parathyroid glands. *Clin Endocrinol (Oxf)* 2002;57(2):241-249. <http://dx.doi.org/10.1046/j.1365-2265.2002.01583.x>.
- [12] Barczynski M, Golkowski F, Konturek A, Buziak-Bereza M, Cichon S, Hubalewska-Dydejczyk A, et al. Technetium-99m-sestamibi subtraction scintigraphy vs. ultrasonography combined with a rapid parathyroid hormone assay in parathyroid aspirates in preoperative localization of parathyroid adenomas in directing

- surgical approach. *Clin Endocrinol (Oxf)* 2006;65(1):106-113. <http://dx.doi.org/10.1111/j.1365-2265.2006.02556.x>.
- [13] Ishibashi M, Nishida H, Hiromatsu Y, Kojima K, Tabuchi E, Hayabuchi N. Comparison of technetium-99m MIBI, technetium-99m tetrofosmin, ultrasound and MRI for localization of abnormal parathyroid glands. *J Nucl Med* 1998;39(2):320-324.
- [14] Gotthardt M, Lohmann B, Behr TM, Bauhofer A, Franzius C, Schipper ML, et al. Clinical value of parathyroid scintigraphy with technetium-99m methoxyisobutylisonitrile: discrepancies in clinical data and a systematic metaanalysis of the literature. *World J Surg* 2004;28(1):100-107. <http://dx.doi.org/10.1007/s00268-003-6991-y>.
- [15] De Feo ML, Colagrande S, Biagini C, Tonarelli A, Bisi G, Vaggelli L, et al. Parathyroid glands: Combination of (99m) Tc MIBI scintigraphy and US for demonstration of parathyroid glands and nodules. *Radiology* 2000;214(2):393-402. <http://dx.doi.org/10.1148/radiology.214.2.roof0e4393>.
- [16] Torregrosa JV, Fernandez-Cruz L, Canalejo A, Vidal S, Astudillo E, Almaden Y, et al. (99m) Tc-sestamibi scintigraphy and cell cycle in parathyroid glands of secondary hyperparathyroidism. *World J Surg* 2000;24(11):1386-1390. <http://dx.doi.org/10.1007/s00268010229>.
- [17] Palestro CJ, Tomas MB, Tronco GG. Radionuclide imaging of the parathyroid glands. *Semin Nucl Med* 2005;35(4):266-276. <http://dx.doi.org/10.1053/j.semnuclmed.2005.06.001>.
- [18] Pons F, Torregrosa JV, Fuster D. Biological factors influencing parathyroid localization. *Nucl Med Commun* 2003;24(2):121-124. <http://dx.doi.org/10.1097/00006231-200302000-00003>.
- [19] Rodriguez J, Parrilla P. Localization studies in persistent or recurrent hyperparathyroidism. In: Clark OH, Duh QY, Kebebew E, editors. *Textbook of endocrine surgery*. Philadelphia: Elsevier Saunders; 2005. P. 430-438.
- [20] Lane MJ, Desser TS, Weigel R J, et al. Use of colour and power Doppler sonography to identify feeding arteries associated with parathyroid adenomas. *A JR Am J Roentgenol* 1998;171:819-823. <http://dx.doi.org/10.2214/ajr.171.3.9725323>.
- [21] Biertho LD, Kim C, Wu HS, Unger P, Inabnet WB. Relationship between sestamibi uptake, parathyroid hormone assay, and nuclear morphology in primary hyperparathyroidism. *J Am Coll Surg* 2004;199(2):229-233. <http://dx.doi.org/10.1016/j.jamcollsurg.2004.04.013>.
- [22] Hung GU, Wang SJ, Lin WY. Tc-99m MIBI parathyroid scintigraphy and intact parathyroid hormone levels in hyperparathyroidism. *Clin Nucl Med* 2003;28(3):180-185. <http://dx.doi.org/10.1097/01.RLU.0000053529.71776.37>.
- [23] Ambrosioni P, Heuguerot C, Olaizola I, Acuña G, Fajardo L, Petraglia A, et al. Can we use ^{99m}Tc-MIBI in functional studies of the parathyroid gland? *Nephrol Dial Transplant* 1998;13(3):33-36. http://dx.doi.org/10.1093/ndt/13.suppl_3.33.
- [24] Melloul M, Paz A, Koren R, Cytron S, Feinmesser R, Gal R, et al. ^{99m}Tc-MIBI scintigraphy of parathyroid adenomas and its relation to tumour size and oxyphil cell abundance. *Eur J Nucl Med* 2001;28(2):209-213. <http://dx.doi.org/10.1007/s002590000406>.
- [25] Carpentier A, Jeannotte S, Verreault J, Lefebvre B, Bisson G, Moineau C, et al. Preoperative localization of parathyroid lesions in hyperparathyroidism: relationship between technetium-99m-MIBI uptake and oxyphil cell content. *J Nucl Med* 1998;39(8):1441-1444.
- [26] Parikshak M, Castillo ED, Conrad MF, Talpos GB. Impact of hypercalcemia and parathyroid hormone level on the sensitivity of preoperative sestamibi scanning for primary hyperparathyroidism. *Am Surg* 2003;69(5):393-398.
- [27] Denham DW, Norman J. Cost-effectiveness of preoperative sestamibi scan for primary hyperparathyroidism is dependent solely upon the surgeon's choice of operative procedure. *J Am Coll Surg* 1998;186(3):293-304. [http://dx.doi.org/10.1016/S1072-7515\(98\)00016-7](http://dx.doi.org/10.1016/S1072-7515(98)00016-7).
- [28] Rubello D, Casara D, Pelizzo MR. Optimization of peri-operative procedures. *Nucl Med Commun* 2003;24(2):133-140. <http://dx.doi.org/10.1097/00006231-200302000-00005>.
- [29] Hindie E, Ugur O, Fuster D, O'Doherty M, Grassetto G, Ureña P, et al. EANM parathyroid

- guidelines. *Eur J Nucl Med Mol Imaging* 2009;36(7):1201–1216. <http://dx.doi.org/10.1007/s00259-009-1131-z>.
- [30] Bhansali A, Masoodi SR, Bhadada S, Mittal BR, Behra A, Singh P. Ultrasonography in detection of single and multiple abnormal parathyroid glands in primary hyperparathyroidism: comparison with radionuclide scintigraphy and surgery. *Clin Endocrinol (Oxf)* 2006; 65(3): 340–345. <http://dx.doi.org/10.1111/j.1365-2265.2006.02601.x>.
- [31] Lo CY, Lang BH, Chan WF, Kung AW, Lam KS. A prospective evaluation of preoperative localization by technetium-99m sestamibi scintigraphy and ultrasonography in primary hyperparathyroidism. *Am J Surg* 2007;193(2):155–9. <http://dx.doi.org/10.1016/j.amjsurg.2006.04.020>.